Videotorakoskopik Cerrahideki Limitler

Olgularla VATS Göğüs Duvarı Cerrahisi

Prof. Dr. Hüseyin MELEK
Bursa Uludağ Üniversitesi Tıp Fakültesi
Göğüs Cerrahisi Anabilim Dalı

Çıkar çatışmam bulunmamaktadır…

Olgu

- 56 y, E
- 30 yıl önce seminom, opere + RT
- Ek sistemik hast yok
- Antidepresan kullanıyor

- Şikayeti: hemoptizi

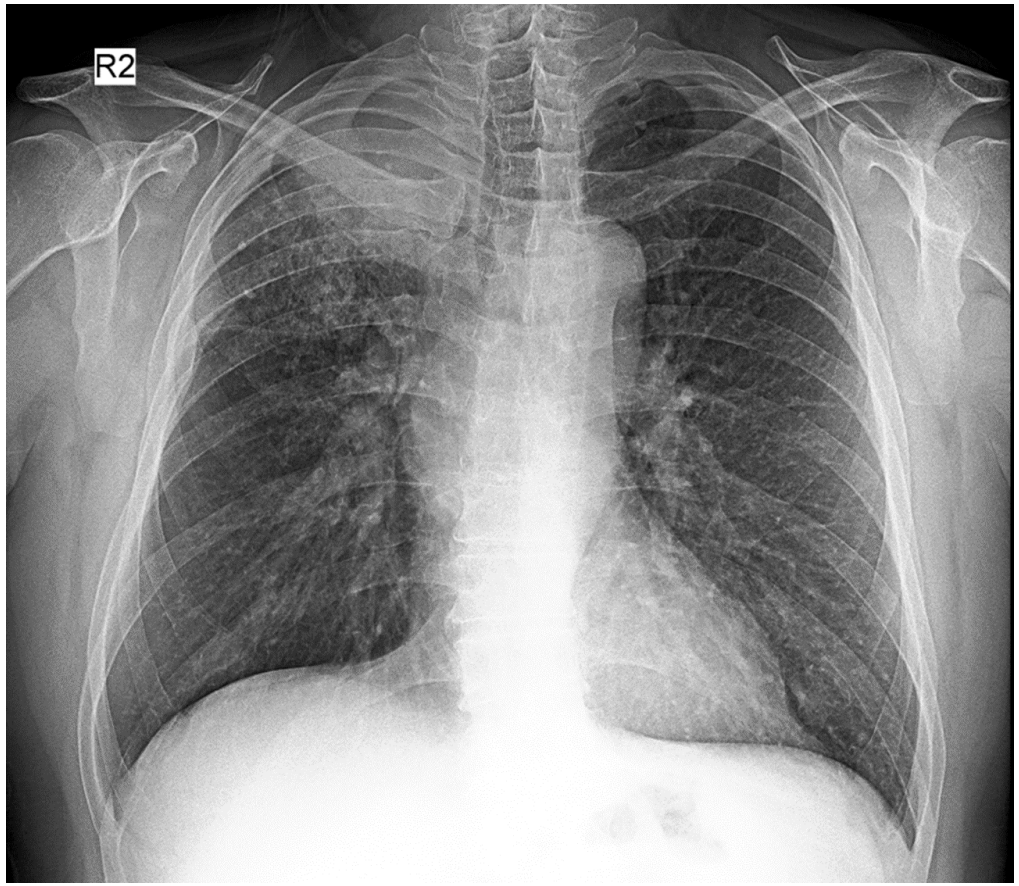

Olgu Toraks BT ve PET BT

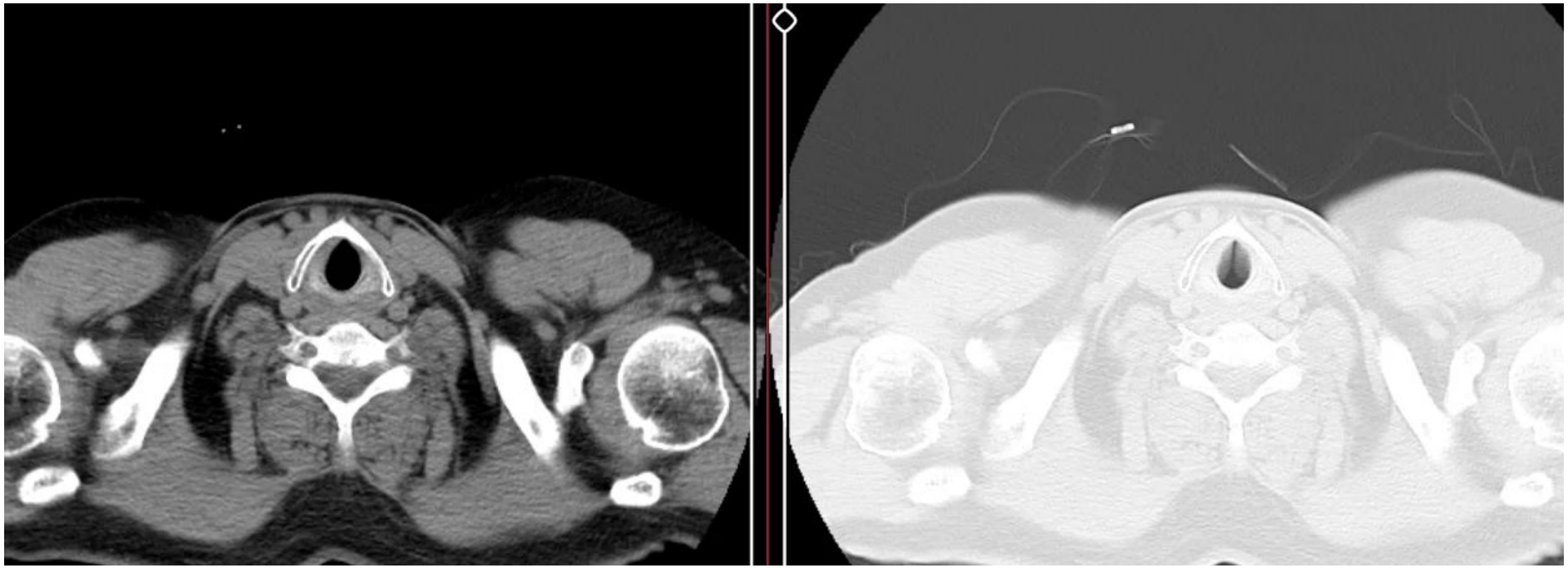

- Sağ akc üst lob apikoposterior segmentte major fissüre komşu 8x7cm, lenfanjitik yayılım?
- SUVmaks 18
- cT4N0M0

Olgu Toraks BT ve PET BT

Göğüs Duvarı İnvazyonu - Klinik

- Ağrı: en sık şikayet
  - Dayanılmaz, şiddetli, sürekli
  - geleneksel analjeziklere yanıt az
  - ağrı → %50 GDİ
  - ağrı yoksa →GDİ yoktur ?
- Diğer
  - Öksürük
  - Hemoptizi
  - Dispne
  - Asemptomatik
- Toraks BT: sensivitesi %50-81
- MR: daha yüksek doğruluk oranı
  - Rutin uygulanmıyor

- Akciğer ca → %5- 8 GDİ
- ilk torasik tm GDR→ 1778, Osias Aimar
- ilk Akciğer ve GDR→1947, Coleman
- Eski yıllarda GDİ varlığı akciğer rezeksiyonu için kontrendike

9.TNM

IASLC

INTERNATIONAL ASSOCIATION FOR THE STUDY OF LUNG CANCER

Lung Cancer TNM Stages–9th Edition

Stage Groups of the 9th Edition of the Tumor, Node, Metastasis (TNM) Classification of Lung Cancer

9th Edition TNM Descriptors and Stages

T/M	Categories and Descriptors	N0	N1	N2		N3
				N2a	N2b	
T1	T1a ≤1 cm	IA1	IIA	IIB	IIIA	IIIB
	T1b >1 to ≤2 cm	IA2	IIA	IIB	IIIA	IIIB
	T1c >2 to ≤3 cm	IA3	IIA	IIB	IIIA	IIIB
T2	T2a Visceral pleura / central invasion	IB	IIB	IIIA	IIIB	IIIB
	T2a >3 to ≤4 cm	IB	IIB	IIIA	IIIB	IIIB
	T2b >4 to ≤5 cm	IIA	IIB	IIIA	IIIB	IIIB
T3	T3 >5 to ≤7 cm	IIB	IIIA	IIIA	IIIB	IIIC
	T3 Invasion	IIB	IIIA	IIIA	IIIB	IIIC
	T3 Same lobe separate tumor nodules	IIB	IIIA	IIIA	IIIB	IIIC
T4	T4 >7 cm	IIIA	IIIA	IIIB	IIIB	IIIC
	T4 Invasion	IIIA	IIIA	IIIB	IIIB	IIIC
	T4 Ipsilateral separate tumor nodules	IIIA	IIIA	IIIB	IIIB	IIIC

IASLC

INTERNATIONAL ASSOCIATION FOR THE STUDY OF LUNG CANCER

Lung Cancer T Classification–9th Edition

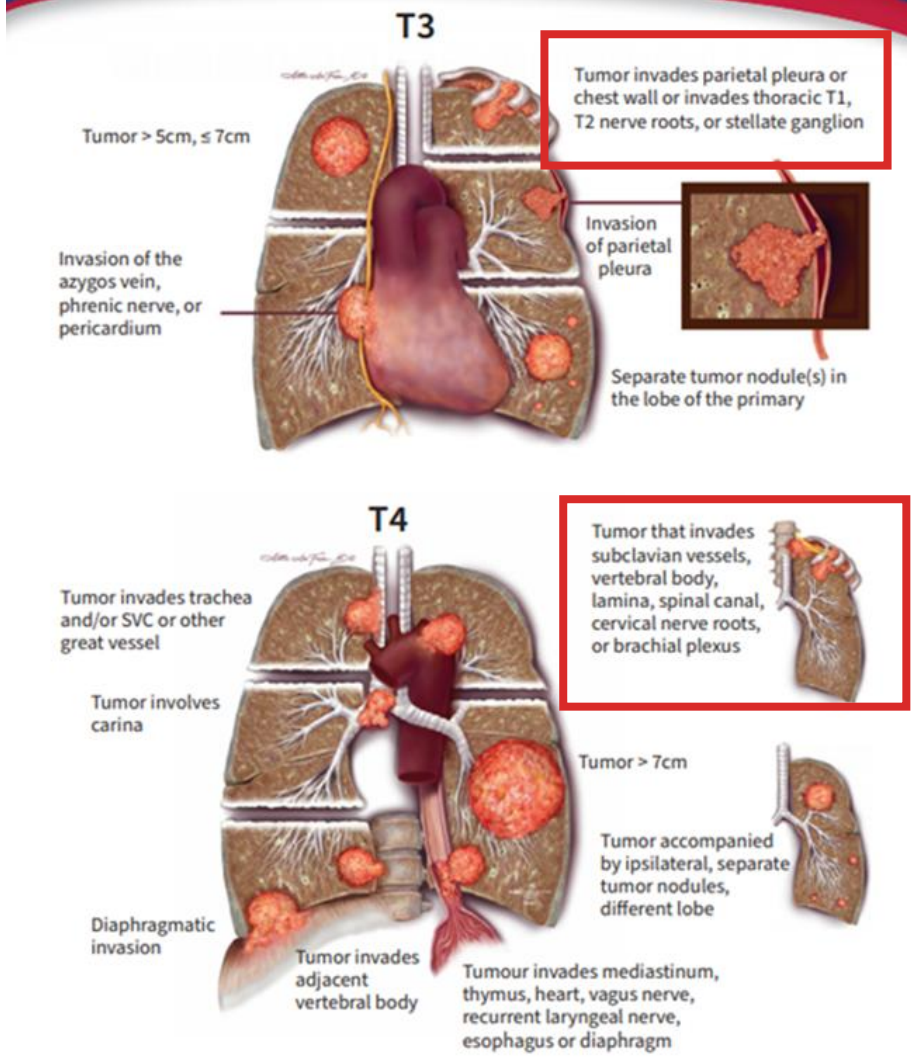

Van Schil PE, Asamura H, Nishimura KK, et al. The IASLC lung cancer staging project: Proposals for the revisions of the T descriptors in the forthcoming ninth edition of the TNM classification for lung cancer. *J Thorac Oncol*. 2024; 19(5):749-765.

GDİ-Neoadjuvan tedavi?

- Akciğer ve GDR → Onkolojik Değerlendirme
- SST hariç T3 tm tedavisinde rolü tartışmalı

- Japonya'da çok merkezli, faz II bir çalışma
  - KTRT + Cerrahi → yüksek patolojik yanıt
    - güvenli ve etkili

Lung Cancer 104 (2017) 79–84

Contents lists available at ScienceDirect

Lung Cancer

journal homepage: www.elsevier.com/locate/lungcan

A prospective, multi-institutional phase II study of induction chemoradiotherapy followed by surgery in patients with non-small cell lung cancer involving the chest wall (CJLSG0801)☆

Koji Kawaguchi[a], Kohei Yokoi[a,*], Hiroshi Niwa[b], Yasuhisa Ohde[c], Shoichi Mori[d], Sakae Okumura[e], Satoshi Shiono[f], Hiroyuki Ito[g], Motoki Yano[h], Kikuo Shigemitsu[i], Yoshinori Hiramatsu[j], Jiro Okami[k], Hideo Saka[l], for the Central Japan Lung Study Group

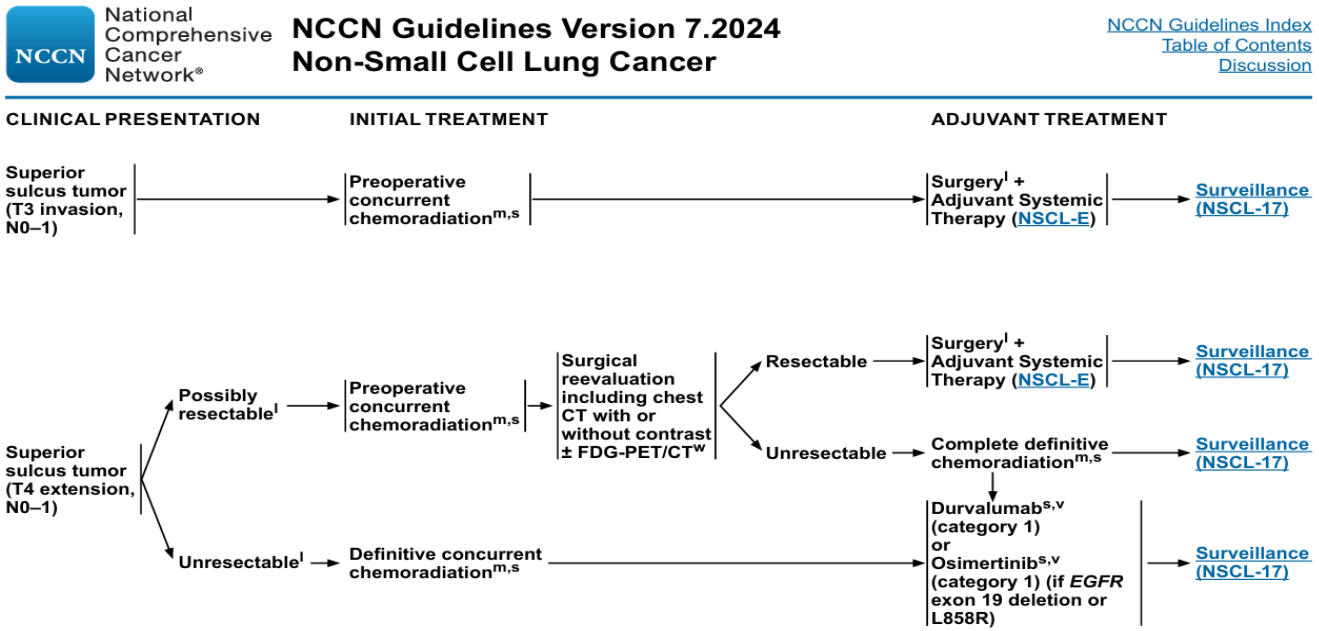

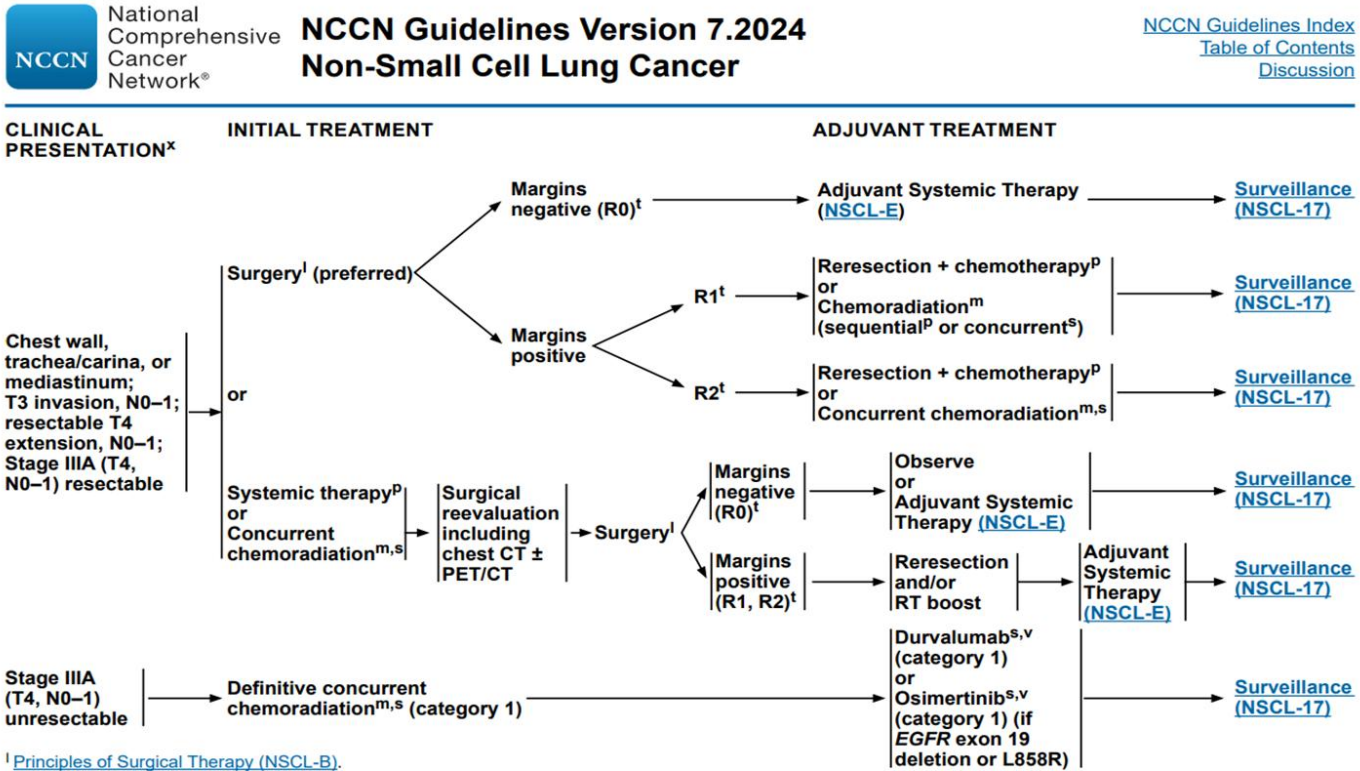

Cerrahi Yaklaşım-GDR

- Mediastinal evreleme →N2 varlığında sağkalım %60 →%20
- Amaç; En Blok GDR ve akciğer rezeksiyonu
- Torakotomi(Geleneksel):
    - Plevral boşluğa, ilgili bölgenin dışında, üstünde veya altında ki interkostal boşluktan girilir

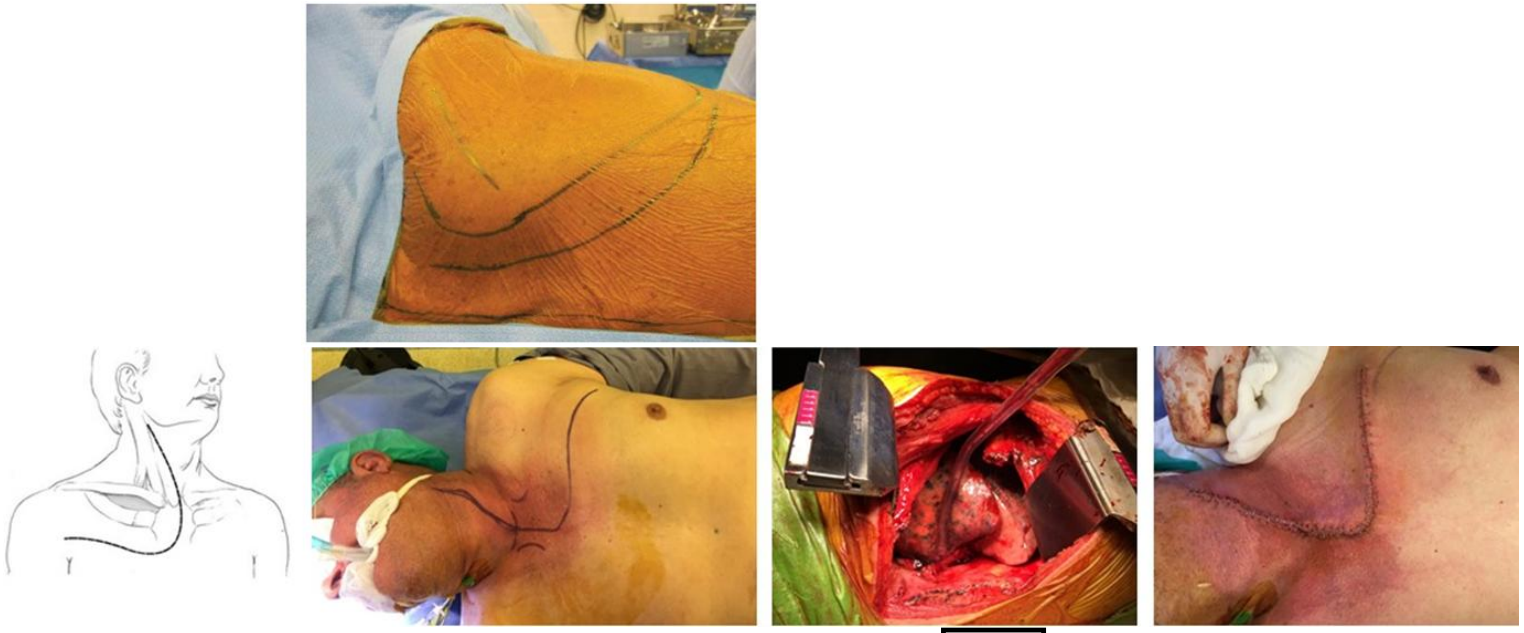

Torakotomi - Skapula retrakte edilmesi

- Sadece Paryetal plevrayı tutan tümörlerde
  - Görüş 1→ Ekstraplevral mobilizasyon yeterli
  - Görüş 2→ En blok GDR, çünkü lokal nüks daha fazla olablir
- Tümörün cerrahi sınırları belirlenir
  - Üst ve alta en az bir kaburga - bir interkostal boşluk ve ön ve arka sınırlar 2-4 cm
  - Tüm alanlardan en az 1 cm

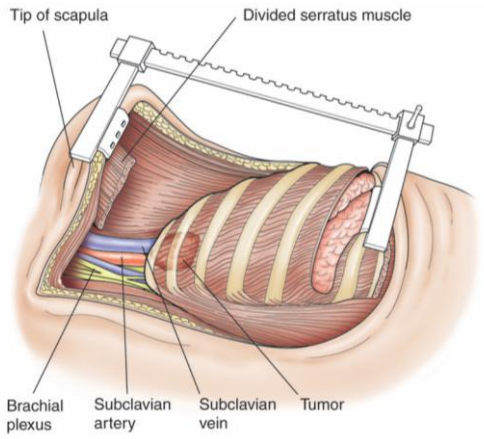

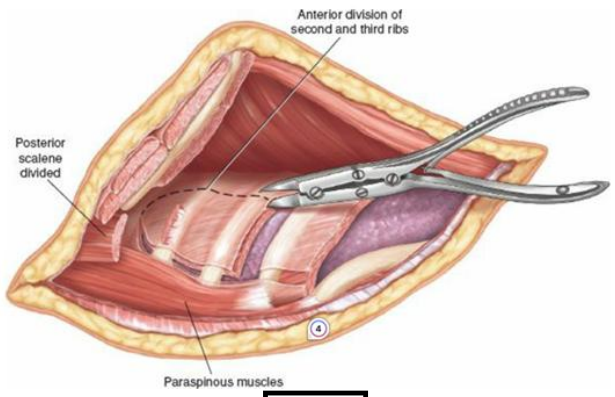

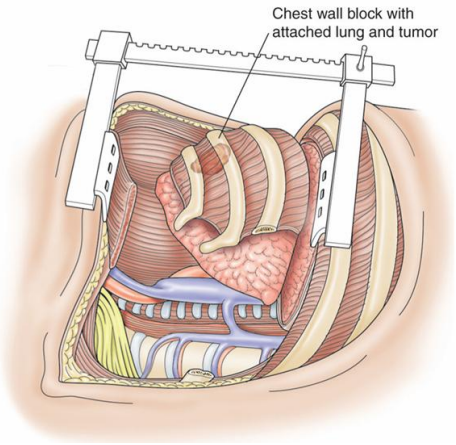

Rekonstrüksiyon

- Amaç:
  - Göğüs duvarının sertliğini ve stabilitesini sağlamak
  - Plevrayı kapamak ve enfeksiyonu önlemek
  - Yelken göğüs ve akciğer herniasyonunu önlemek
- Genel olarak,
  - Göğüs duvarı defektleri <5 cm,
  - Skapula altındaki posterior göğüs duvarı defektleri
  - 2 ve daha az kosta rezeksiyonlarında önerilmez
- kritik bölgeler ise bazal, lateral ve anterior
- Skapulanın ucu defektin içine düşüyorsa rekonstrüksiyonu gerekir

Onkolojik ve cerrahi sonuçlar

- Morbidite %20 üzerinde
- Mortalite %6
  - Standart lobektomiden biraz daha yüksek
  - En sık ölüm nedeni → pulmoner komplikasyonlar
- Adjuvan tedavi
- 5 yıllık sağkalım
  - T3N0 →% 50-70
  - N1 veya N2→ %20
- sağ kalımı etkileyen faktörler→ R0 rezeksiyon ve N0
- Tümör çapı vs çıkartılan kosta sayısı ?

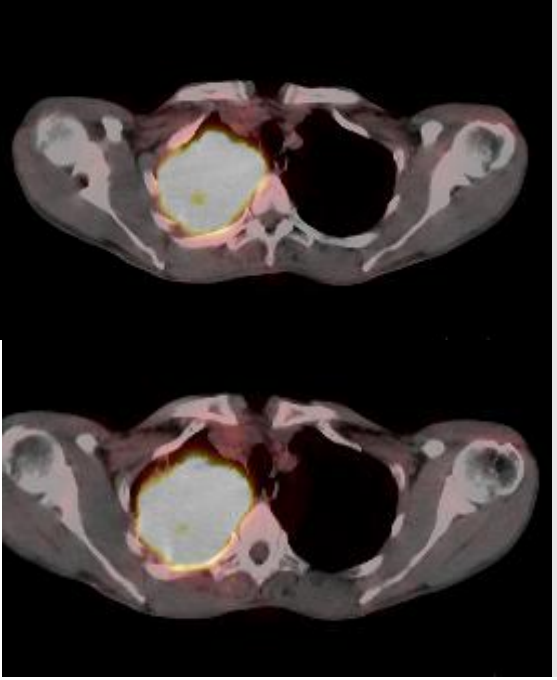

KTRT

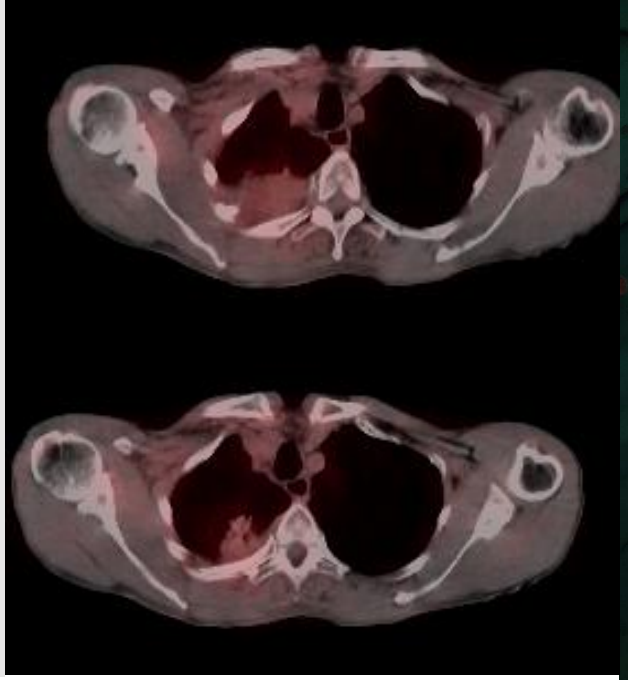

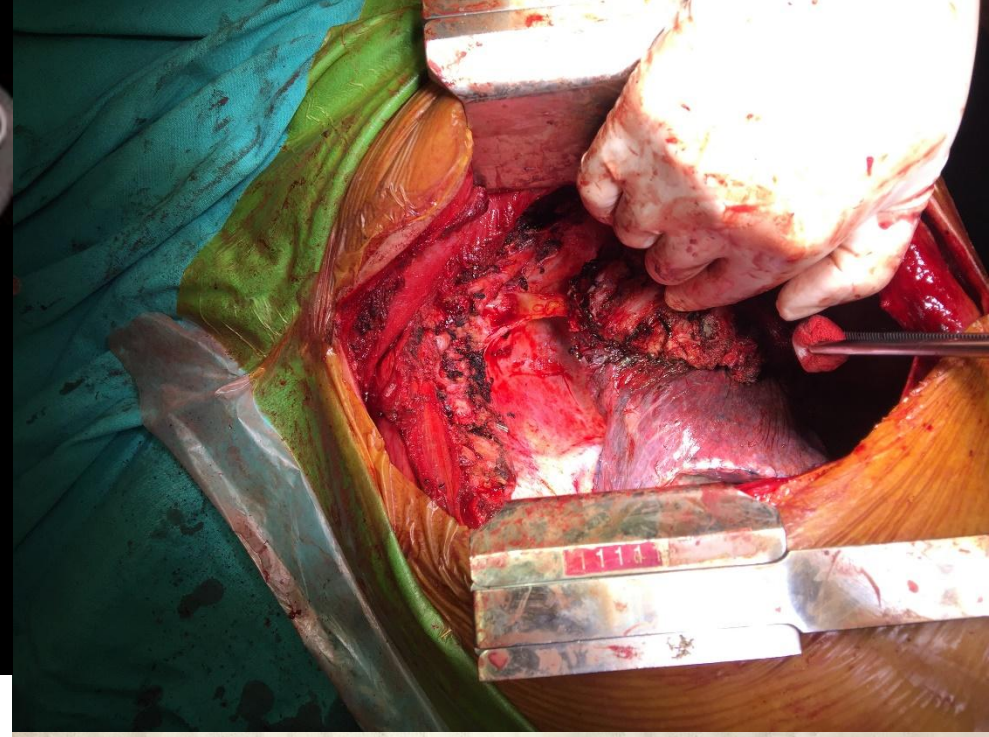

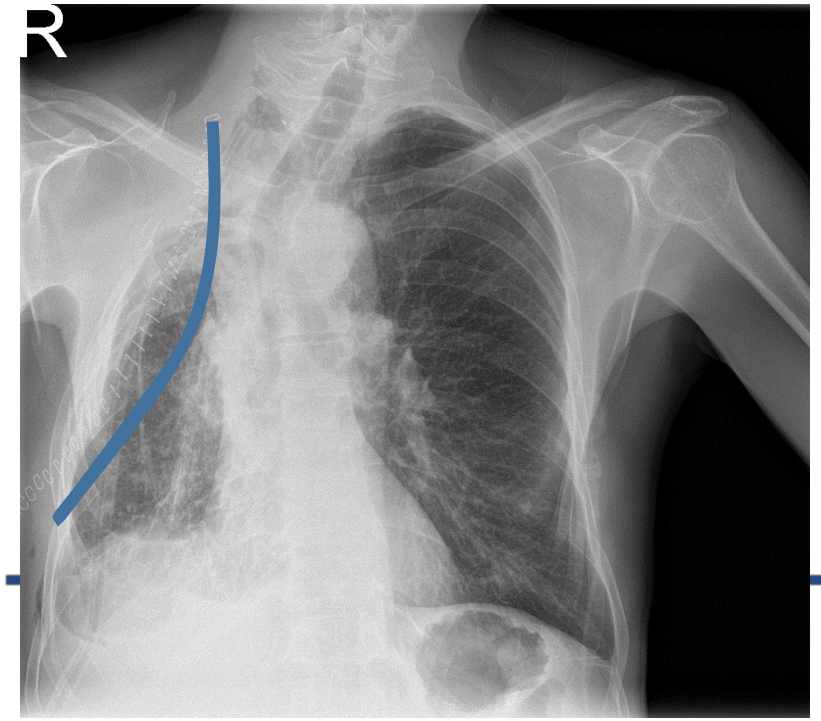

RUL+1-4 Kosta Rez

Olgu

- Dış Merkez P-L Torakotomi
- Ekstraplevral Sağ üst lobektomi,
- Patoloji: Grade 3 Adenokarsinom
  - Tümör çapı: 7.5 cm
  - Göğüs duvarı invaze
  - R2 rezeksiyon
  - pT4N?M0

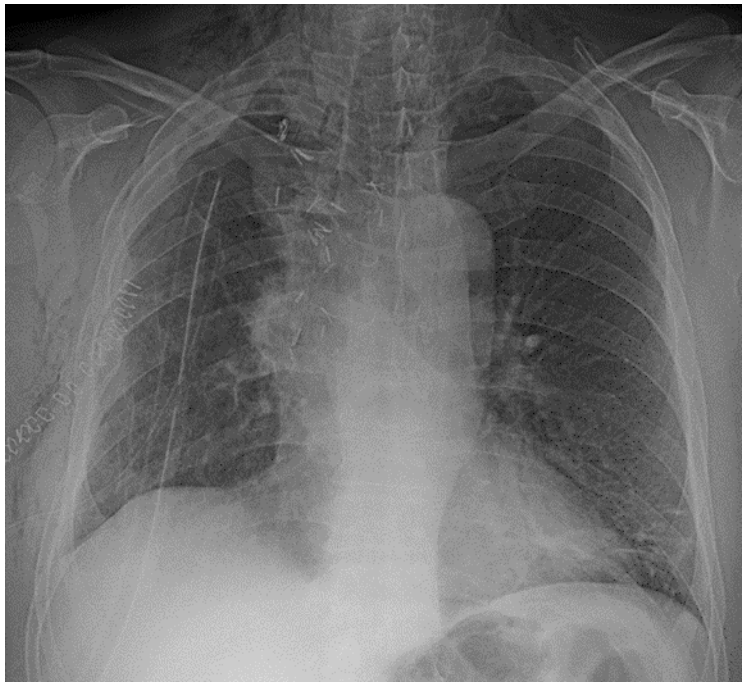

National Comprehensive Cancer Network®

NCCN Guidelines Version 7.2024
Non-Small Cell Lung Cancer

NCCN Guidelines Index
Table of Contents
Discussion

CLINICAL PRESENTATION[x] | **INITIAL TREATMENT** | **ADJUVANT TREATMENT**

- **Chest wall, trachea/carina, or mediastinum; T3 invasion, N0–1; resectable T4 extension, N0–1; Stage IIIA (T4, N0–1) resectable**
  - **Surgery[l] (preferred)**
    - **Margins negative (R0)[t]** → **Adjuvant Systemic Therapy (NSCL-E)** → **Surveillance (NSCL-17)**
    - **Margins positive**
      - **R1[t]** → **Reresection + chemotherapy[p] or Chemoradiation[m] (sequential[p] or concurrent[s])** → **Surveillance (NSCL-17)**
      - **R2[t]** → **Reresection + chemotherapy[p] or Concurrent chemoradiation[m,s]** → **Surveillance (NSCL-17)**
  - **or**
  - **Systemic therapy[p] or Concurrent chemoradiation[m,s]** → **Surgical reevaluation including chest CT ± PET/CT** → **Surgery[l]**
    - **Margins negative (R0)[t]** → **Observe or Adjuvant Systemic Therapy (NSCL-E)** → **Surveillance (NSCL-17)**
    - **Margins positive (R1, R2)[t]** → **Reresection and/or RT boost** → **Adjuvant Systemic Therapy (NSCL-E)** → **Surveillance (NSCL-17)**
- **Stage IIIA (T4, N0–1) unresectable** → **Definitive concurrent chemoradiation[m,s] (category 1)** → **Durvalumab[s,v] (category 1) or Osimertinib[s,v] (category 1) (if *EGFR* exon 19 deletion or L858R)** → **Surveillance (NSCL-17)**

[l] Principles of Surgical Therapy (NSCL-B).

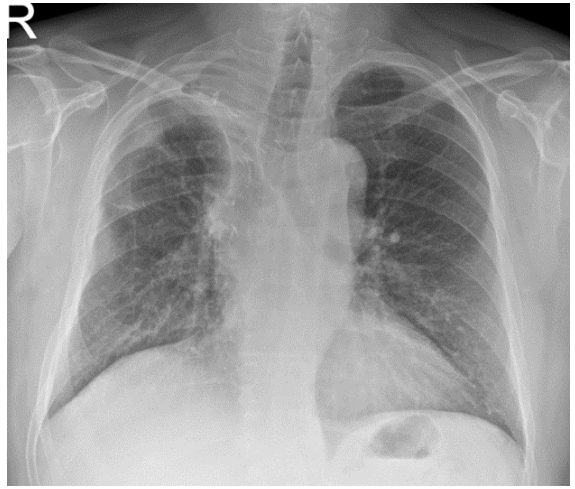

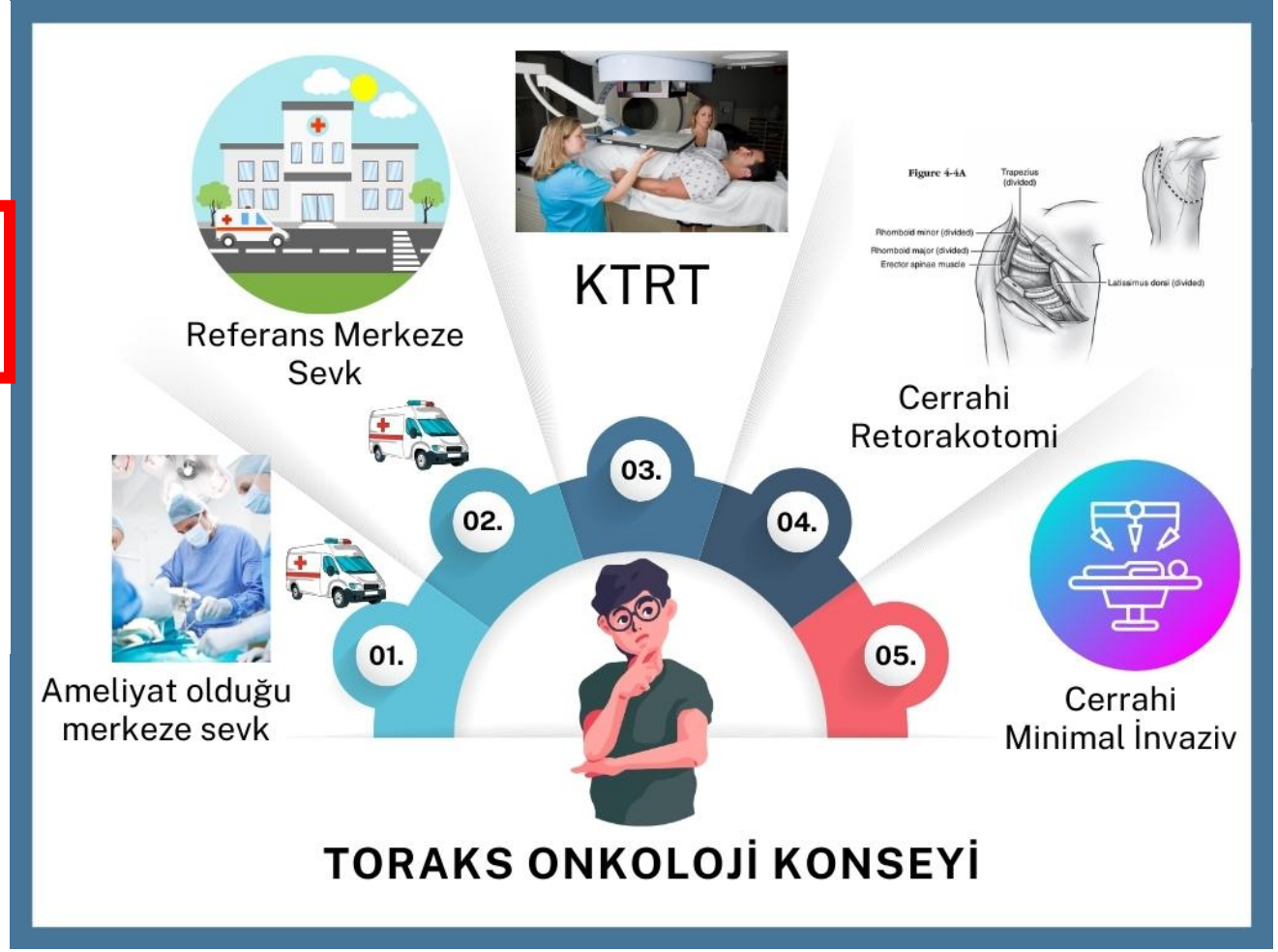

VATS GDR

- İlk VATS lobektomi
- Widmann ve ark. 2000 yılında adenokarsinomlu bir hasta
  - RT + VATS Sol üst lob wedge rezeksiyon + iki kaburga rezeksiyonu

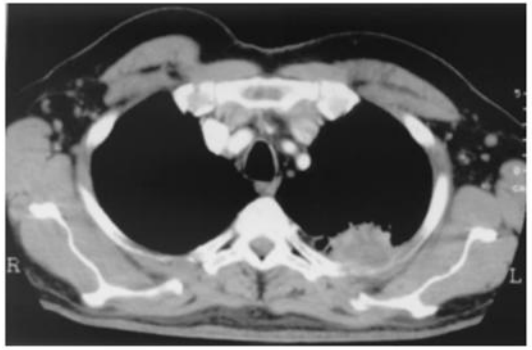

Fig 1. Preradiotherapy chest computerized tomogram.

Fig 3. Postoperative day 1 chest roentgenogram.

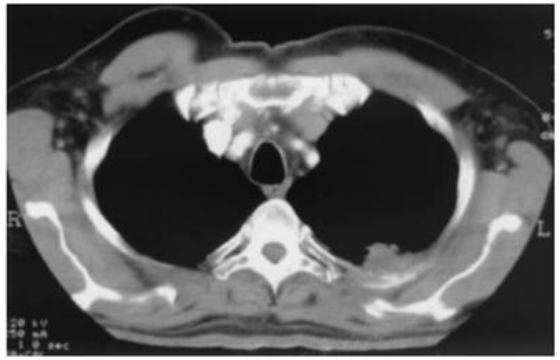

Fig 2. Postradiotherapy computerized tomogram.

VATS – RATS GDR

European Journal of Cardio-Thoracic Surgery 45 (2014) 633–639
doi:10.1093/ejcts/ezt463 Advance Access publication 14 October 2013

ORIGINAL ARTICLE

Video-assisted thoracoscopic surgery lobectomy at 20 years: sensus statement

A. D'Amico[c], Todd L. Demmy[d], Jianxing He[e], Henrik Hansen[f],
behalf of the International VATS Lobectomy Consensus Group

Table 1: Summary of responses regarding the indications and contraindications to VATS lobectomy from the panel of international VATS experts

Indications and contraindications for VATS lobectomy	Number of respondents (%)
T status for tumour	
≤5 cm (T1 and T2a)	16 (32)
≤7 cm (T1, T2a and T2b)	31 (64)
None of above	3 (6)
N status for tumour	
N0 only	1 (2)
N0 + N1	28 (56)
N0 + N1 + N2	21 (42)
Chest wall involvement is	
A contraindication if involving parietal pleura	3 (6)
A contraindication if involving rib(s)	31 (62)
Not a contraindication for VATS lobectomy	16 (32)

(66%, 'recommended') and (vi) VATS lobectomy should be converted to open thoracotomy under the following circumstances: bronchial sleeve (54%, 'recommended'), vascular sleeve (96%, 'highly recommended'), bronchial-vascular sleeve (96%, 'highly recommended'), major bleeding (92%, 'highly recommended') and chest wall invasion by tumour (60%, 'recommended'). No consensus was reached on postoperative local-regional pain management strategies.

VATS Lobektomi GDR Teknikler 1-Full VATS

Thoracoscopic Chest Wall Resection: What Is Its Role?

Todd L. Demmy, MD, Chukwumere E. Nwogu, MD, and Sai Yendamuri, MD

Department of Thoracic Surgery, Roswell Park Cancer Institute and University at Buffalo, Buffalo, New York

Background. Although thoracoscopic operations like pulmonary lobectomy are gaining popularity because of reduced complications and improved quality of life, the role of more complex procedures is unknown.

Methods. From January 2007 to April 2009, 3 patients (2 women) aged 61, 71, and 79 years, underwent thoracoscopic lobectomy with en bloc chest wall resection in an attempt to reduce perioperative morbidity. During the same time, 4 additional patients underwent thoracoscopic explorations before open en bloc resections and 10 underwent thoracotomy to remove primary or secondary chest wall neoplasms. Innovations that facilitated the thoracoscopic operations were the use of an endoscopic rib cutter and division of other chest wall tissues with thermal sealing technology.

Results. Tumors were stage IIb-IIIa and sized 3.2 to 5 cm. Two patients received neoadjuvant therapy before resection. No patients required reconstruction. The first patient required thoracoscopic reexploration to evacuate a hematoma attributed to aggressive anticoagulation required because of high-risk cardiac comorbidities. No other complications occurred. By 3 weeks after resection, the first patient had discontinued narcotics, and the other patients denied pain and analgesic use entirely. All patients were alive, with no evidence of disease, at 26, 16, and 6 months after their operations.

Conclusions. Highly selected cases of lung cancer with chest wall extension are appropriate candidates for thoracoscopic resection. Advanced thoracoscopic instrumentation makes this procedure feasible while following oncologic principles.

(Ann Thorac Surg 2010;89:S2142–5)

© 2010 by The Society of Thoracic Surgeons

- 2007-2009 arası 3 vaka
- Klinik T3N0(n=2), T3N1(n=1)
- NT→ KT (n=1), KTRT(n=1)
- Alt lobektomi (n=2)
- Rekonstrüksiyon yok
- Tm çapı→3-5 cm
- 1 hasta reoperasyon hematom nedeniyle ve bu hastada kr ağrı sendromu
- Takipte nüks yok

VATS Lobektomi GDR Teknikler 1-Full VATS

- Teknik: 3 port insizyon
- Önce GDR sonra - VATS lobektomi
- Hangi hastalar uygun:
  - 4 veya daha az sayıda kaburga rezeksiyonu gerektiren
  - Rekonstrüksiyon gerektirmeyen
  - İnsizyona yakın olan hastalar en uygun

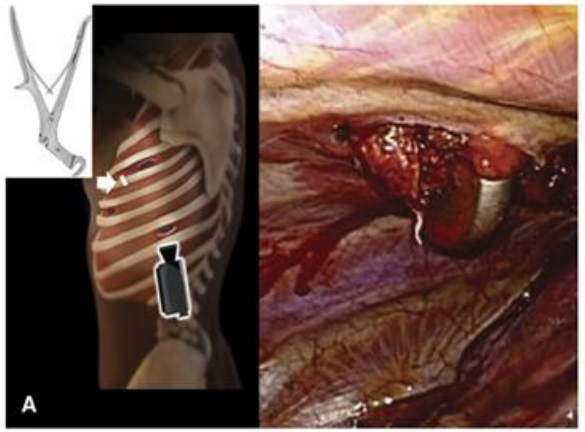

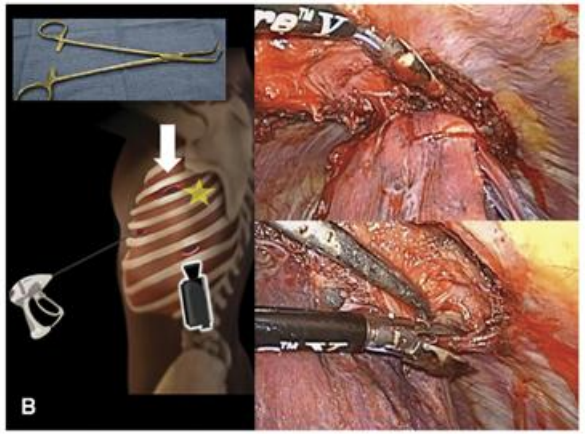

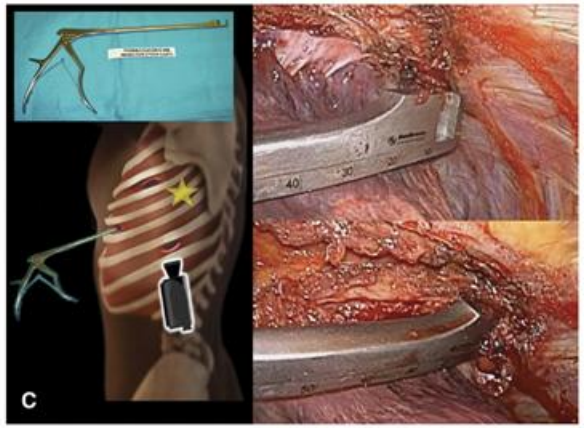

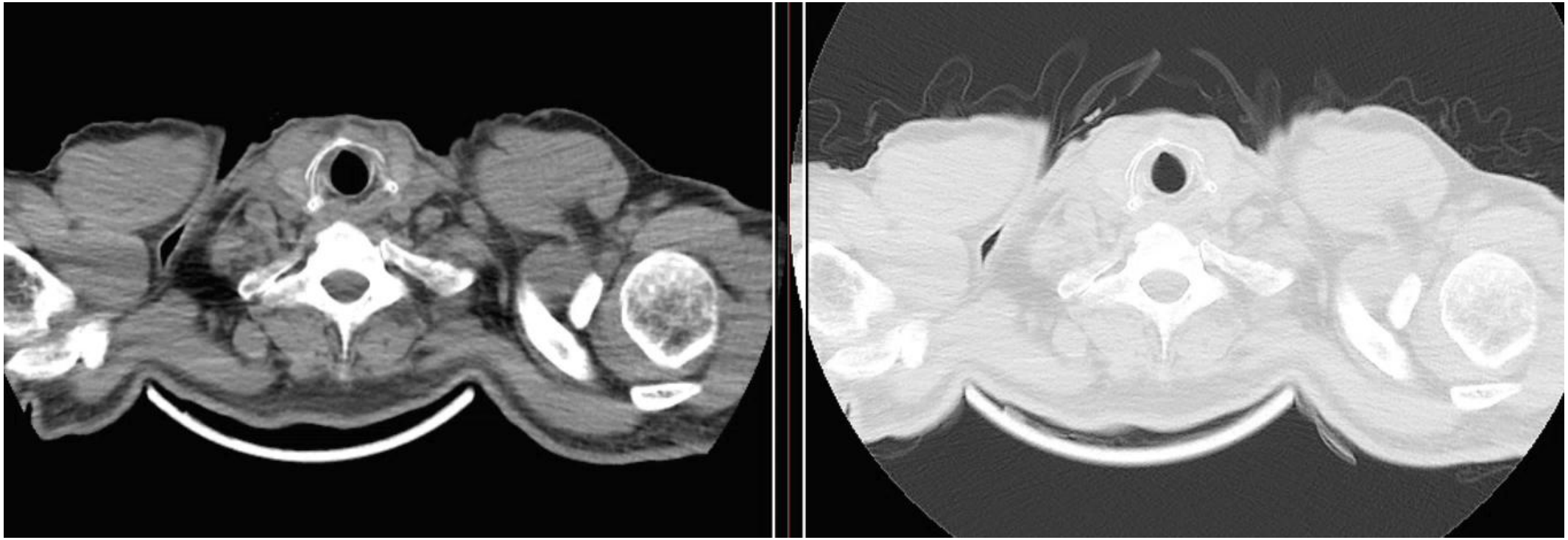

Age:
3/2025
0:52
/---(0/1)
1 Cm:1
nent:

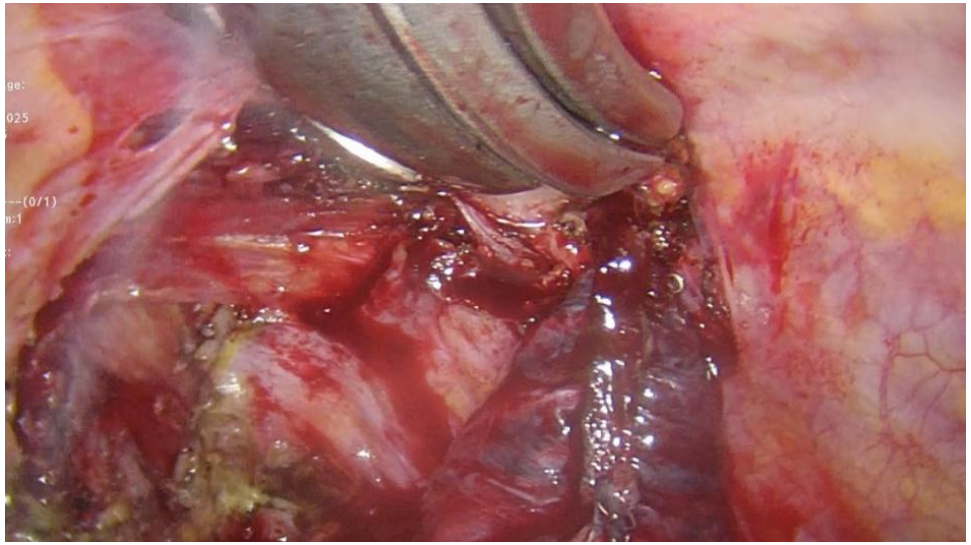

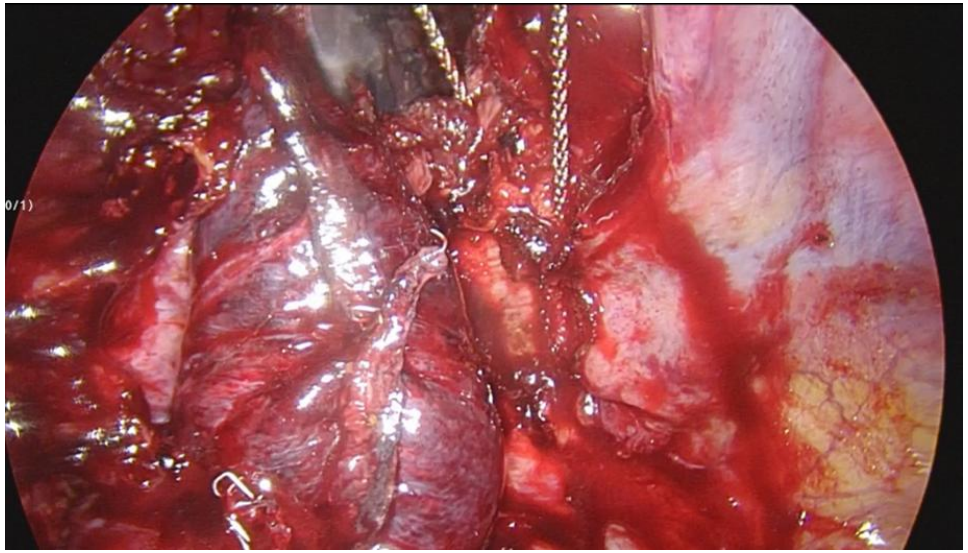

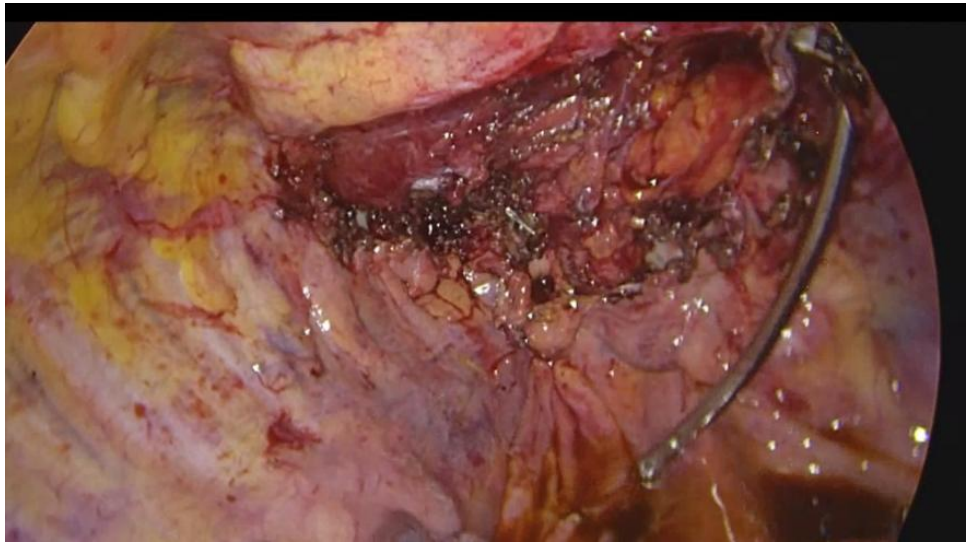

Berry ve ark- Duke (Hybrid)

- İlk VATS lobektomi
- GDİ olan bölgeye Hibrit insizyon
- Doğrudan görüntü veya VATS kılavuzluğunda GDR

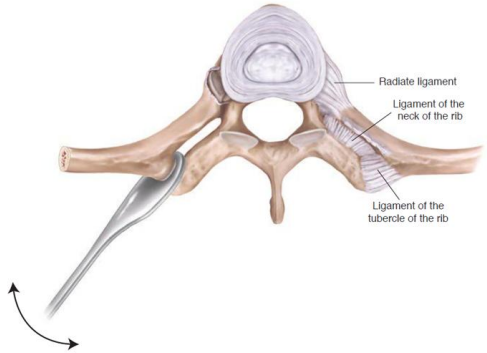

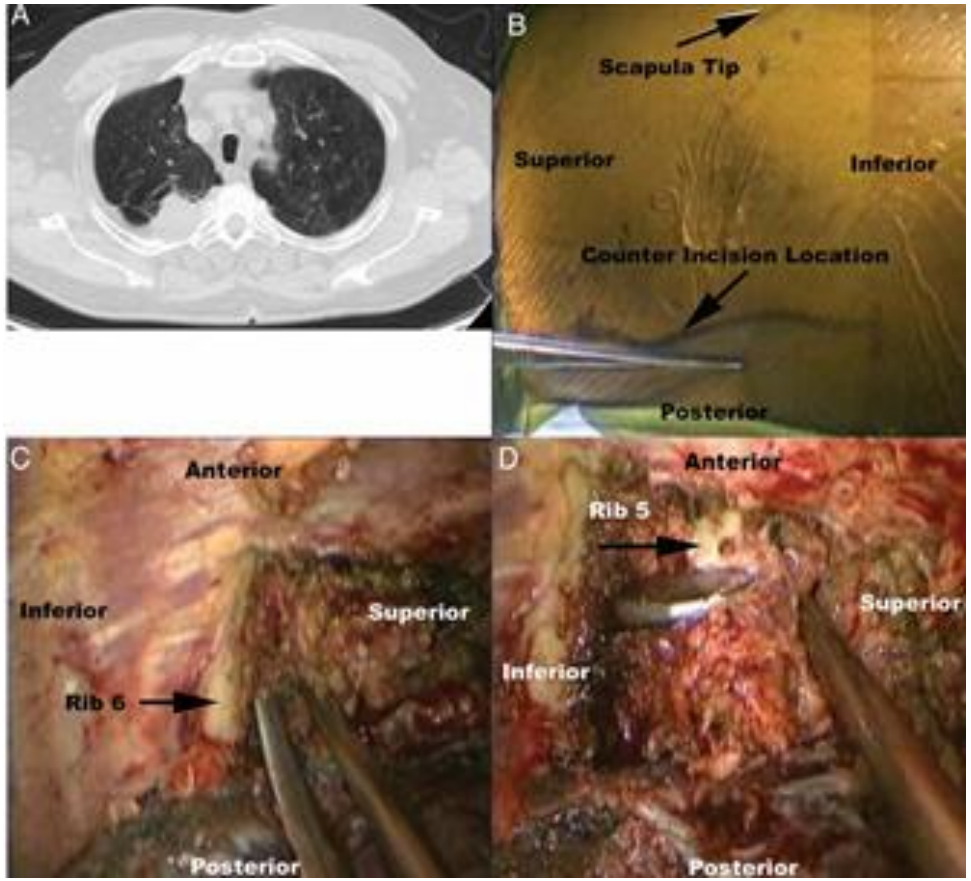

İlk olarak kosta ön taraftan kesilir
arka segment daha fazla hareketlenmesi
Sonra periosteal elevatör yerleştirilir

Berry ve ark- Duke (Hybrid)

- 2000-2010 yılları arasında
- 105 GDR VATS vs torakotomi
  - 95’i torakotomi
  - 12’si (%11) VATS
- %92 üst lob yerleşimli
- 4/12 Hastaya mesh
- %42 morbidite
- Sonuç: Seçilmiş hastalarda uygulanabilir ve etkili
- Onkolojik etkinlikten ödün vermez

Eur J Cardiothorac Surg. 2012 Apr;41(4):888-92. doi: 10.1093/ejcts/ezr150. Epub 2011 Dec 20.

Feasibility of hybrid thoracoscopic lobectomy and en-bloc chest wall resection.

Berry MF[1], Onaitis MW, Tong BC, Balderson SS, Harpole DH, D'Amico TA.

Author information

Abstract

OBJECTIVES: Lobectomy with an en-bloc chest wall resection is an effective but potentially morbid treatment of lung cancer invading the chest wall. Minimally invasive approaches to lobectomy have reduced morbidity compared with thoracotomy for early stage lung cancer, but there is insufficient evidence regarding the feasibility of hybrid thoracoscopic lobectomy chest wall resection. We reviewed our experience with an en-bloc chest wall resection and lobectomy to evaluate the outcomes of a hybrid approach using thoracoscopic lobectomy combined with the chest wall resection where rib spreading is avoided.

METHODS: All patients who underwent lobectomy and en-bloc chest wall resection with ribs for primary non-small cell lung cancer from January 2000 to July 2010 were reviewed. Starting in April 2003, a hybrid approach was introduced where thoracoscopic techniques were utilized to accomplish the pulmonary resection and a limited counter incision was used to perform the en-bloc resection of the chest wall, avoiding scapular mobilization and rib spreading. Preoperative, perioperative and outcome variables were assessed using the standard descriptive statistics.

RESULTS: During the study period, 105 patients underwent en-bloc lobectomy and chest wall resection, including 93 patients with resection via thoracotomy and 12 patients with resection via the hybrid thoracoscopic approach. Complete resection was achieved in all patients in both groups. Tumour size and the extent of resection were similar in the two groups. There were no conversions and no perioperative mortality in the hybrid group. Post-operative outcomes were similar, although patients who underwent the hybrid approach had a shorter length of stay (P = 0.03).

CONCLUSIONS: A hybrid approach that combines thoracoscopic lobectomy and chest wall resection is feasible and effective in selected patients. The use of a limited counter incision without rib spreading does not compromise oncologic efficacy. Further experience is needed to determine if this approach provides any advantage in outcomes, including post-operative morbidity.

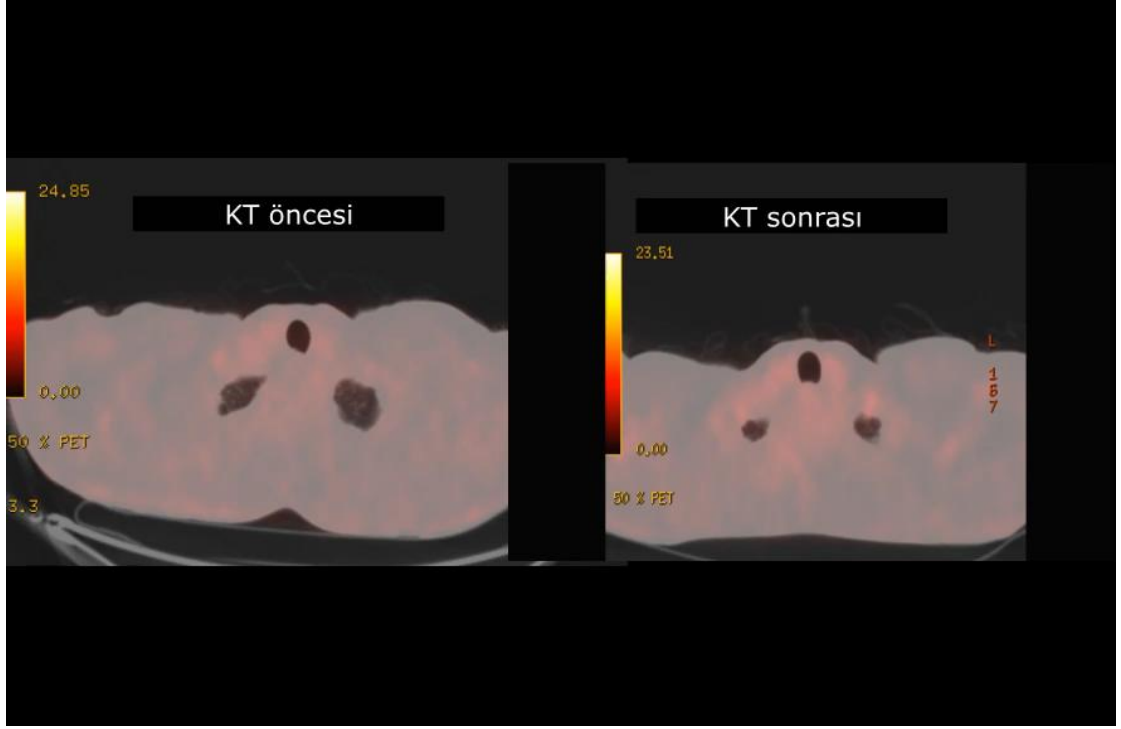
24.85
KT öncesi
0.00
50 % PET
3.3
23.51
KT sonrası
0.00
50 % PET
L
157

Uniportal VATS GDR

- Diego Rivas
- U-VATS ile anatomik akciğer rezeksiyonu ve MLND
- GDR makroskopik rezeksiyon sınırı belirlenir
- GD üzerine ikinci insizyon

Single-incision thoracoscopic right upper lobectomy with chest wall resection by posterior approach.

Gonzalez-Rivas D[1], Fernandez R, Fieira E, Mendez L.

Author information

Abstract

Lobectomy requiring chest wall resection is usually performed by thoracotomy, but thanks to the advances in the field of thoracoscopic surgery, this procedure can be performed by video-assisted thoracoscopic surgery (VATS). Recent improvements in surgical devices and previous VATS experience have allowed this complex surgery for advanced stages to be undertaken safely. Most of the thoracoscopic lobectomies with rib resection are performed using three to four incisions. We report a different minimally invasive technique for chest wall resection (minimally invasive posterior approach) and VATS right upper lobectomy (single-incision anterior approach).

Bayarri ve ark

- Tek port VATS
  - Amaç: GDİ doğrulamak, rezeksiyon sınırlarını ve yerini belirlemek
- GDİ olan yerin üzerine insizyon yapılır
- Ortaya çıkan göğüs duvarı defekti yoluyla akciğer rezeksiyonu

Initial single-port thoracoscopy to reduce surgical trauma during open en bloc chest wall and pulmonary resection for locally invasive cancer.

Bayarri CI[1], de Guevara AC, Martin-Ucar AE.

Author information

Abstract

OBJECTIVES: En bloc pulmonary and chest wall resection is the preferred method of treatment for locally invasive lung carcinoma. However, it carries major trauma to the chest wall, especially in cases with chest wall involvement distant to the potential location of 'traditional' thoracotomies. We describe an alternative method of estimating the boundaries of chest wall resection employing video assisted thoracoscopic surgery (VATS) and hypodermic needles.

METHODS: VATS delineation of boundaries of chest wall involvement by lung cancer has been performed in six patients who gave written consent. In one case the single-port thoracoscopic examination revealed unexpected distant pleural metastases thus preventing from resection. The other 5 patients, three males and two females [median age of 60.5 (range 39 to 75) years] underwent en bloc anatomical lung resection in addition to chest wall excision and reconstruction for T3N0 lung cancer.

RESULTS: In these five cases the chest wall opening was restricted to the extent of the rib excision, and the pulmonary resection was performed via the existing chest wall opening without requiring extension of the thoracotomy or any rib spreading.

DISCUSSION: Minimally invasive techniques aid to delineate the boundaries of chest wall involvement of lung cancer and intraoperative staging. This helped tailoring the surgical approach and location of the thoracotomy, and prevented rib-spreading or additional thoracotomies in our cases.

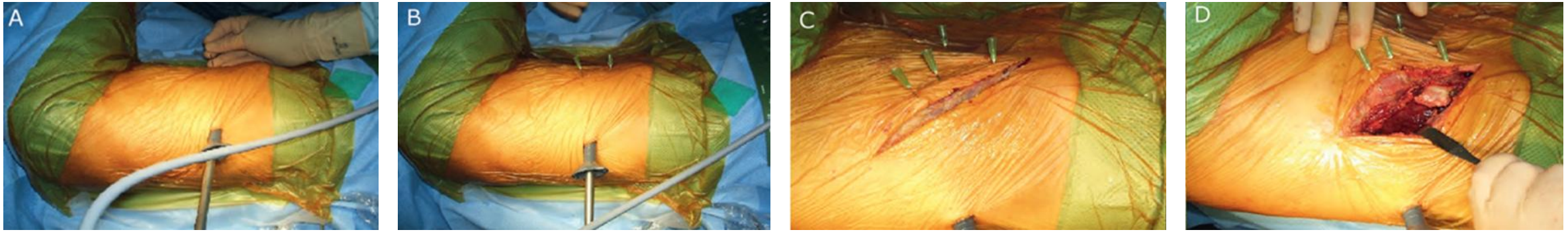

Bayarri ve ark

Avantajları

- Büyük tecrübeye gerek yok
- İntraoperatif evreleme (plevral, göğüs duvarı ve lenf nodu) ile bilgi edinme
- Doğru insizyon seçimi

Initial single-port thoracoscopy to reduce surgical trauma during open en bloc chest wall and pulmonary resection for locally invasive cancer.

Bayarri CI[1], de Guevara AC, Martin-Ucar AE.

Author information

Abstract

OBJECTIVES: En bloc pulmonary and chest wall resection is the preferred method of treatment for locally invasive lung carcinoma. However, it carries major trauma to the chest wall, especially in cases with chest wall involvement distant to the potential location of 'traditional' thoracotomies. We describe an alternative method of estimating the boundaries of chest wall resection employing video assisted thoracoscopic surgery (VATS) and hypodermic needles.

METHODS: VATS delineation of boundaries of chest wall involvement by lung cancer has been performed in six patients who gave written consent. In one case the single-port thoracoscopic examination revealed unexpected distant pleural metastases thus preventing from resection. The other 5 patients, three males and two females [median age of 60.5 (range 39 to 75) years] underwent en bloc anatomical lung resection in addition to chest wall excision and reconstruction for T3N0 lung cancer.

RESULTS: In these five cases the chest wall opening was restricted to the extent of the rib excision, and the pulmonary resection was performed via the existing chest wall opening without requiring extension of the thoracotomy or any rib spreading.

DISCUSSION: Minimally invasive techniques aid to delineate the boundaries of chest wall involvement of lung cancer and intraoperative staging. This helped tailoring the surgical approach and location of the thoracotomy, and prevented rib-spreading or additional thoracotomies in our cases.

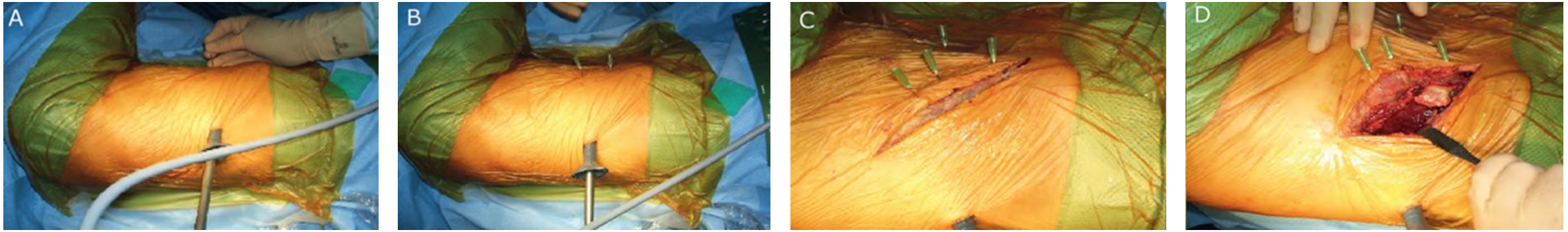

National trends, safety, and effectiveness of minimally invasive concomitant chest wall resection for locally advanced lung cancer

Check for updates

JTCVS 2024

Shawn Purnell, MD,[a,b] Ayham Odeh, MD,[a,b] Richard Freeman, MD, MBA,[a,b] Wissam Raad, MD, FACS,[a,b]
Elliot Servais, MD, FACS,[c] and Zaid Abdelsattar, MD, MS, FACS[a,b,d]

- 2010-2020 yılları arası Lobektomi-GDR yapılan 2837 hasta
- %73,4 Torakotomi
- Dönüşüm oranı: **(%31,3) [**minimal inv. başlayan 756 (%26,6) → **237 (%31,3)]**
- VATS grubunda → Neoadjuvan tedavi ⬇
- Tümör çapı arttıkça→ VATS ⬇ dönüşüm ⬆

- VATS hastanede kalış daha kısa (8.6 gün vs 9.7 gün; P<0.001)
- 90 günlük mortalite %8
- Genel sağ kalım eşdeğer

National trends, safety, and effectiveness of minimally invasive concomitant chest wall resection for locally advanced lung cancer

Check for updates

Shawn Purnell, MD,[a,b] Ayham Odeh, MD,[a,b] Richard Freeman, MD, MBA,[a,b] Wissam Raad, MD, FACS,[a,b] Elliot Servais, MD, FACS,[c] and Zaid Abdelsattar, MD, MS, FACS[a,b,d]

Hastaların %53 ü RATS/VATS ile başlanıyor, dönüşüm olmaksızın %36 tamamlanıyor

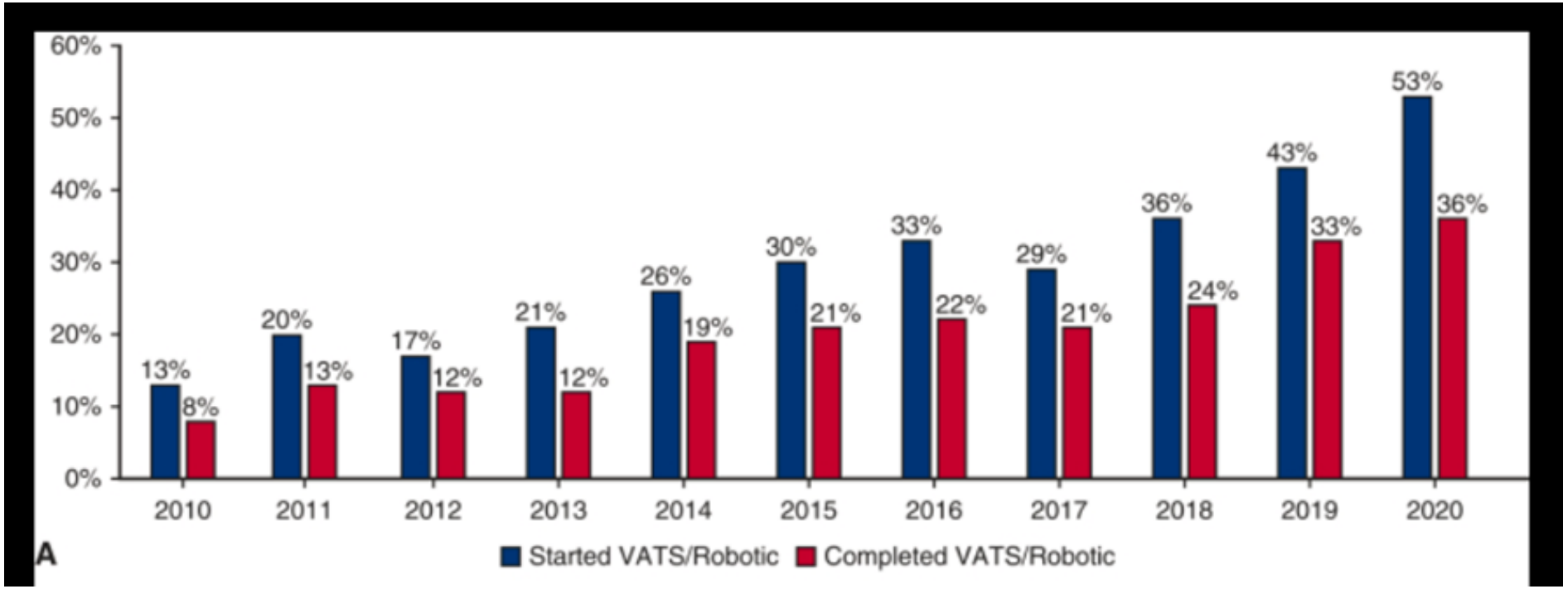

Turkish Journal of Thoracic and Cardiovascular Surgery 2023;31(3):374-380
ORIGINAL ARTICLE / ÖZGÜN MAKALE

Minimally invasive approaches for *en-bloc* anatomical lung and chest wall resection

En-blok anatomik akciğer ve göğüs duvarı rezeksiyonu için minimal invaziv yaklaşımlar

Hüseyin Melek[1], Berker Özkan[2], Hasan Volkan Kara[3], Tolga Evrim Sevinç[1], Erkan Kaba[2], Akif Turna[3], Alper Toker[2], Cengiz Gebitekin[1]

- Ocak 2013 - 2021 →22 hasta
- Cerrahi Teknik: 2 RATS, 18 mVATS, 2 uVATS
- 17 (%77.3) üst lobektomi, 3 (%13.6) alt lob
- 1 kosta →9 (%40.9) 2 kosta →8 (%36.4)
- 3 kosta → 4 (%18.2) 4 kosta →1 (%4.5)

- Tüm hastalarda komplet rezeksiyon sağlandı
- Morbidite →7 (%31.8), mortalite yok
- Beş yıllık genel sağkalım oranı %55.3

Table 1. Pre- and postoperative characteristics of patients

Case	Age/Sex	Surgery	Technique	Neoadjuvant/ Induction treatment	Lung resection	Number of rib resection	Chest wall reconstruction	Operation time	Comp.	Chest drain	Stage	Adjuvant treatment
1	48/M	RATS	No Ad Inc	Cht-RT	RUL	2	No	80	No	2	T3N0M0	Cht
2	69/M	VATS	Hybrid (Bayarri)	No	LUL	1	No	55	No	7	T3N0M0	Cht
3	71/M	VATS	No Ad Inc	No	Seg.	2	No	65	No	5	T3N0M0	No
4	60/F	VATS	Hybrid	No	LUL	3	No	90	PAL	9	T3N0M1	Cht
5	69/M	RATS	Hybrid	Cht-RT	LUL	4	No	140	No	3	T4N0M0	Cht
6	62/M	VATS	Hybrid	No	RUL	2	No	90	PAL/ pneumonia	14	T3N0M0	Cht
7	61/M	VATS	Hybrid	No	RUL	3	No	90	PAL/ pneumonia	14	T4N1M0	Cht
8	67/M	VATS	No Ad Inc	No	RUL	1	No	120	No	3	T3N0M0	No
9	62/M	VATS	No Ad Inc	No	RUL	1	No	100	No	4	T3N0M0	No
10	65/F	VATS	Hybrid	Cht	LLL	2	No	120	No	3	T3N0M0	Cht
11	62/M	VATS	Hybrid	Cht-RT	LUL	2	No	100	No	5	T3N0M0	No
12	58/M	VATS	Hybrid (Uniport)	No	RLL	1	No	105	Pneumonia	12	T3N0M0	No
13	58/F	VATS	Hybrid (Uniport)	No	RUL	1	No	100	No	4	T3N0M0	No
14	57/M	VATS	Hybrid	Cht	LUL	2	No	95	PAL	21	T3NOM1	Cht
15	56/M	VATS	Hybrid	No	RUL	3	No	180	No	3	T3N0M0	Cht
16	75/M	VATS	No Ad Inc	No	LUL	1	No	120	No	4	T3N0M0	No
17	64/M	VATS	No Ad Inc	No	RUL	2	No	160	No	4	T3N0M0	Cht
18	67/M	VATS	No Ad Inc	No	LUL	1	No	90	No	4	T3N0M0	No
19	78/M	VATS	Hybrid	No	RLL	3	No	130	PAL	8	T3N1M0	No
20	67/M	VATS	Hybrid	No	RUL	1	No	140	Hematoma	3	T3N0M0	No
21	55/F	VATS	Hybrid	No	Seg.	1	No	140	No	3	T4N0M0	Cht-RT
22	67/M	VATS	No Ad Inc	No	RUBL	2	Yes	210	No	5	T3N0M0	No

Chest drain: Chest tube drainage time; Comp: Complications; RATS: Robot-assisted thoracic surgery; No Add Inc: No addition incision; Cht-RT: Chemoradiotherapy; RUL: Right upper lobectomy; Cht: Chemotherapy; VATS: Video-assisted thoracoscopy; LUL: Left upper lobectomy; Seg: Segmentectomy; PAL: Prolonged air leak; LLL: Left lower lobectomy; RLL: Right lower lobectomy; RUBL: Right upper Bi-lobectomy.

VATS GDR
SONUÇ

Avantajları

- Benzer onkolojik sonuçlar
- Ameliyat sonrası iyi iyileşme
- Düşük komplikasyon oranları
- Hastanede yatış süresi kısa
- Postoperatif ağrı az

Dezavantajları

- Operasyon süresi daha uzun
- Vaka serileri az

Melek H, Özkan B, Kara Volkan H, Sevinç Evrim T, Kaba E, Turna A, et al. Minimally invasive approaches for en-bloc anatomical lung and chest wall resection. Turk Gogus Kalp Dama 2023;31:374-380

GDR Uludağ Deneyimi

Ocak 2016 -2024 KHDAK → n=842 (GDR → n= 47 (%5,6))
NT n=33 , 2 vertebra, 9 pankoast

Torakotomi n=31	VATS n=16
Komplet rez. %90,3	Komplet rez. %87,5
Morbidite %67,7 (UHK)	Morbidite %50 (UHK)
Mortalite n=1 (%3)	Mortalite n=1 (%6)
Yatış süresi 13,6 gün	Yatış süresi 7,7 gün

J Laparoendosc Adv Surg Tech A. 2025 Apr 10. doi: 10.1089/lap.2024.0369. Online ahead of print.

Benefits and Radiological Preference Criteria of Hybrid-Video-Assisted Thoracic Surgery in the Treatment of Pancoast Tumor. A Comparative Study with Open Approaches

Melike Ülker [1], Volkan Erdoğu [1], Merve Ekinci Fidan [1], Celal Buğra Sezen [1], Ayşegül Çiftçi [1], Ece Yasemin Demirkol [1], Abdul Samed Alp [1], Reşit Akyel [1], Özgür İşgörücü [1], Muzaffer Metin [1]

Background: We tried to demonstrate the use and benefits of hybrid-video-assisted thoracic surgery (VATS) in Pancoast tumors by comparing it with open surgical approaches. ***Methods:*** Between January 2022 and January 2024, 29 patients operated for Pancoast tumor were retrospectively evaluated. Hybrid-VATS approach was used in 14 cases, while open surgery was used in 15 cases. The two groups were compared regarding demographic characteristics, preoperative and postoperative findings. Preoperative thoracic computed tomography findings were analyzed by an experienced radiologist to guide the choice of surgical approach. ***Results:*** The hybrid-VATS technique was statistically significantly superior to the thoracotomy group in terms of operative time and preoperative bleeding amount (*P*: .027, .012, respectively). There were statistically significantly fewer postoperative complications in the hybrid-VATS group (66.6% versus 21.4%, *P*:. 04). In preoperative thorax CT evaluation, the longest distance (>77 mm) at which the tumor invaded the chest wall was found to be statistically predictive in the choice of surgical approach (odds ratio: 7.3, *P*:. 01). ***Conclusions:*** Hybrid-VATS can be used in Pancoast tumor surgery in experienced centers with shorter operation time, less preoperative bleeding, and low postoperative complication rates compared with open surgery without compromising oncological principles. Preoperative thoracic CT may guide the choice of surgical approach.

Hibrit-iki port VATS GDR

Patoloji

10) MALİGN TÜMÖRAL İNFİLTRASYON; 4 nolu lenf nodu kodlu doku

İMMÜNOHİSTOKİMYASAL BOYAMA SONUÇLARI
(9 nolu blok)
TTF1: Pozitif
NAPSİN: Pozitif
CK7: Pozitif
PLAP: Negatif
OCT 3/4: Negatif
PANCK: Pozitif
CD30: Negatif

HİSTOKİMYASAL BOYAMA SONUÇLARI
AB: Fokal pozitif
MÜSİN: Fokal pozitif

NOT: Histopatolojik, immünohistokimyasal bulgular Primer Akciğer Adenokarsinom metastazı ile uyumludur. Rezeksiyon materyalinde kostalara ait uç cerrahi sınırlar intakttır. Tümörün yumuşak doku komponenti fibröz bir psödokapsül yapısı ile çevrilidir. Tümörde perinöral invazyon mevcuttur.

Gönderilen materyal 10 ayrı kaptadır.
1) Göğüs duvarı, 2.kosta posterioru iple 4.kosta anterioru klipsle işaretli gönderilen 2.kostası 5,5 cm uzunlukta 1,8x1, cm çapta, 3.kostası 6,5 cm uzunluğunda 1,5x1,2 cm çapında 4.kostası 7,2 cm uzunluğunda 1,5x1,2 cm çapında 3 adet kot içeren gri kahverengi renkte kemikli doku parçalarıdır. Göğüs duvarı posterioruna yapışık şekilde 2x1,6x1,3 cm boyutunda gri kahverengi renkte lezyon dikkati çekti. Lezyonun kesit yüzeyi gri beyaz renkte izlendi. Kesilebilen yerlerinden 2 parça 1 kasette (1) takibe alındıktan sonra kalan dokular dekal takibine alındı.
Göğüs duvarı dekal takibi sonrası
2. interkosta posterior cerrahi sınır 2 parça 1 kasette (22)
2. interkosto anterior cerrahi sınırın 1 parça 1 kasette (23)
3. interkosto posterior cerrahi sınırın 1 parça 1 kasette (24)
3. interkosto anterior cerrahi sınırın 1 parça 1 kasette (25)
4. interkosto posterior cerrahi sınırın 1 parça 1 kasette (26)
4. interkosto anterior cerrahi sınırın 1 parça 1 kasette (27) kalan doku dekal takibine alındı. Dekal takibi sonrası lezyonu

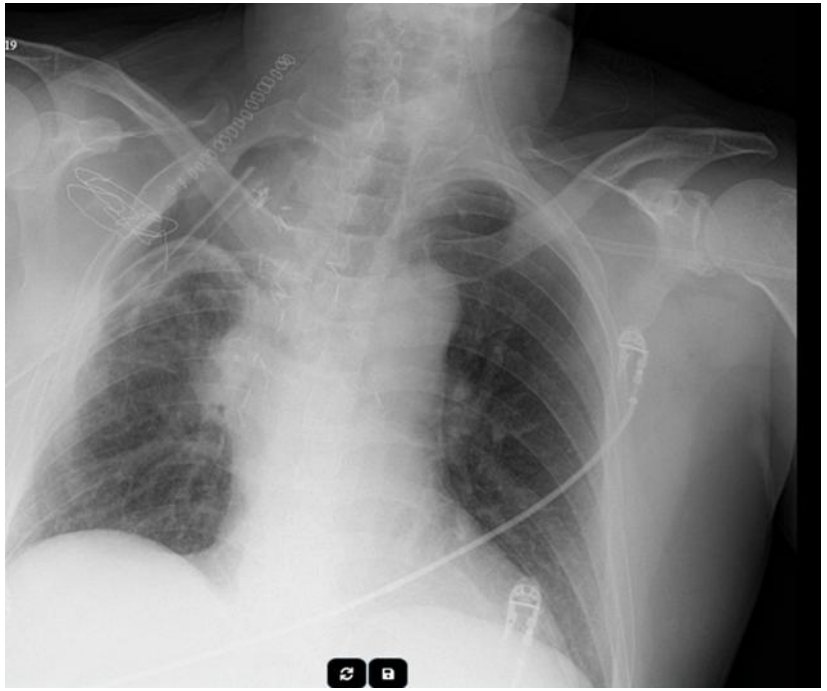

Cerrahi sınırlar negatif
Rezidu tümör +
4R+

5. Yıl kontrol Toraks BT

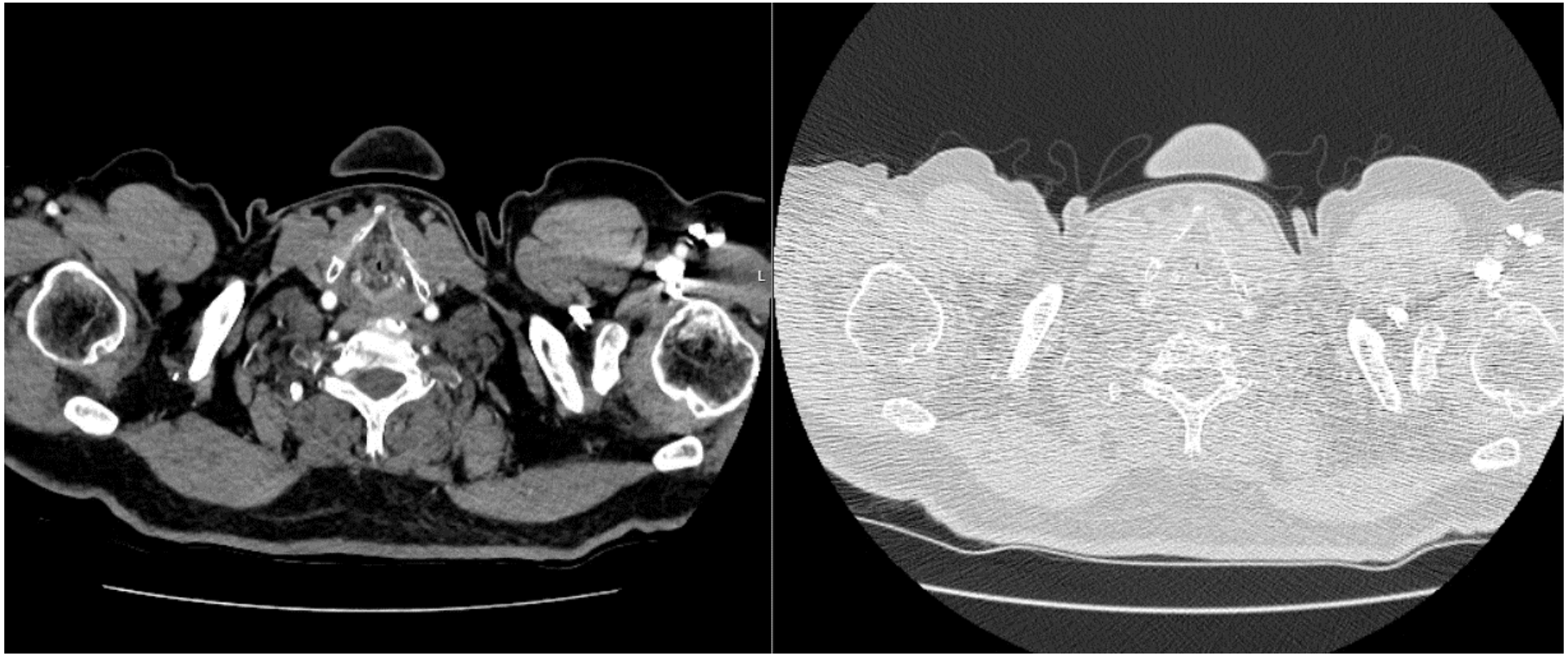

Olgu 2
Torakotomi? VATS?

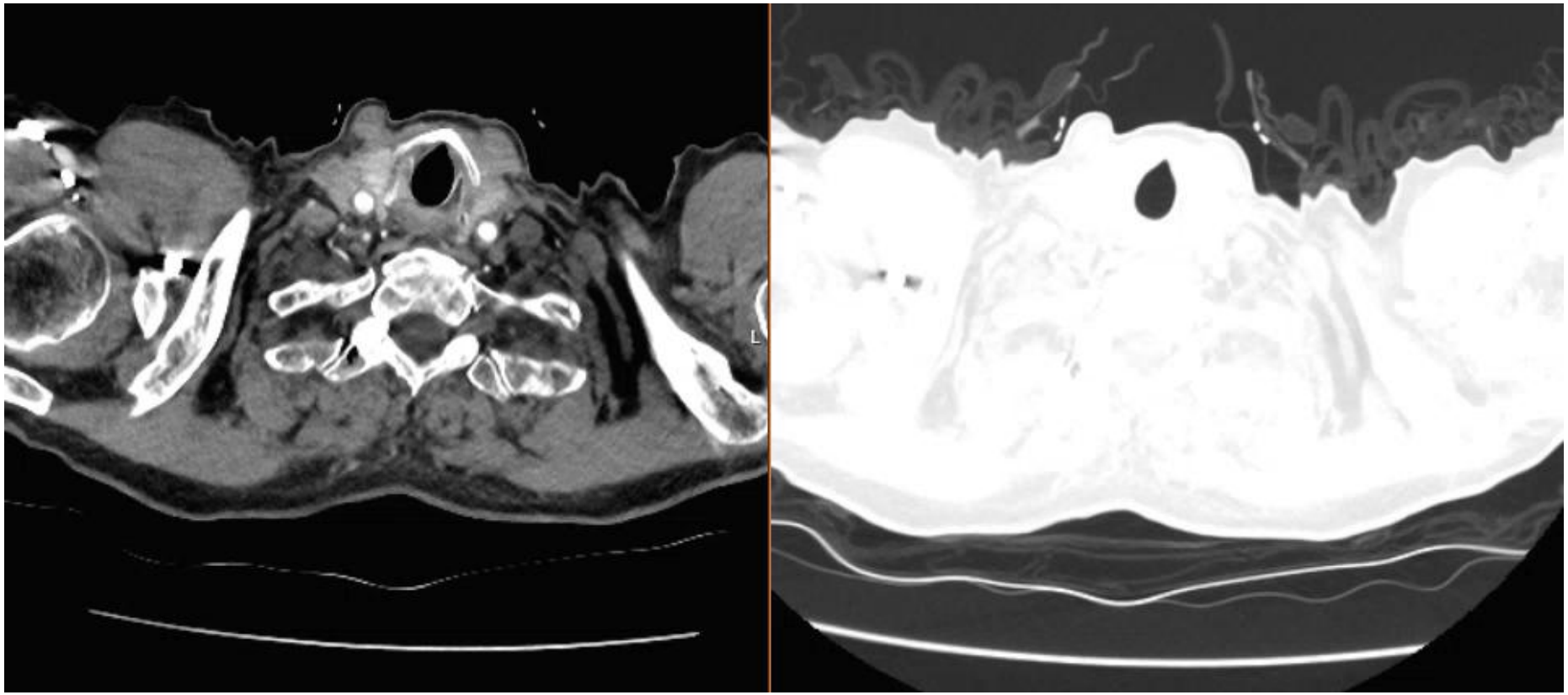

SOL VATS EKSPLORASYON

TORAKOTOMİ İLE SOL ÜST DİVİZYONEKTOMİ+ALT LOB Sup Segm Wedge GDR (3-4-5)

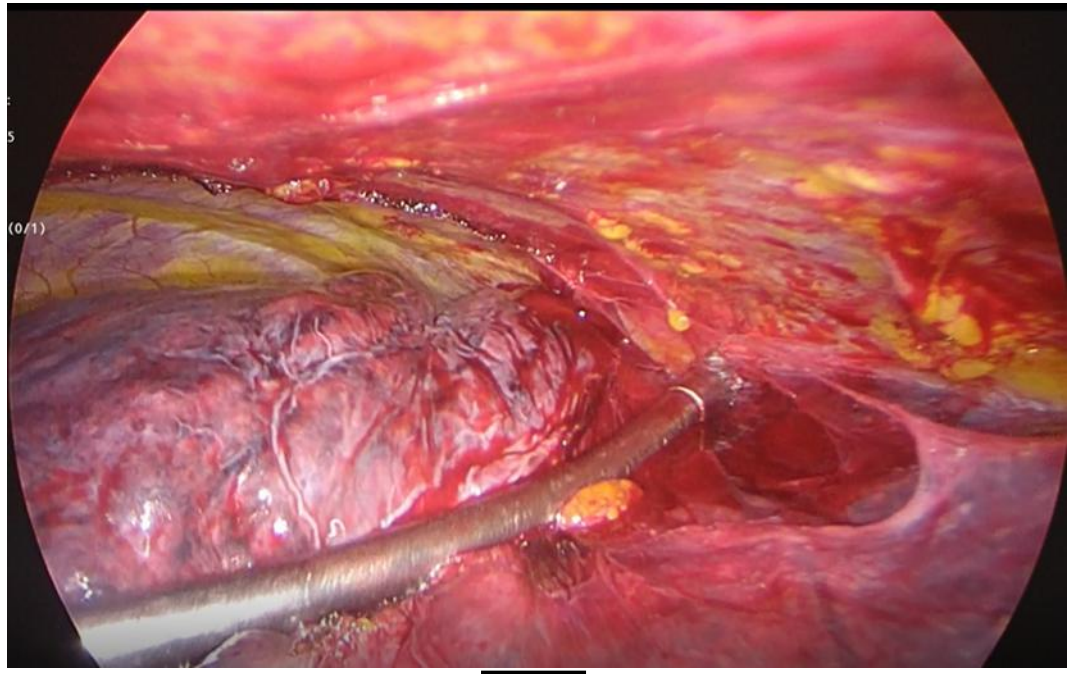

GDİ – Akılda kalanlar

- Sağ kalımı etkileyen en önemli faktör
  - komplet rez
  - N0
- NT için yeterli veri yok
  - Süperior sulcus tümör hariç
- GD cerrahi sınır→ her yönde en az 1 cm ve üstü
- 5 cm'den küçük göğüs duvarı defektleri rekonstrüksiyon olmadan yönetilebilir
- minimal invaziv yaklaşımların hastalara sağladığı faydaları gördükçe, sınırları zorlamaya devam etme isteği artmaya devam ediyor

ilginiz için teşekkürler...