

# Akciğer Grafisi Olgular

Prof.Dr. Akın Kaya  
Ankara Ün. Tıp Fakültesi  
Göğüs Hastalıkları

### • BOX 3.1 How to Look at a Chest X-Ray

Determine the age, sex, and history of the patient

Identify the projection and technique used:

AP, PA, lateral, portable, or standard distance

Identify the position of the patient:

Upright, supine, decubitus, lordotic

Look at the inspiratory effort:

Adequate, hypoinflated, hyperinflated

Identify the obvious and common abnormalities:

Heart size, large or normal

Heart shape, specific chamber enlargement

Upper mediastinal contours

Examine airway, tracheal deviation

Lung symmetry

Any mediastinal shift?

Hilar position

Lung infiltrates, masses, or nodules

Pulmonary vascularity

Increased, decreased, or normal

Lower greater than upper

Pleural effusions, blunting of costophrenic angles

Rib, clavicle, or spine fractures or other lesions

Check tube placement

Recheck what you thought was normal anatomy, and look at

typical blind spots:

Behind the heart

Behind the hemidiaphragms

In the lung apices

Pneumothorax present?

Costophrenic angles

Chest wall

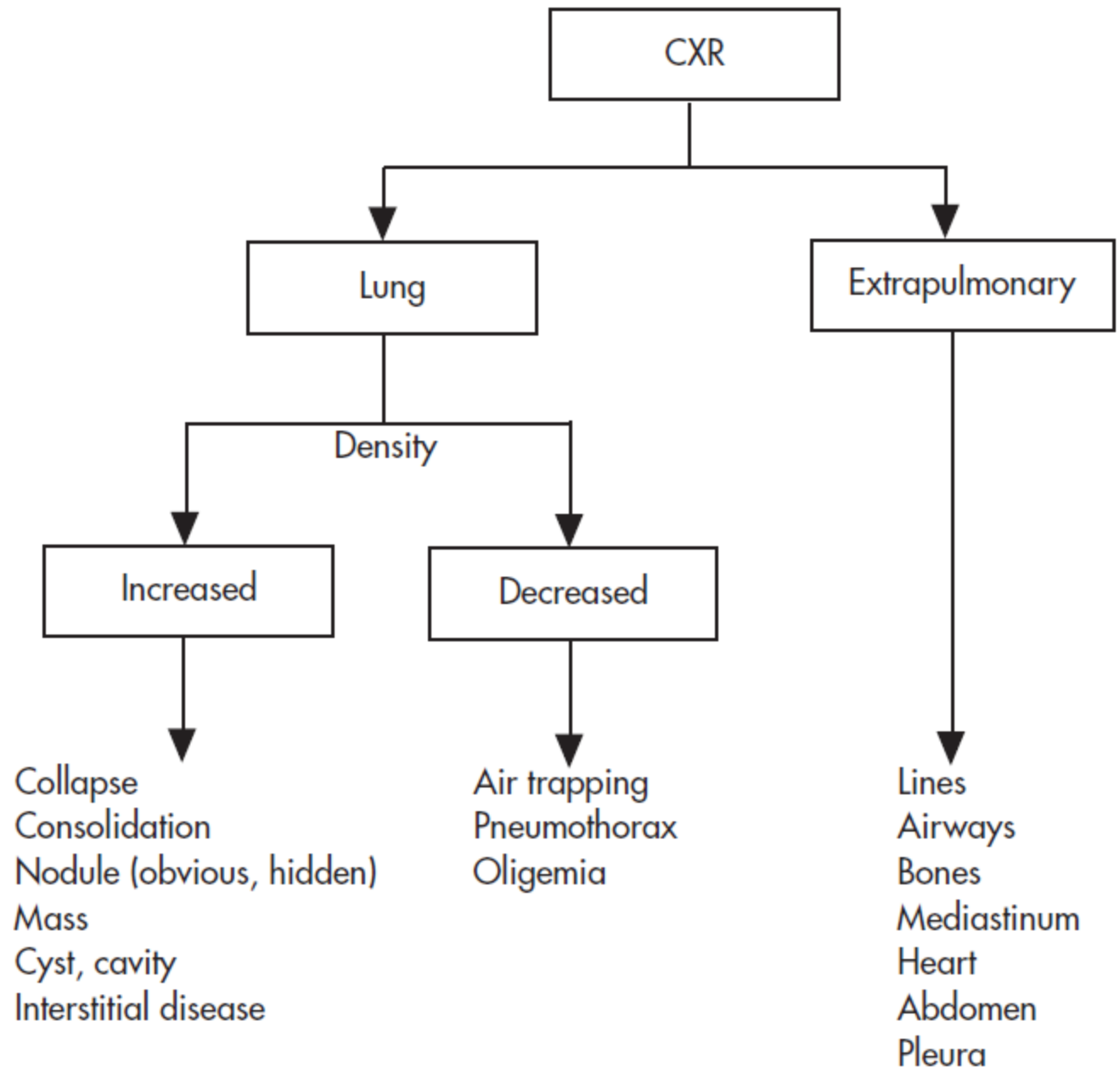
Lytic rib lesions

Shoulders

Look for old images, not just the last one

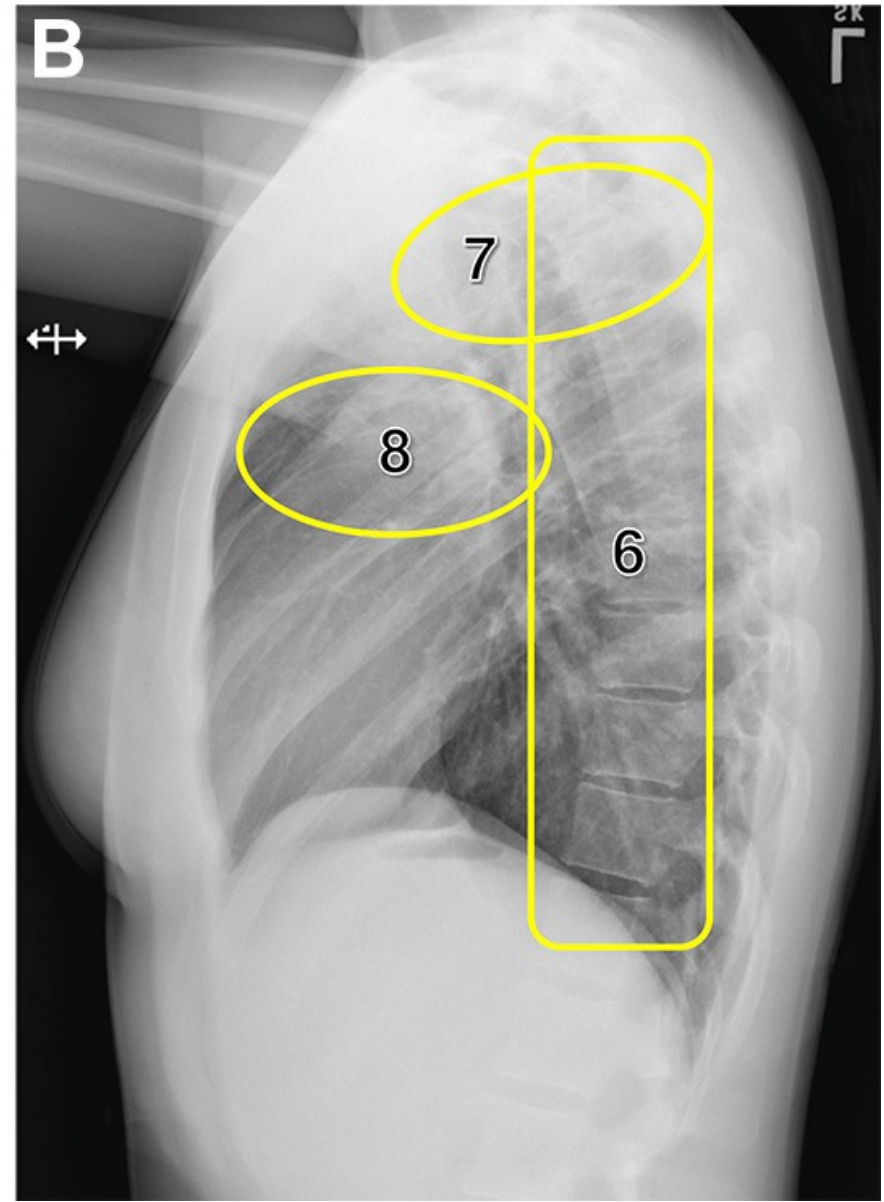
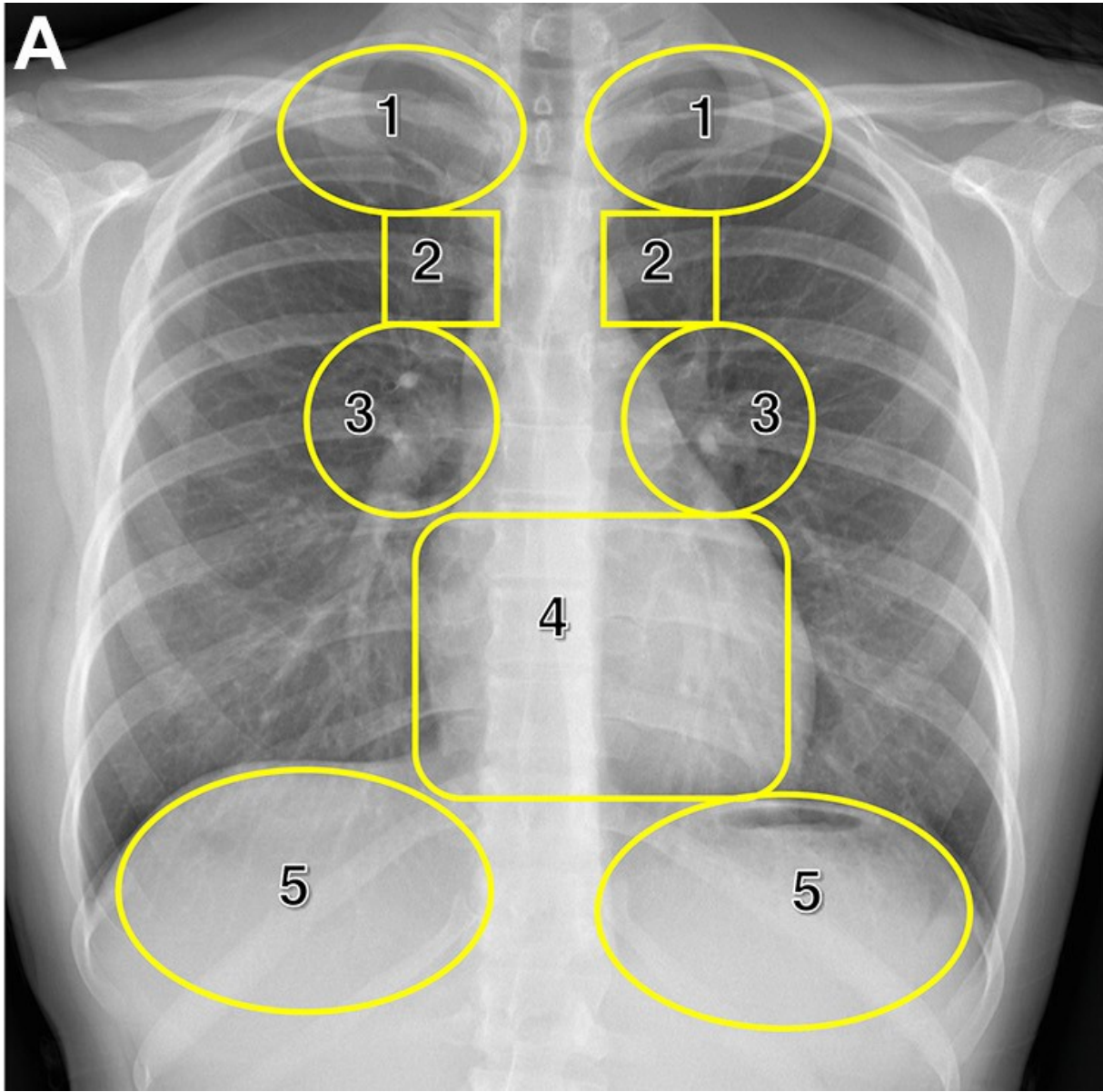
Decide what the findings are and their location

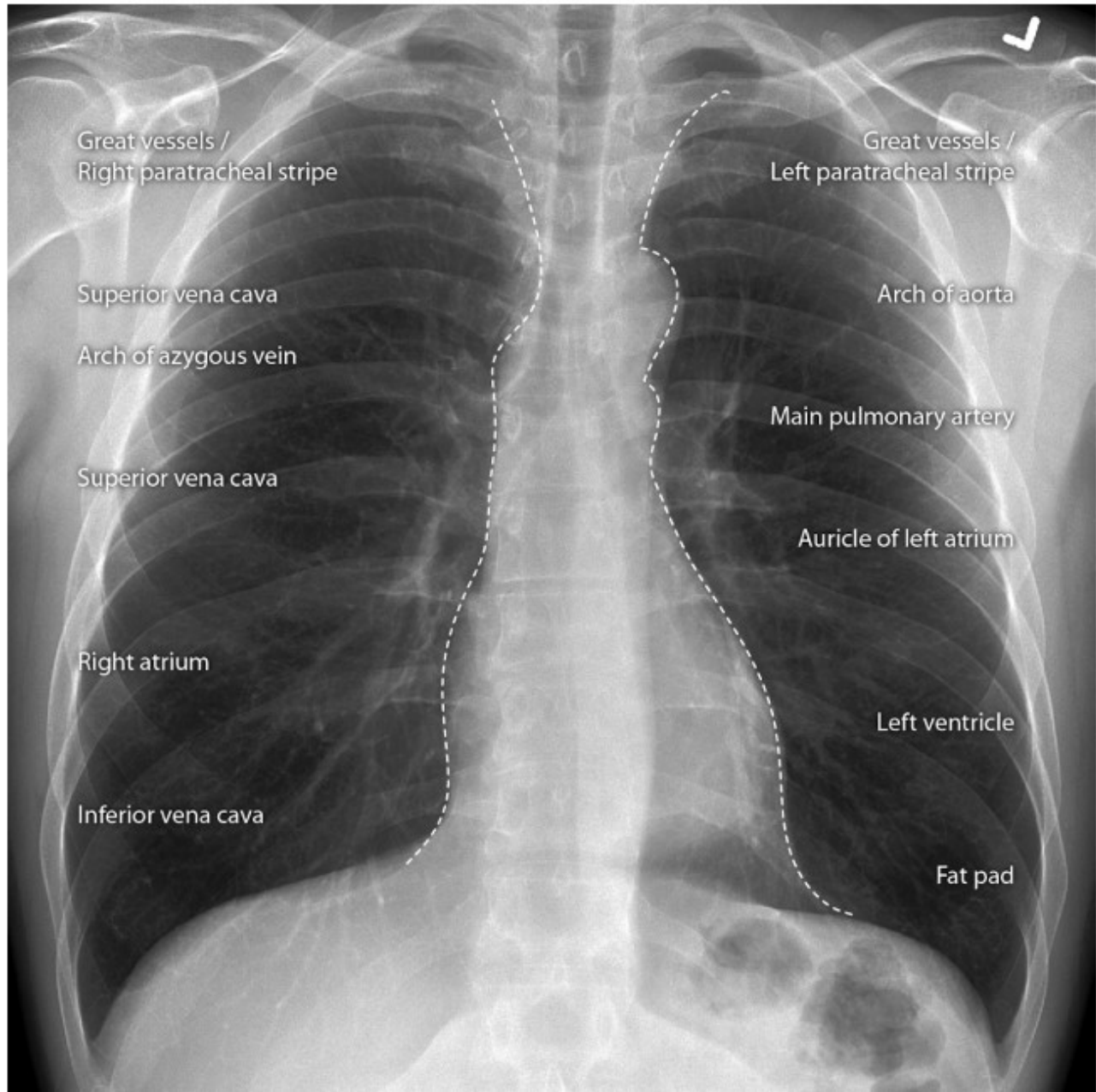
Give a common differential diagnosis correlated with the clinical history



**TABLE 3 ] Commonly Missed Findings and Major Approaches to Avoiding These Errors**

Sequential Search	Commonly Missed Findings	Avoiding Errors
Lungs	<ul style="list-style-type: none"> <li>• Nodule, mass                             <ul style="list-style-type: none"> <li>◦ Superior sulcus tumor</li> </ul> </li> <li>• Pneumonia</li> <li>• Lobar atelectasis</li> </ul>	<ul style="list-style-type: none"> <li>• Second look at all blind spots</li> <li>• Lateral CXR image (if available)</li> <li>• Attention to asymmetric opacity, hilar displacement</li> </ul>
Pleura	<ul style="list-style-type: none"> <li>• Subtle pneumothorax                             <ul style="list-style-type: none"> <li>◦ Supine</li> <li>◦ Tension</li> </ul> </li> <li>• Pleural effusion</li> </ul>	<ul style="list-style-type: none"> <li>• Detection of thin visceral pleural line</li> <li>• Deep sulcus sign</li> <li>• Depressed diaphragm, mediastinal shift</li> <li>• Posterior costophrenic angle blunting lateral</li> </ul>
Trachea and central bronchi	<ul style="list-style-type: none"> <li>• Stenosis                             <ul style="list-style-type: none"> <li>◦ Primary tumor, scarring</li> </ul> </li> <li>• Displacement                             <ul style="list-style-type: none"> <li>◦ Extrinsic mass (thyroid, other)</li> </ul> </li> </ul>	<ul style="list-style-type: none"> <li>• Search cervical trachea to mainstem bronchi</li> </ul>
Hila	<ul style="list-style-type: none"> <li>• Mass, lymphadenopathy</li> <li>• Enlarged pulmonary arteries (pulmonary hypertension)</li> </ul>	<ul style="list-style-type: none"> <li>• Size, configuration, density, position</li> </ul>
Mediastinum/Heart	<ul style="list-style-type: none"> <li>• Mass, lymphadenopathy</li> <li>• Aortic aneurysm, dilatation</li> <li>• Widening (bleed)</li> <li>• Pneumomediastinum, pneumopericardium</li> </ul>	<ul style="list-style-type: none"> <li>• Mediastinal contours</li> <li>• Mediastinal lines</li> <li>• Cardiac contours</li> <li>• Abnormal air collections</li> </ul>
Upper abdomen	<ul style="list-style-type: none"> <li>• Pneumoperitoneum</li> </ul>	<ul style="list-style-type: none"> <li>• Continue visual search below diaphragms</li> </ul>
Bones	<ul style="list-style-type: none"> <li>• Fractures</li> <li>• Metastases</li> </ul>	<ul style="list-style-type: none"> <li>• Lateral: spinal compression fractures</li> <li>• Ribs, clavicles, shoulders, proximal humeri, spine, sternum</li> </ul>
Hardware	<ul style="list-style-type: none"> <li>• Malpositioned lines, tubes</li> </ul>	<ul style="list-style-type: none"> <li>• Focused search</li> </ul>
Foreign bodies	<ul style="list-style-type: none"> <li>• Abnormal, retained, radiopaque foreign bodies</li> </ul>	<ul style="list-style-type: none"> <li>• Review clinical history</li> <li>• Dedicated search</li> </ul>





Great vessels /  
Right paratracheal stripe

Superior vena cava

Arch of azygous vein

Superior vena cava

Right atrium

Inferior vena cava

Great vessels /  
Left paratracheal stripe

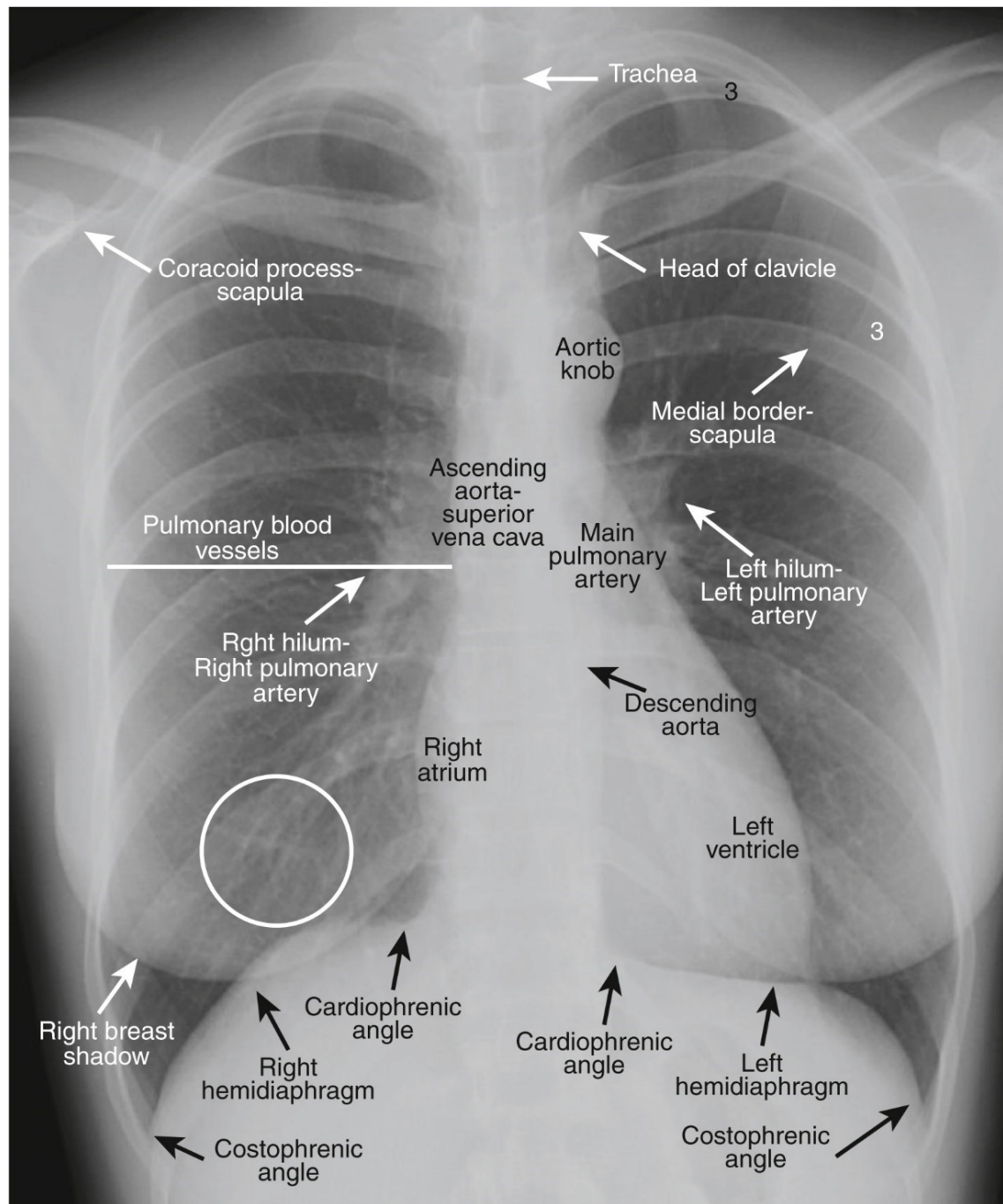
Arch of aorta

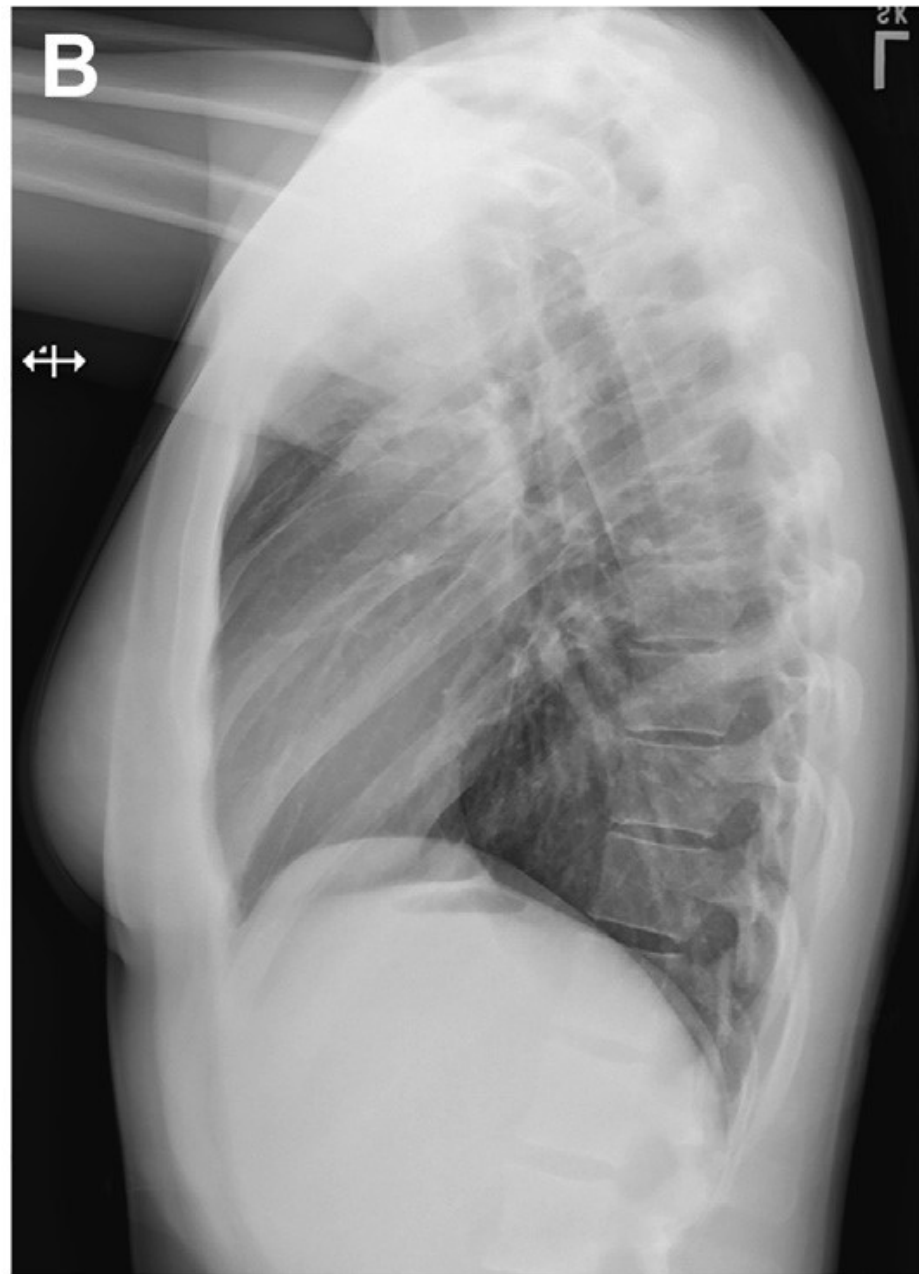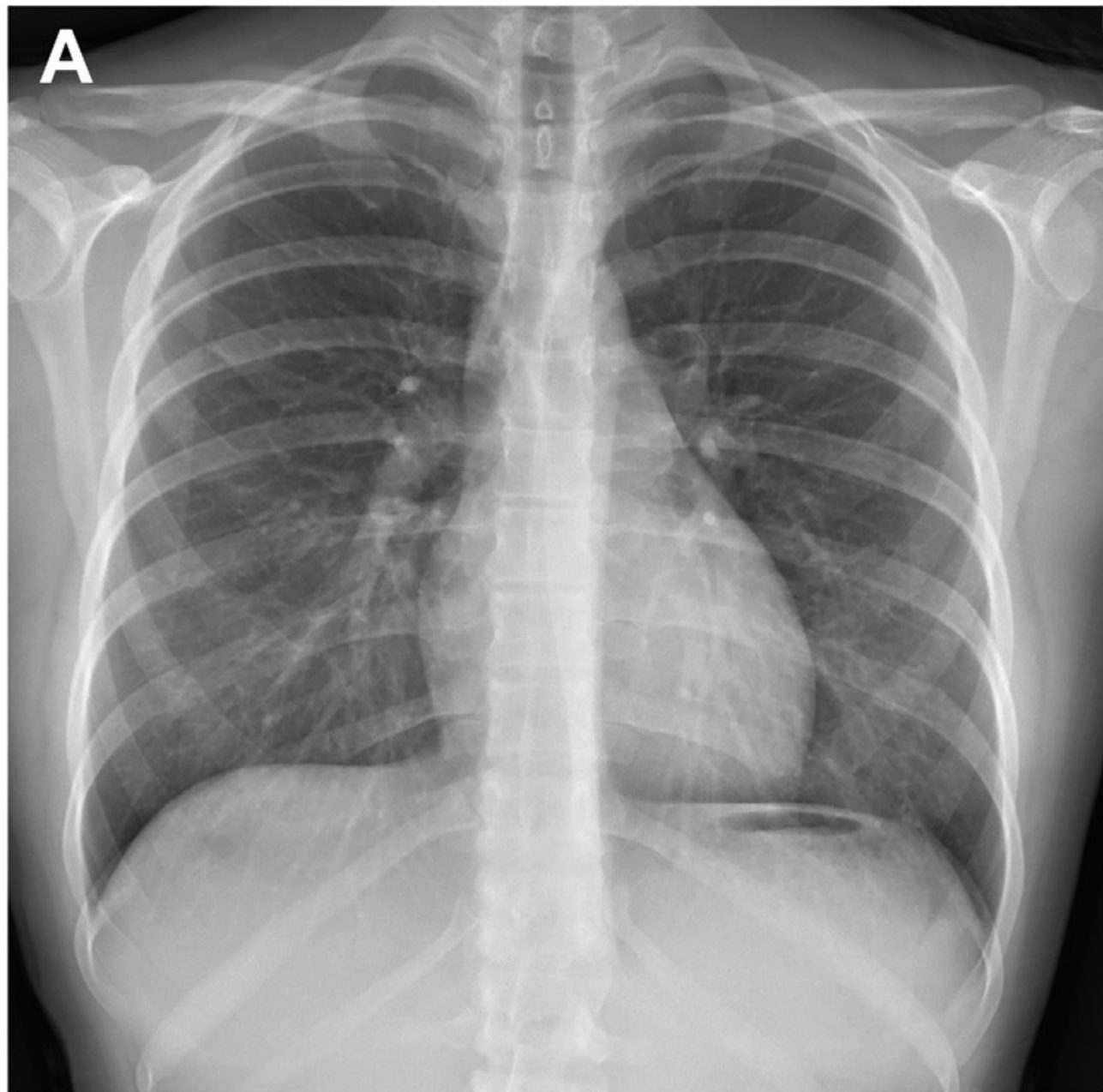
Main pulmonary artery

Auricle of left atrium

Left ventricle

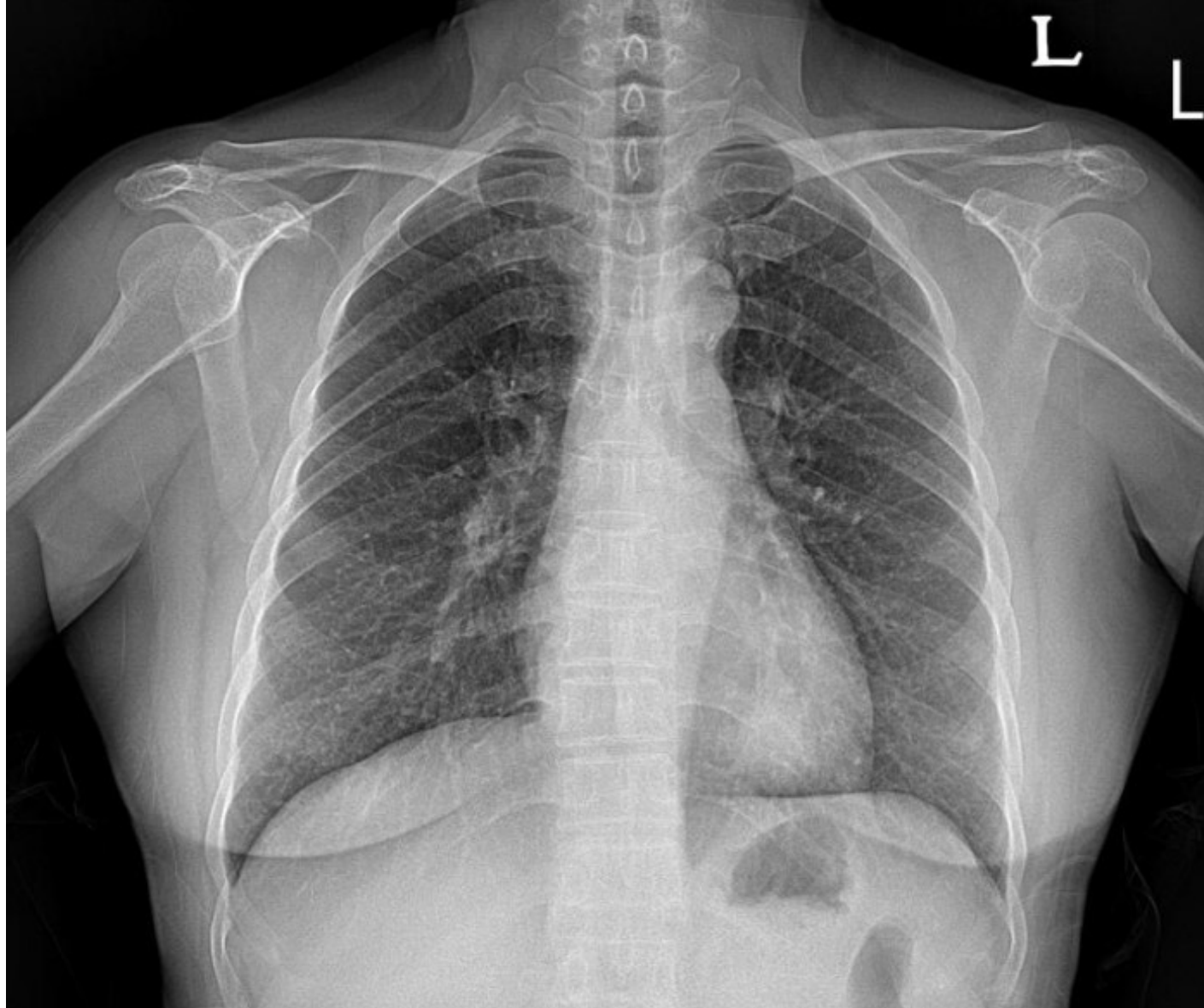
Fat pad

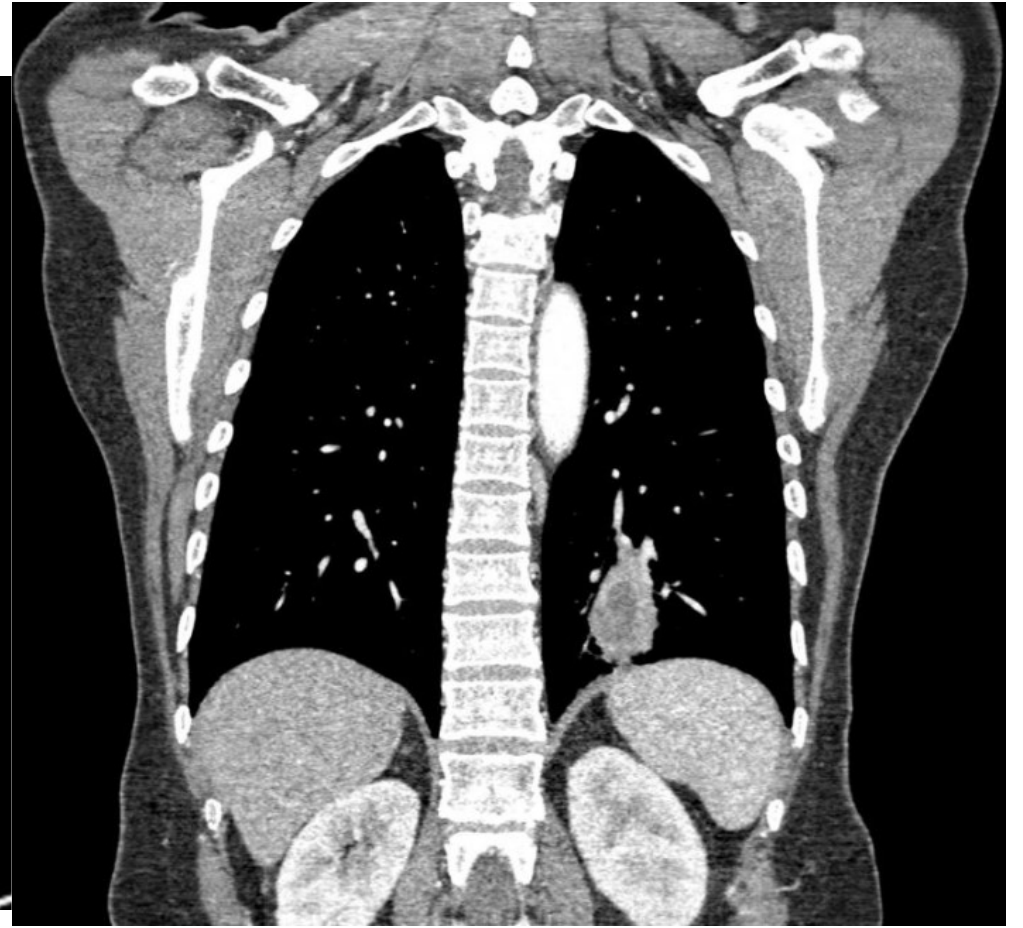
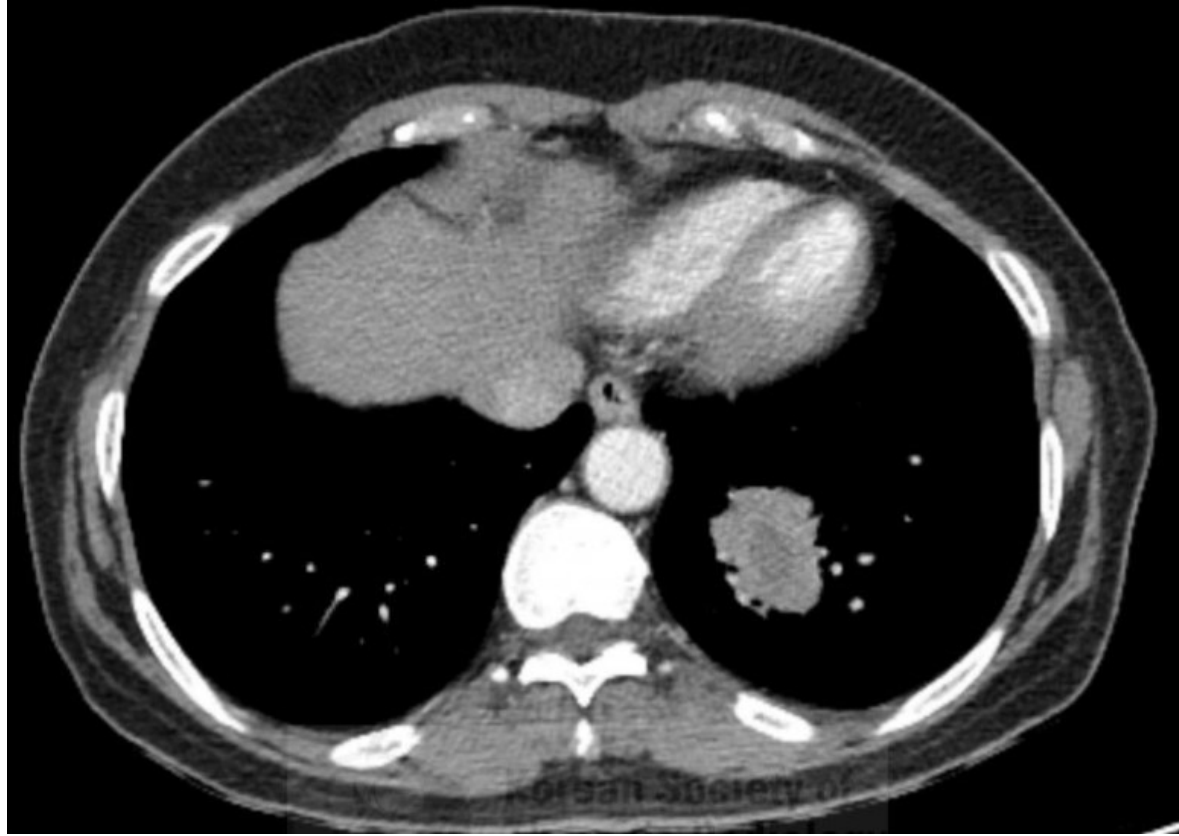

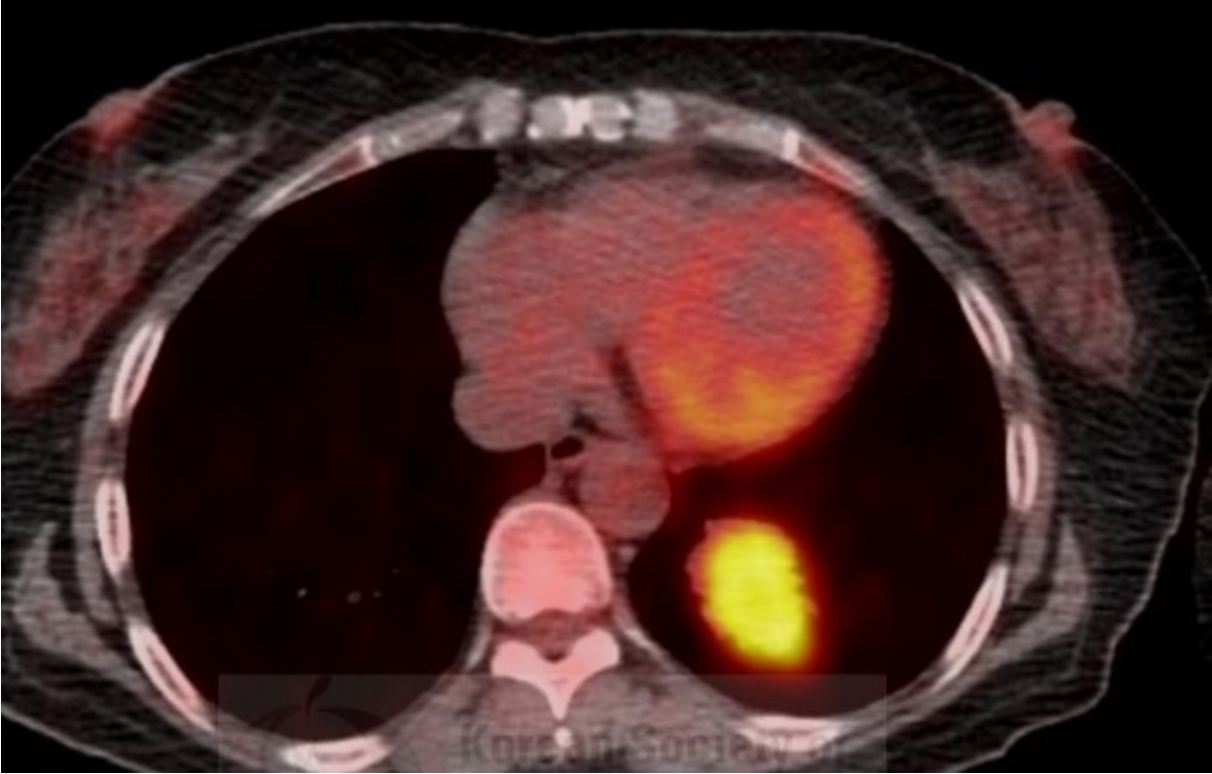


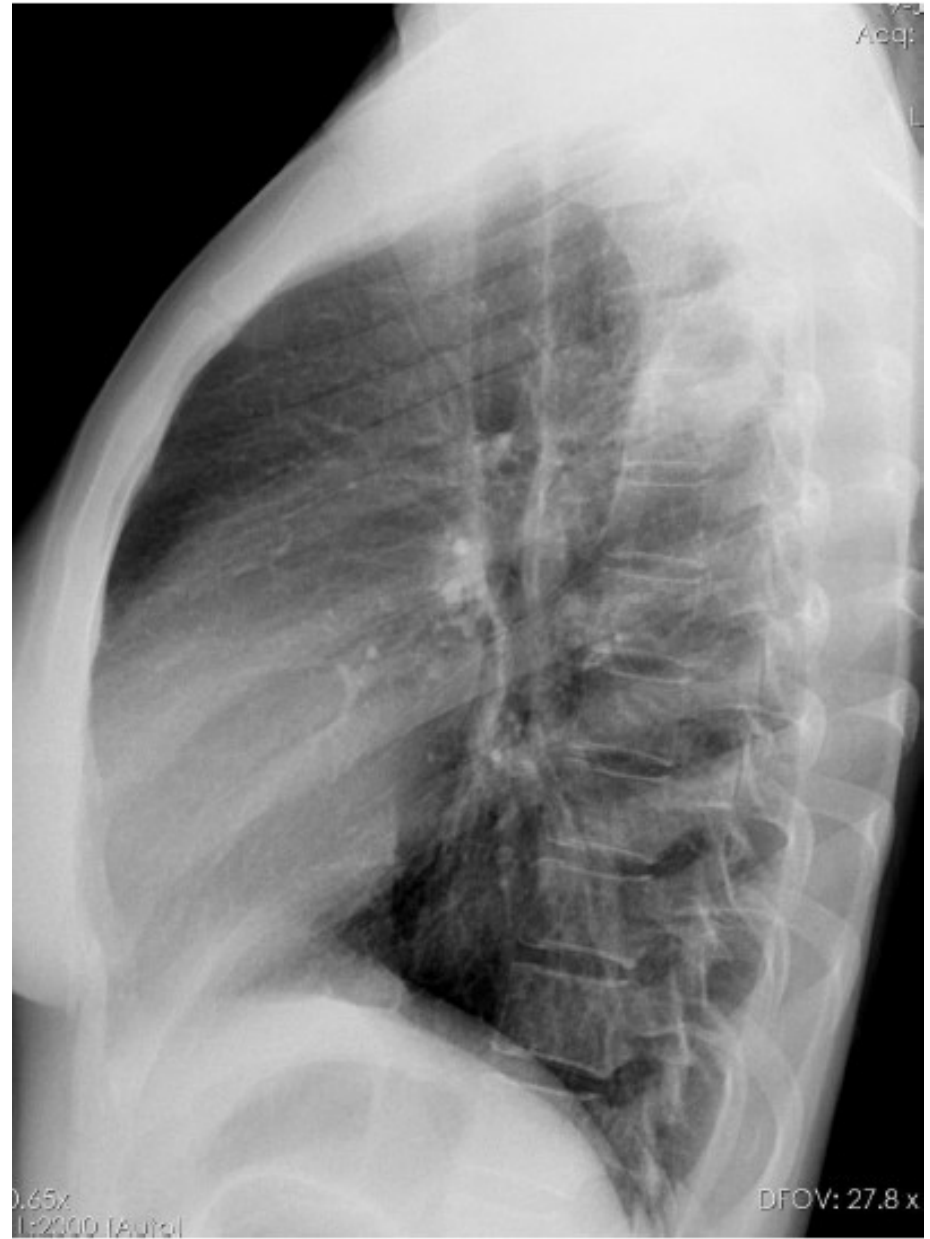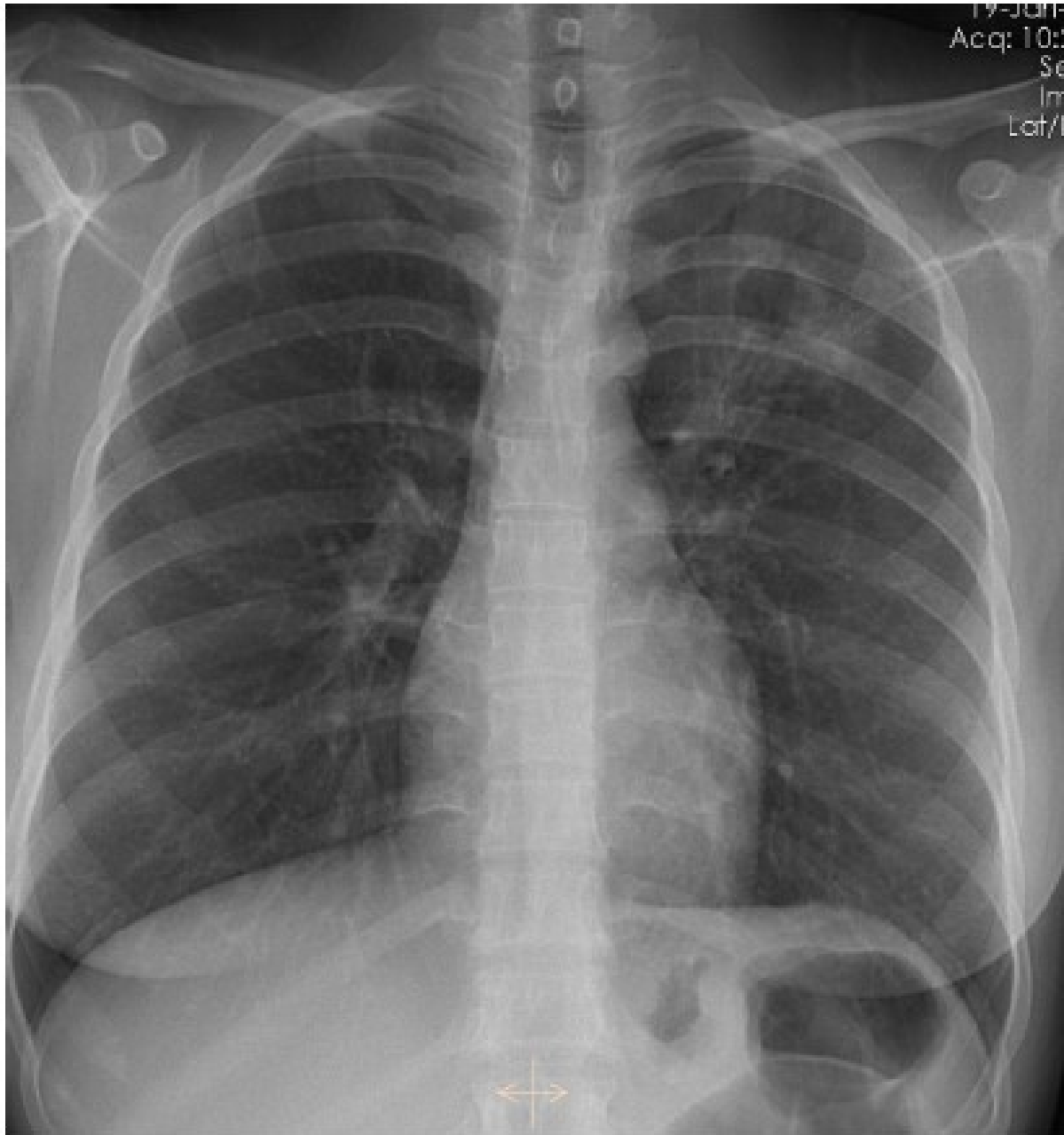


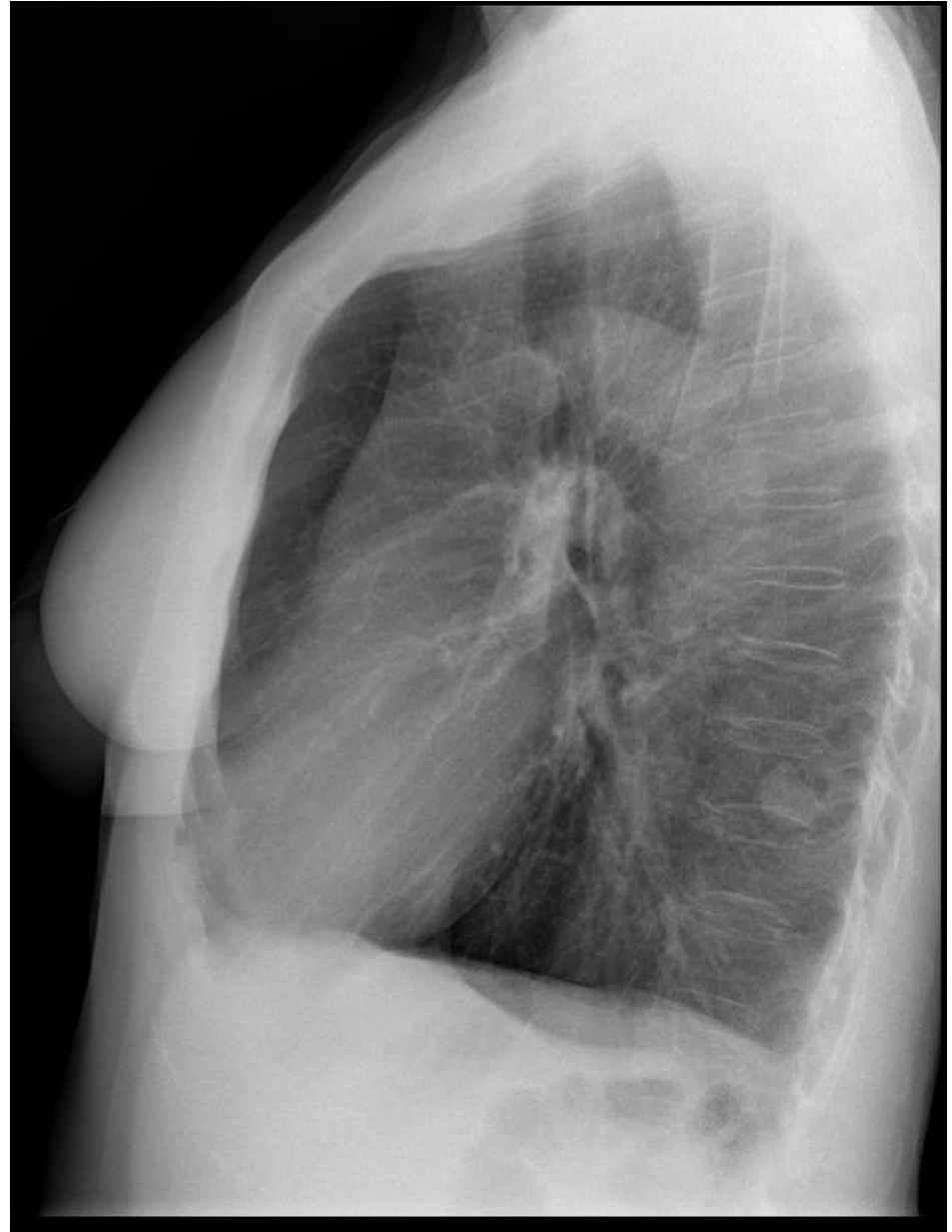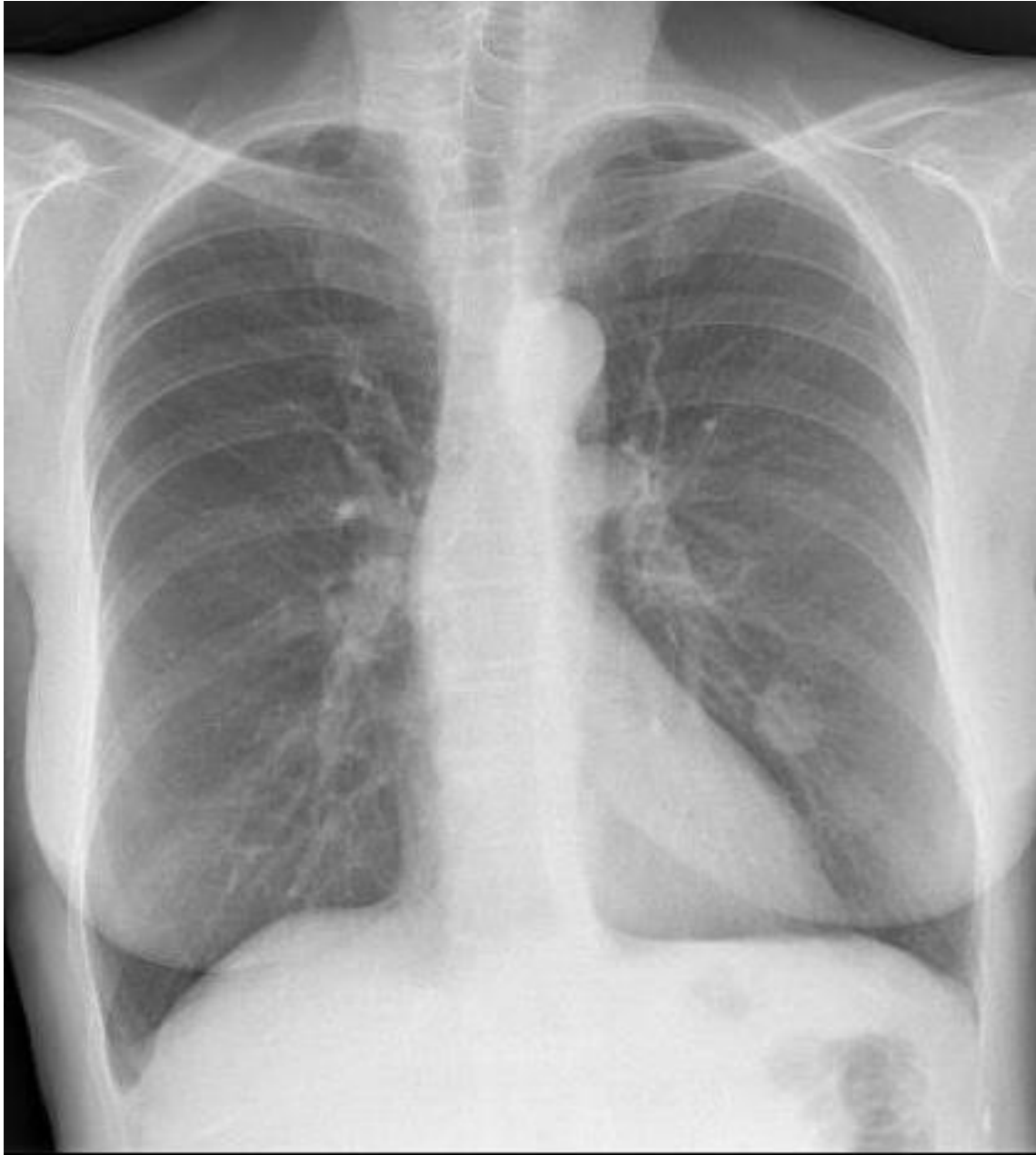61 Y. K..Öksürük 4 ay..Hemoptizi 1 ay.

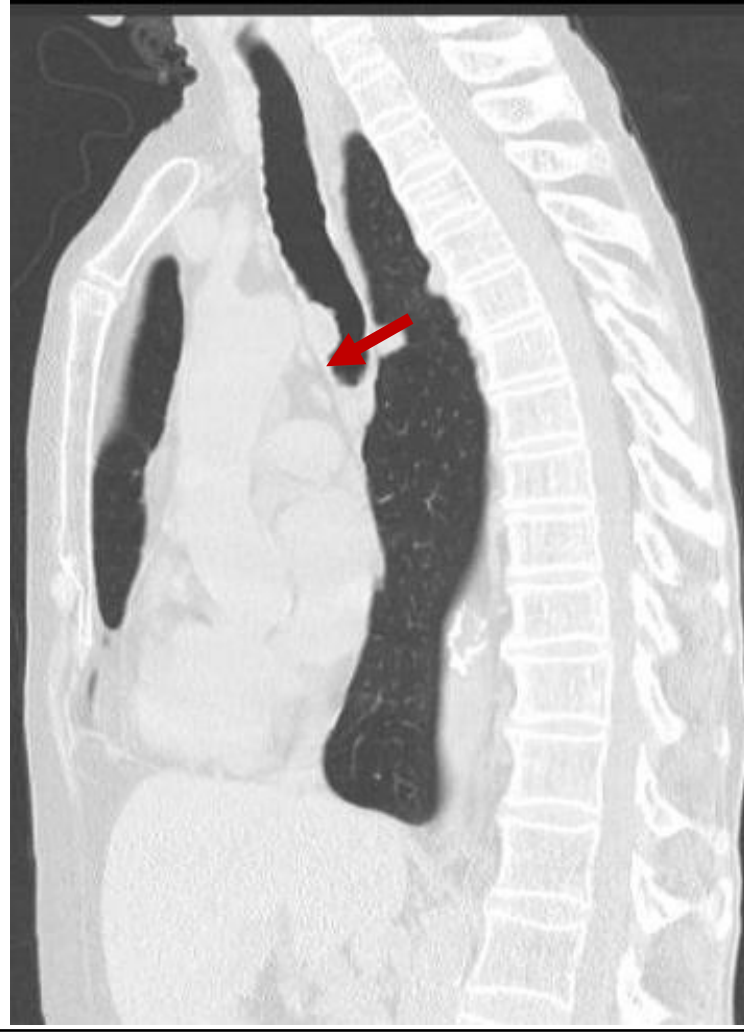
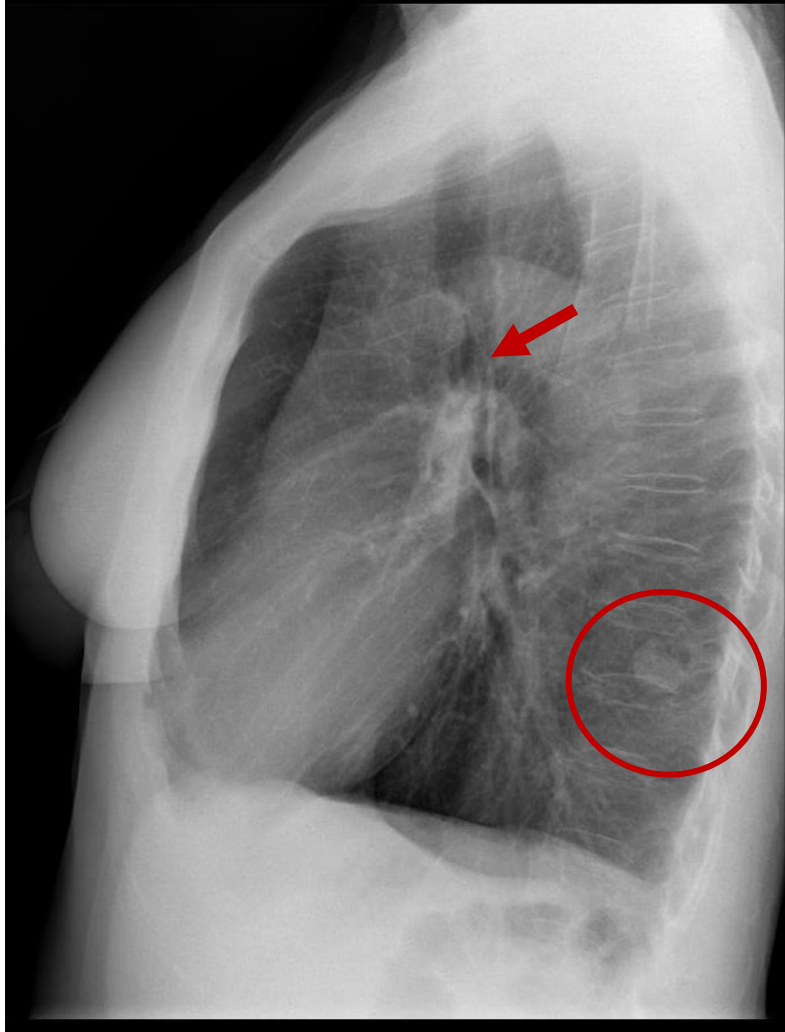


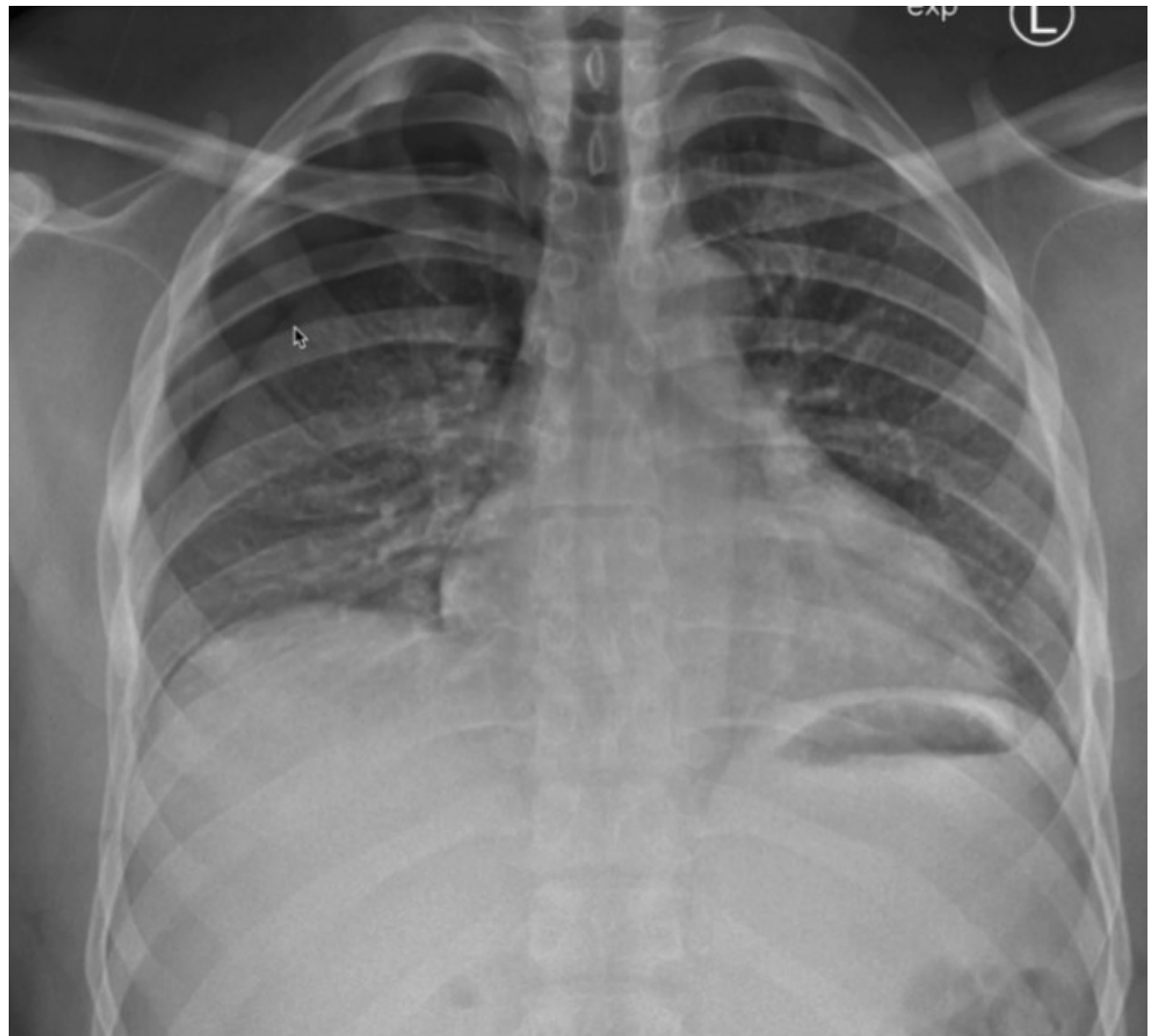
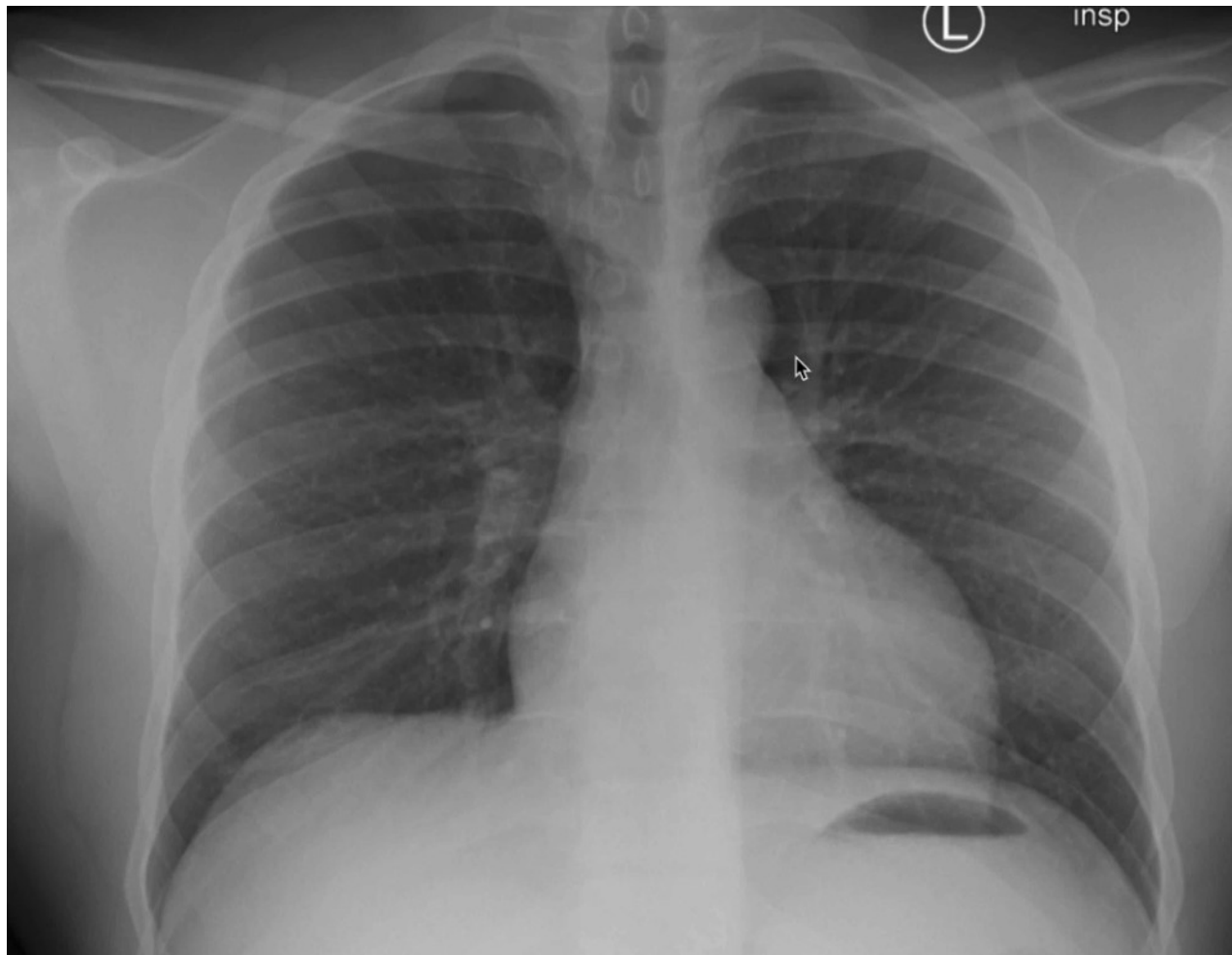


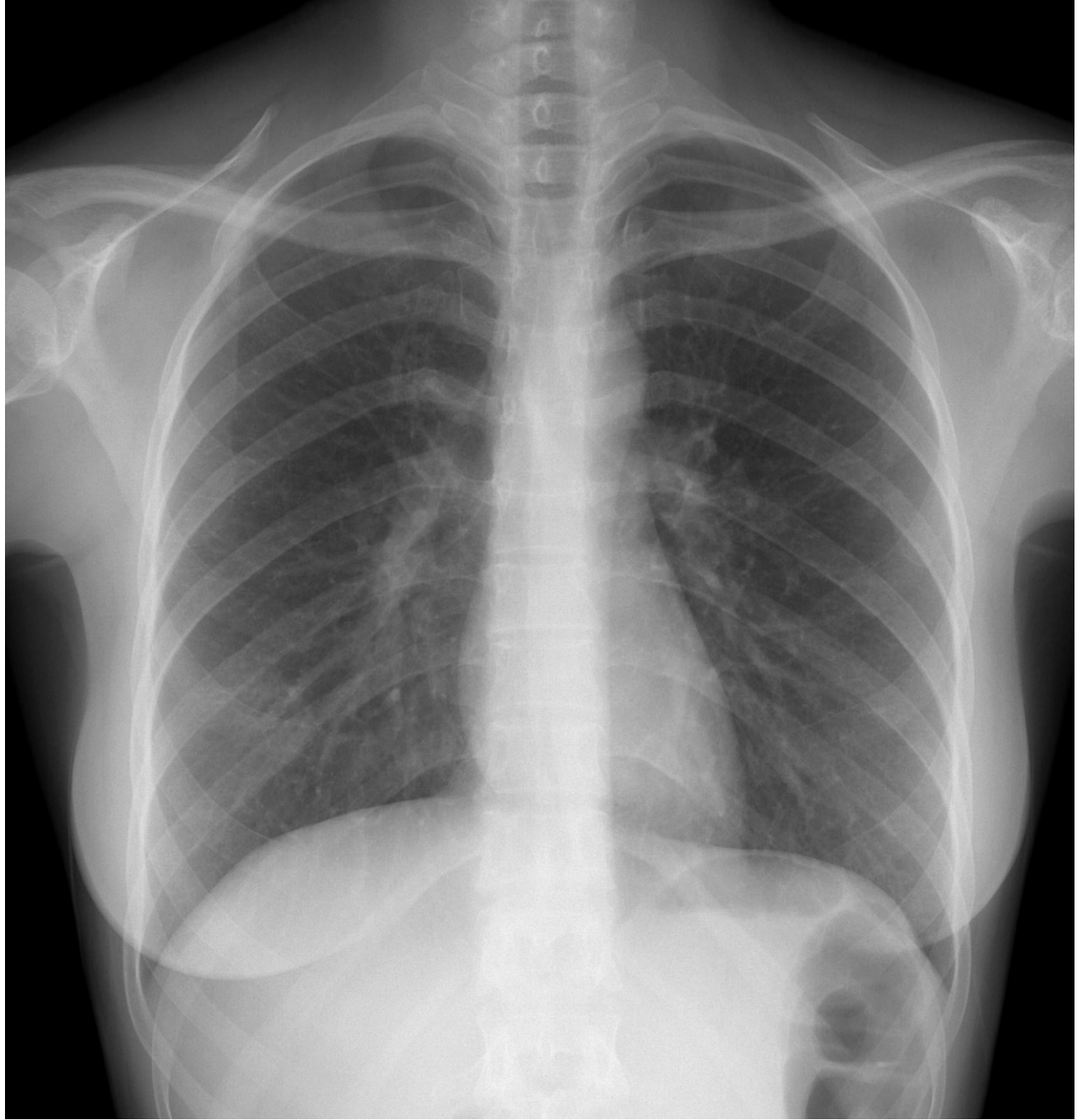




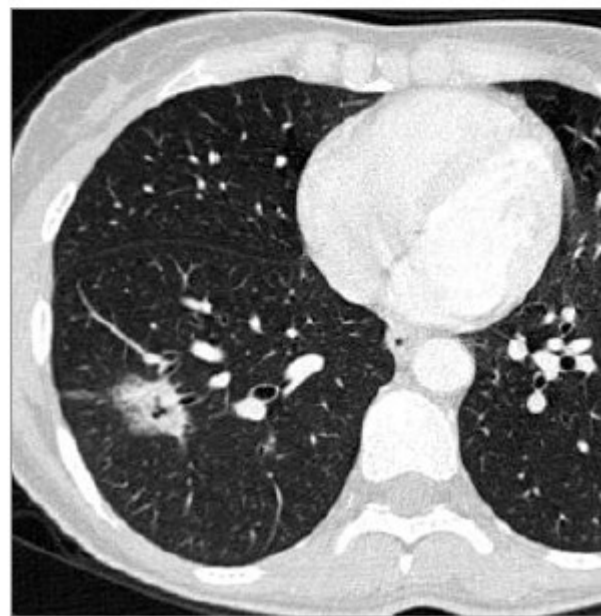
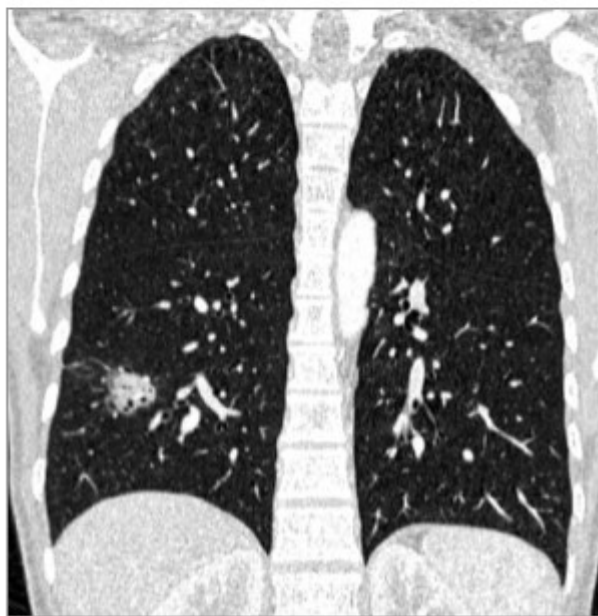
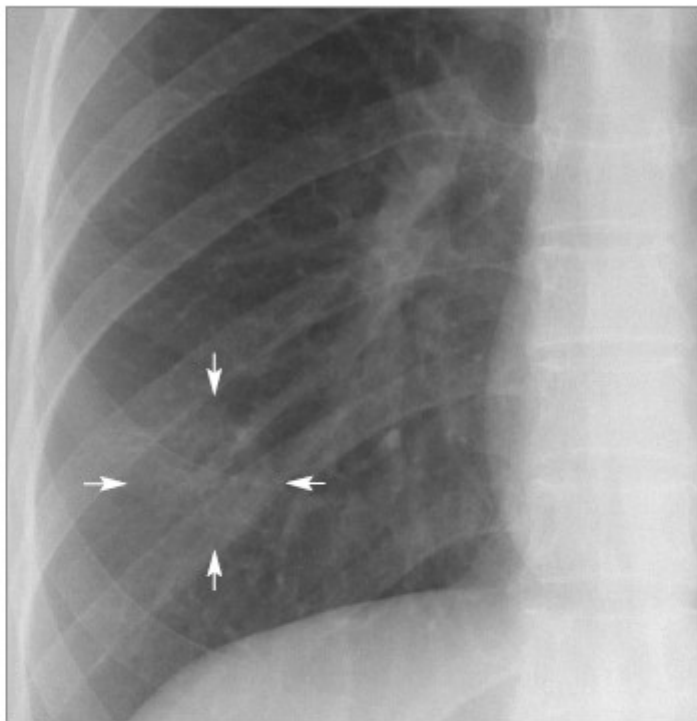








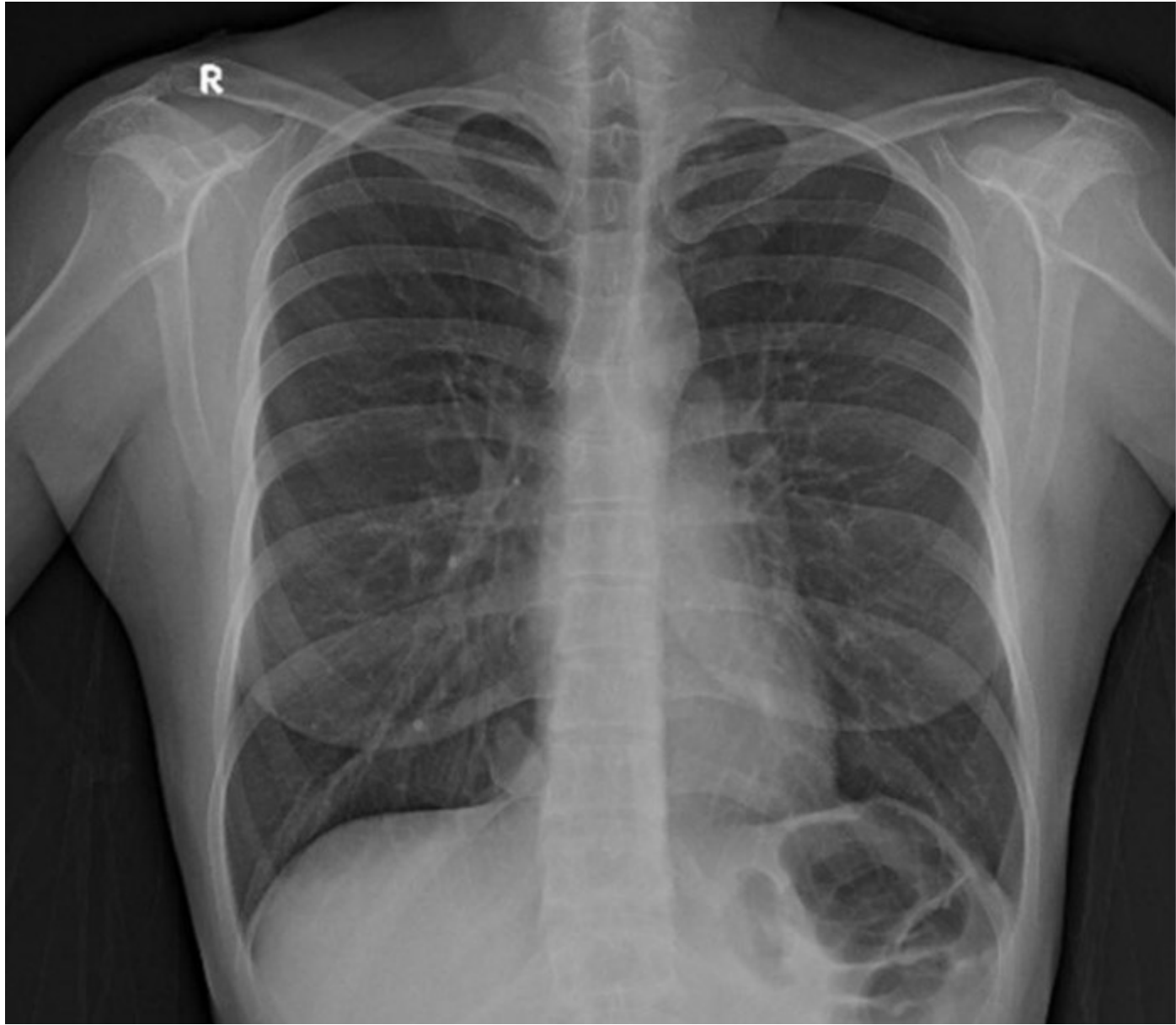


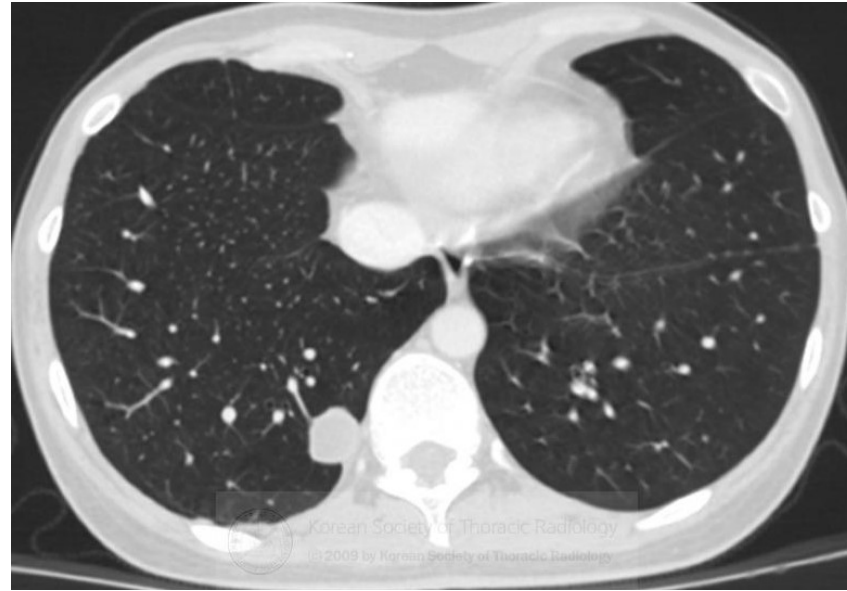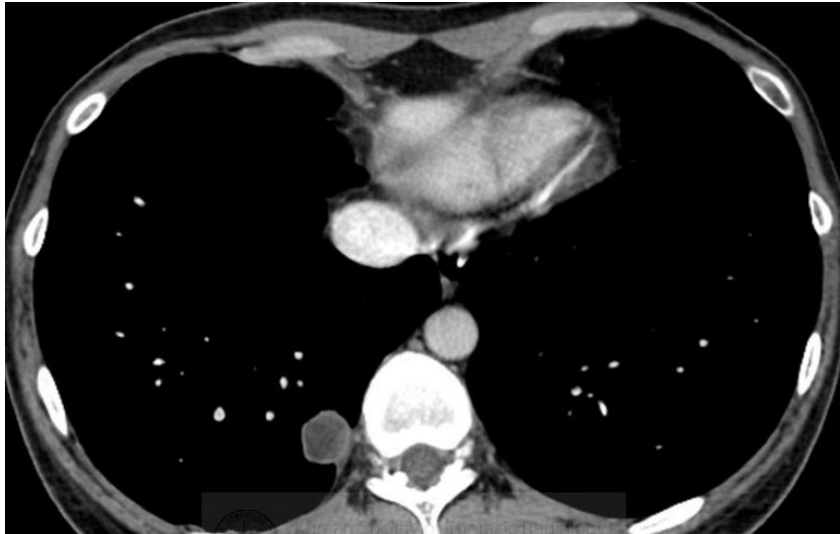


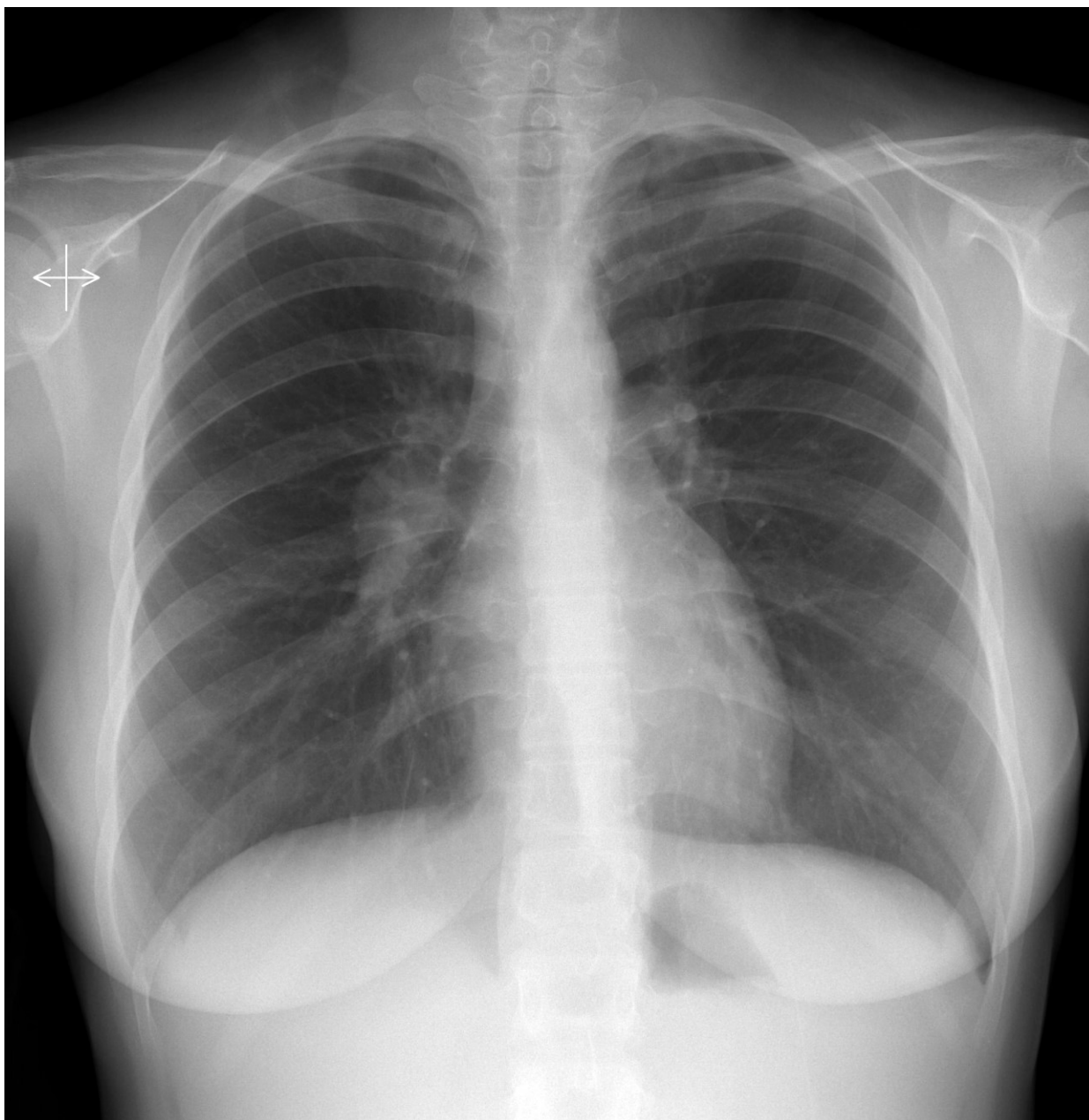37 yaşında F hasta

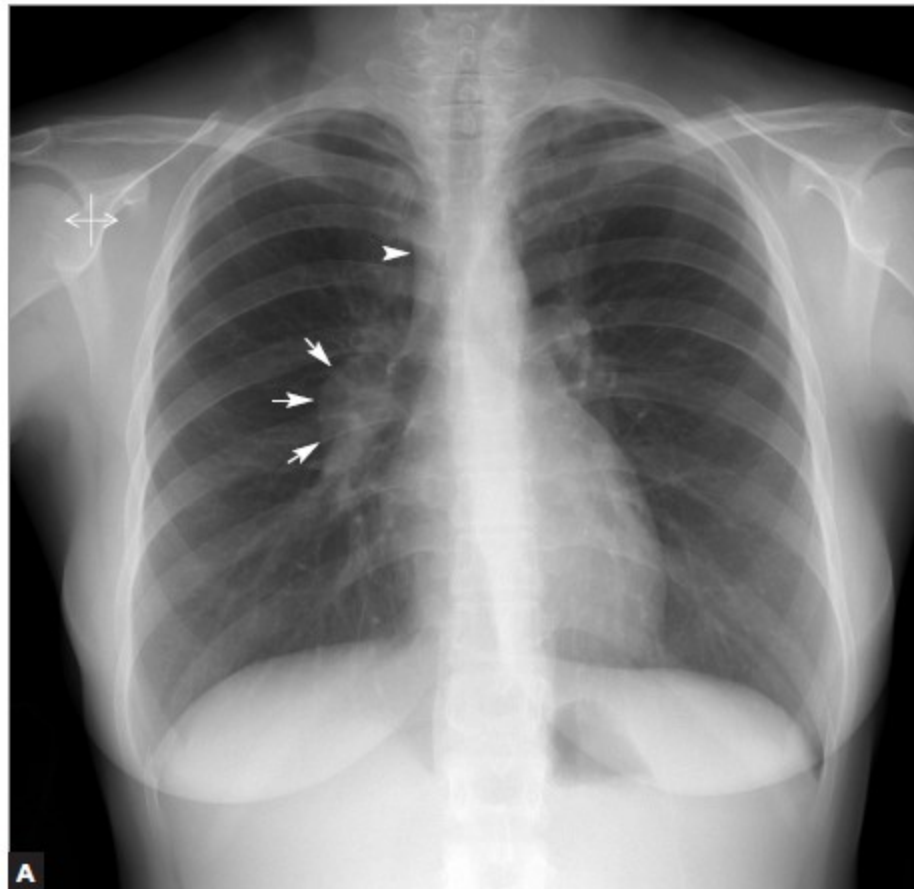
37 yaşımda F hasta akciğer grafisindeki patoloji nedeniyle deęerlendirildi.Tanı?

- A. Nörojenik kist
- B. Kistik schwannom
- C. Kist Hidatik
- D. Bronkojenik kist
- E. Pevral Malign Mezotelyoma

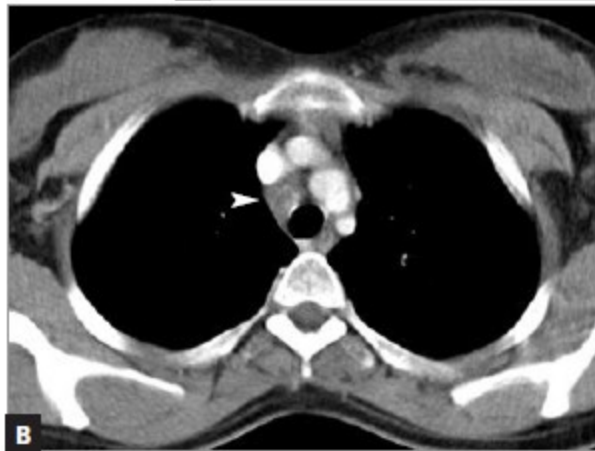




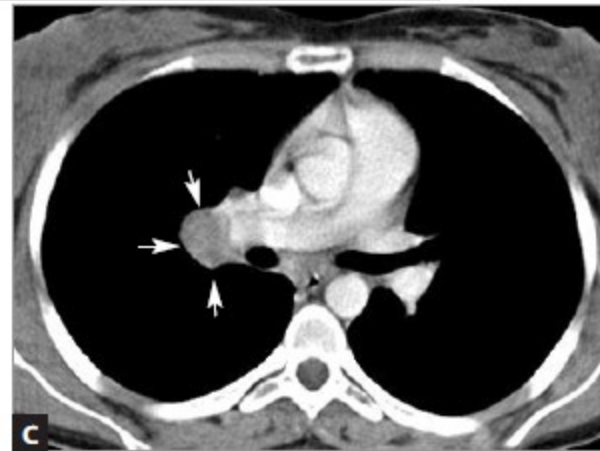




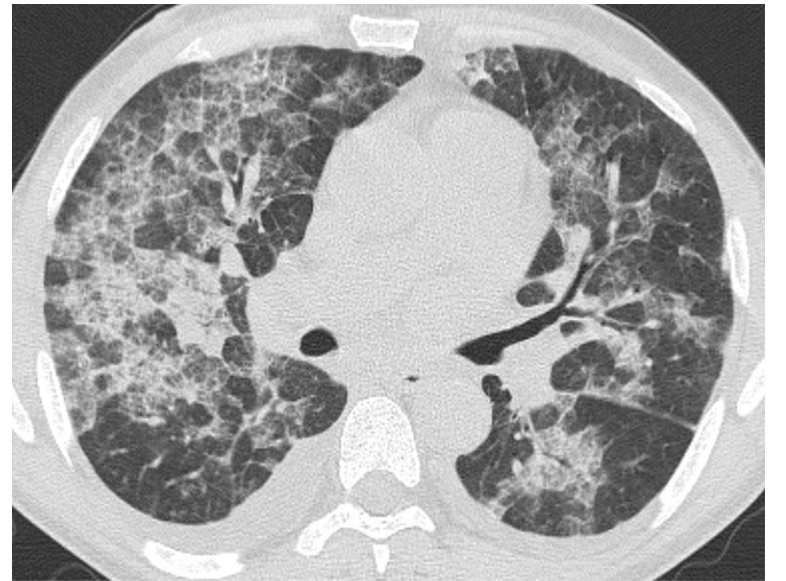
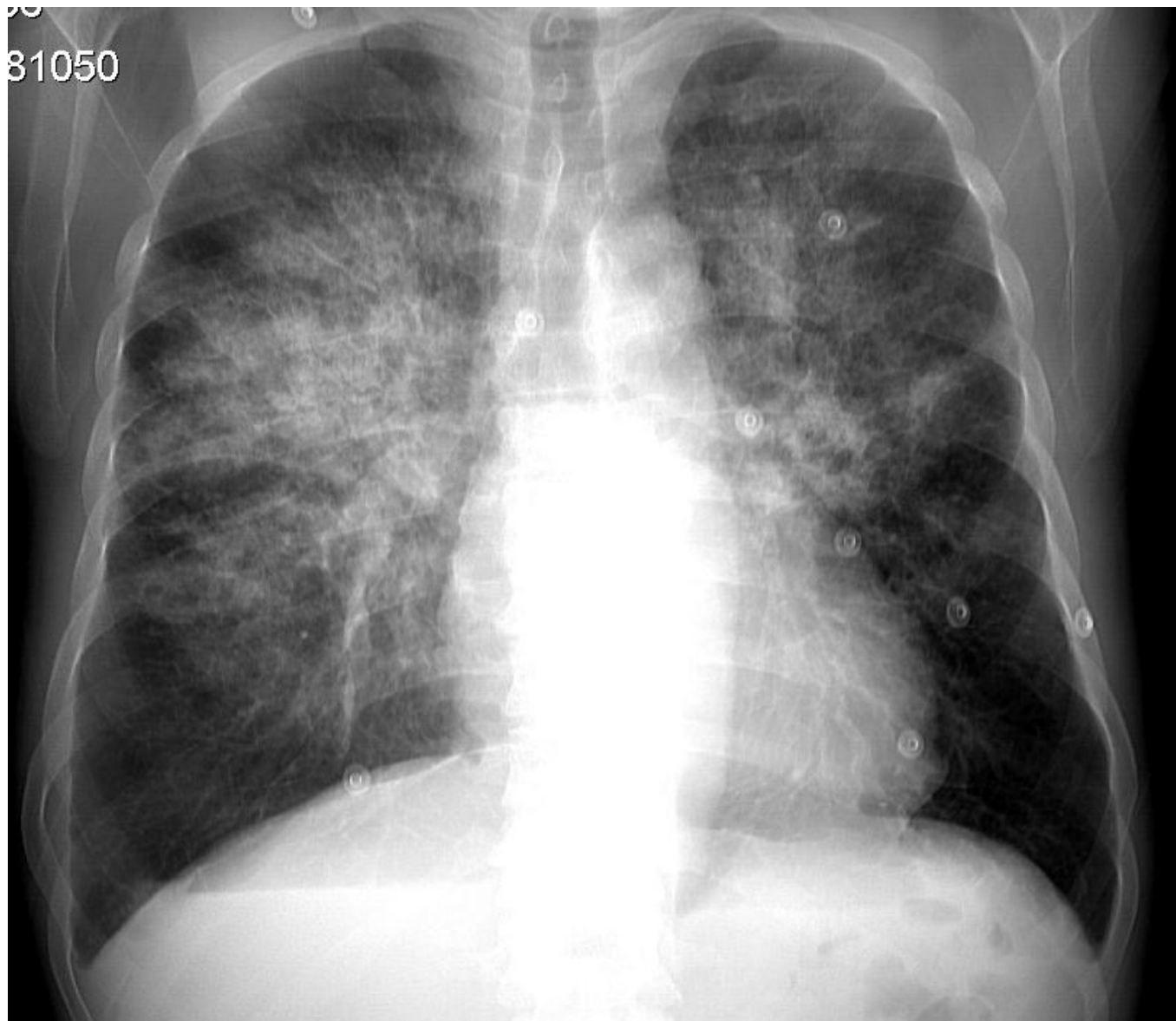
A



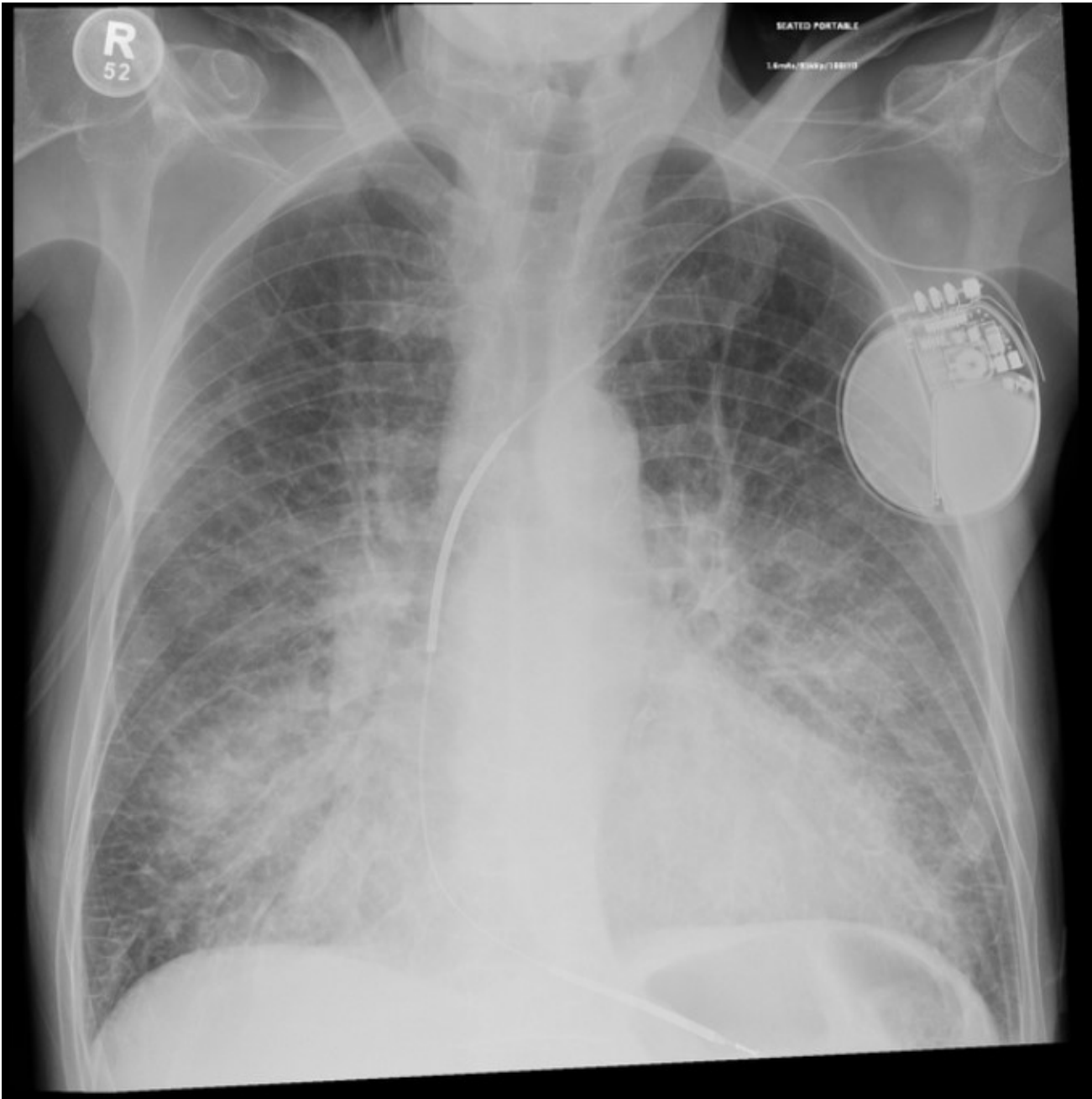
B

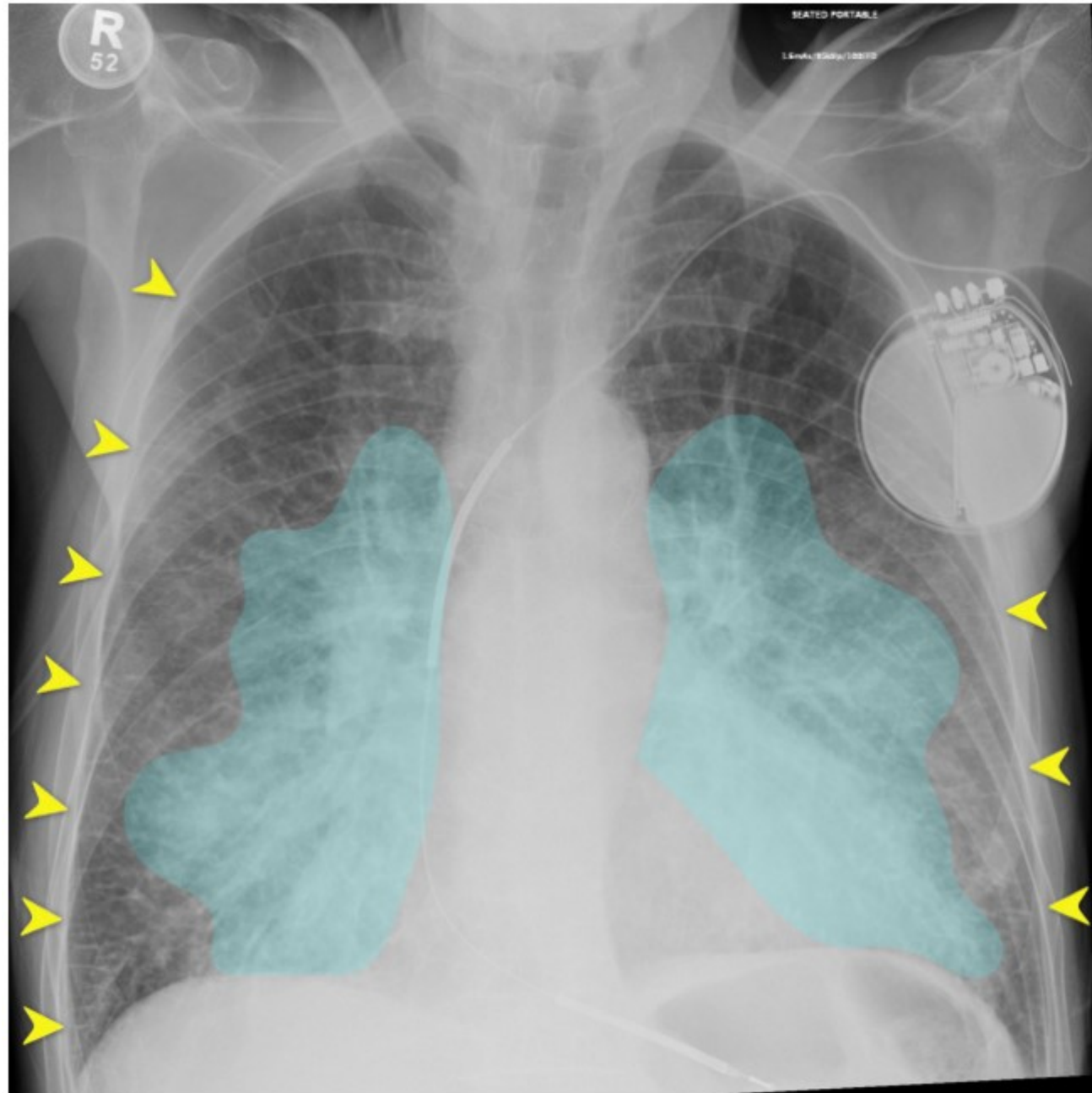


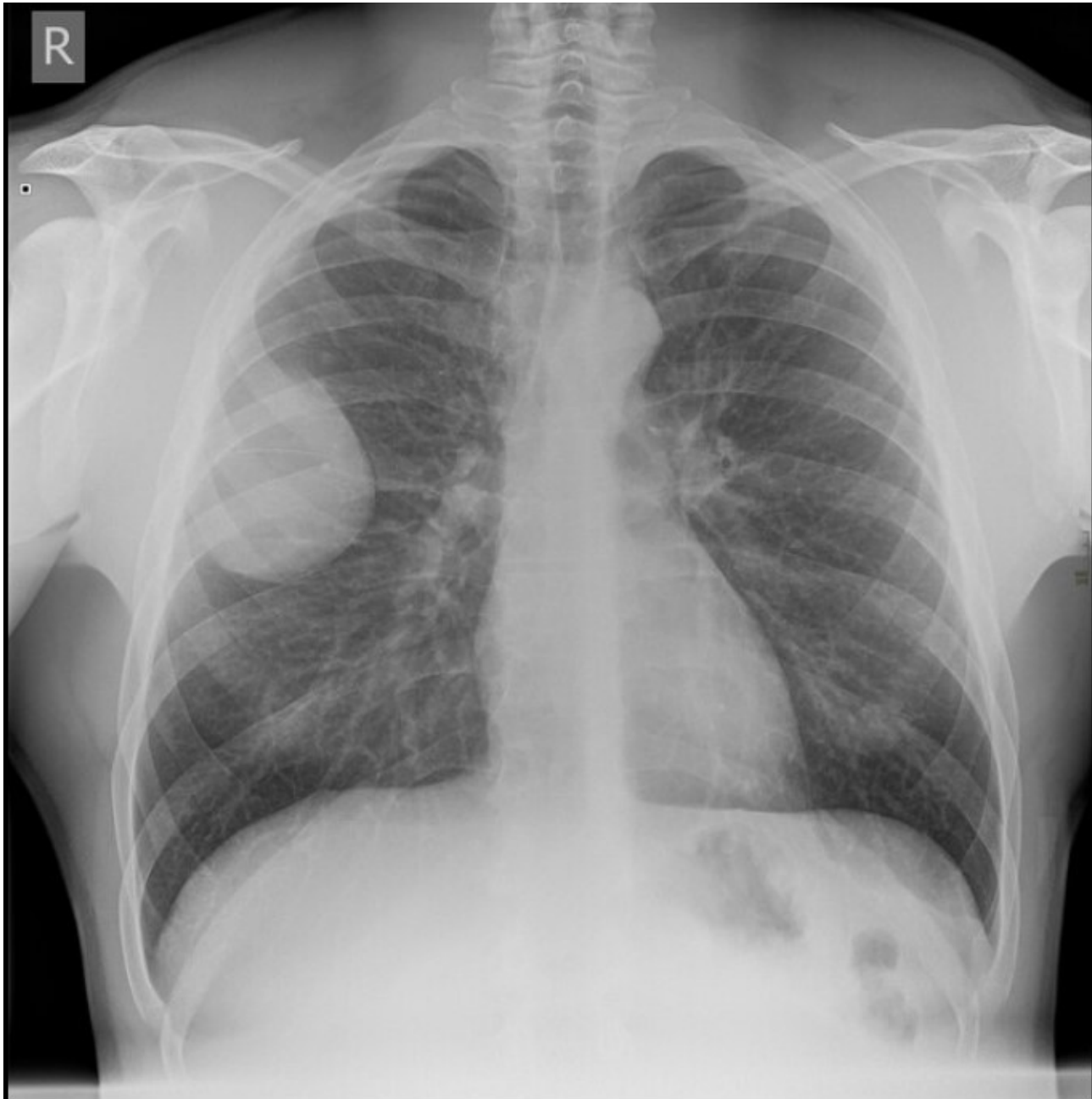
C

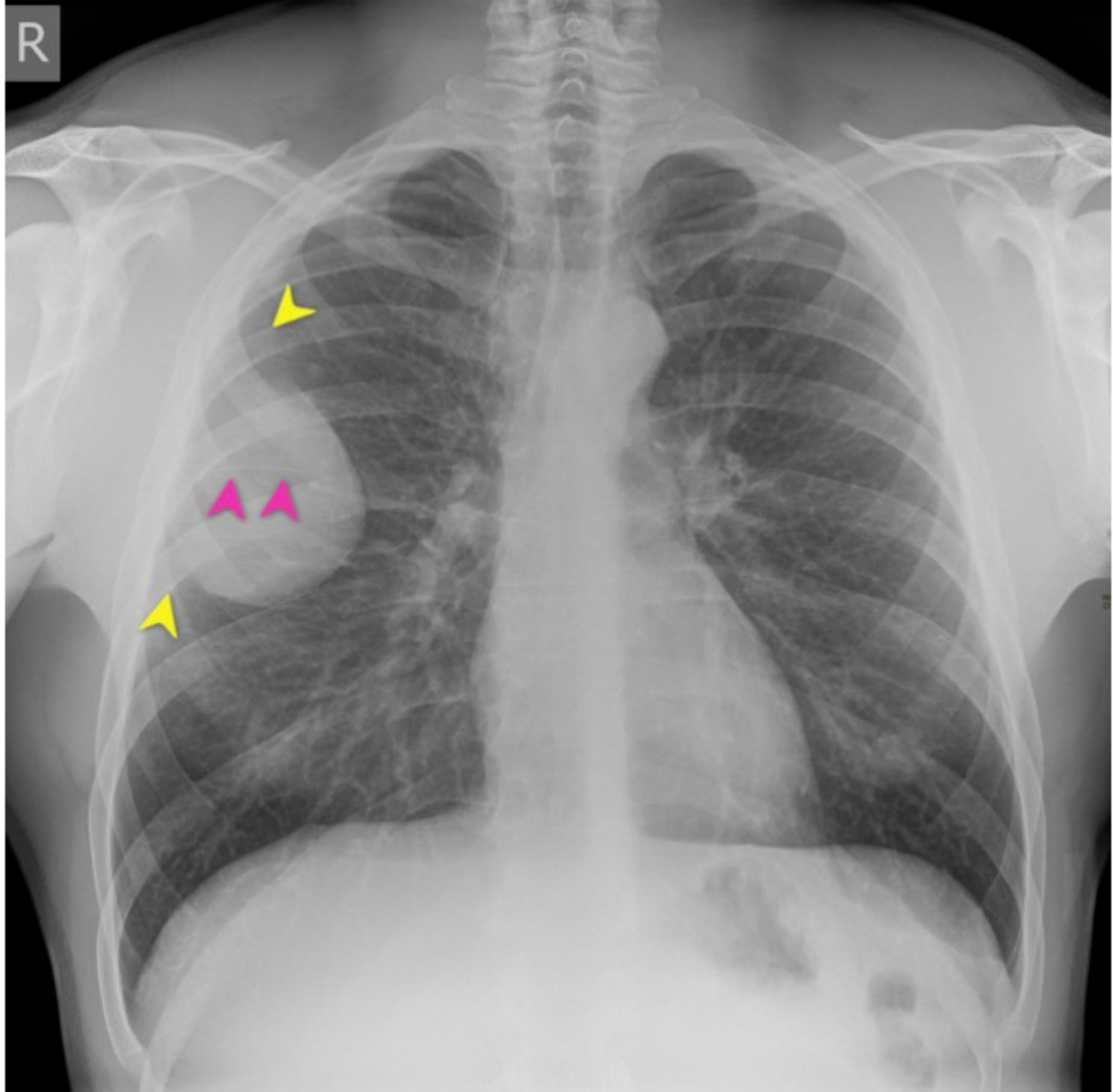


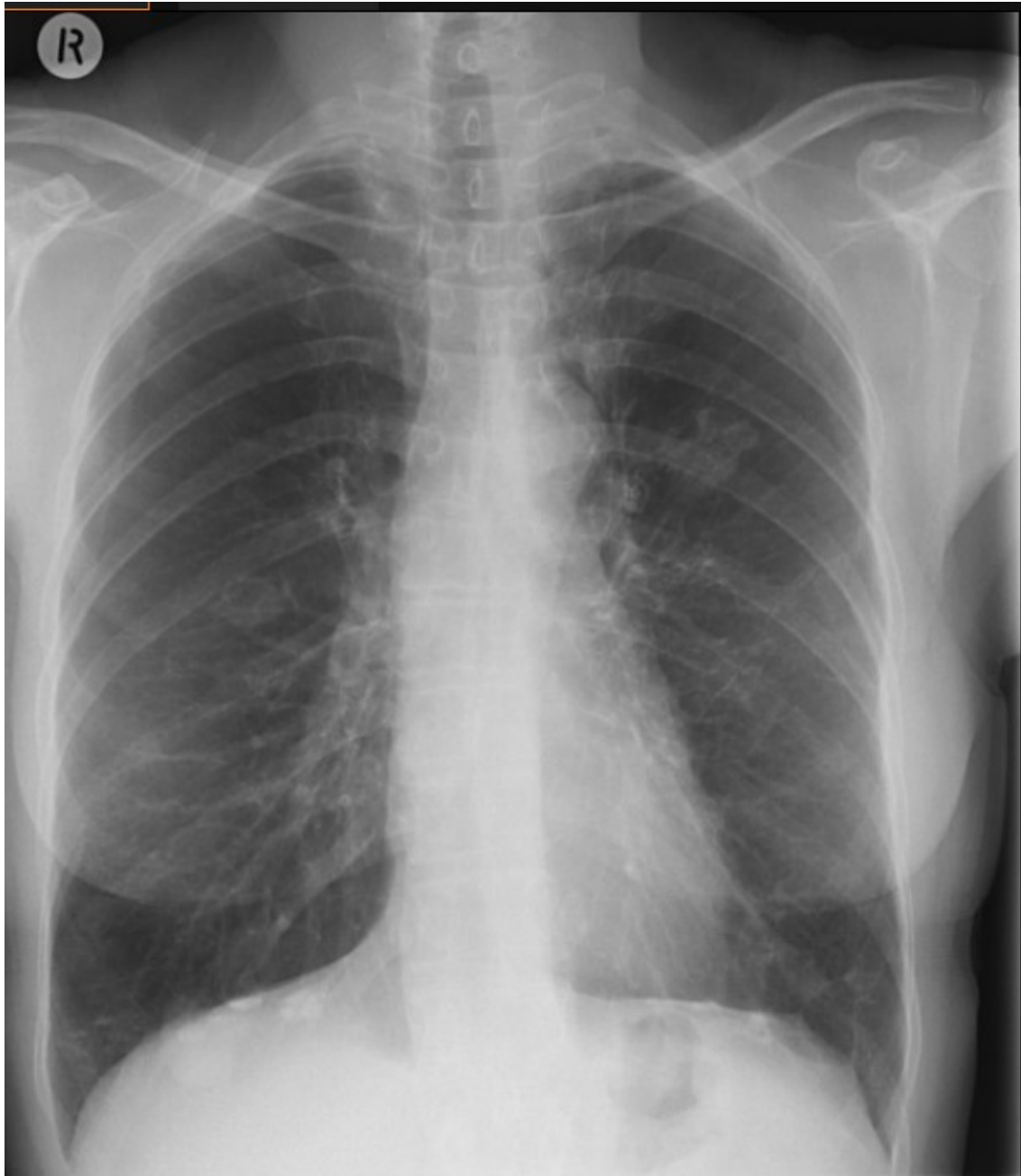


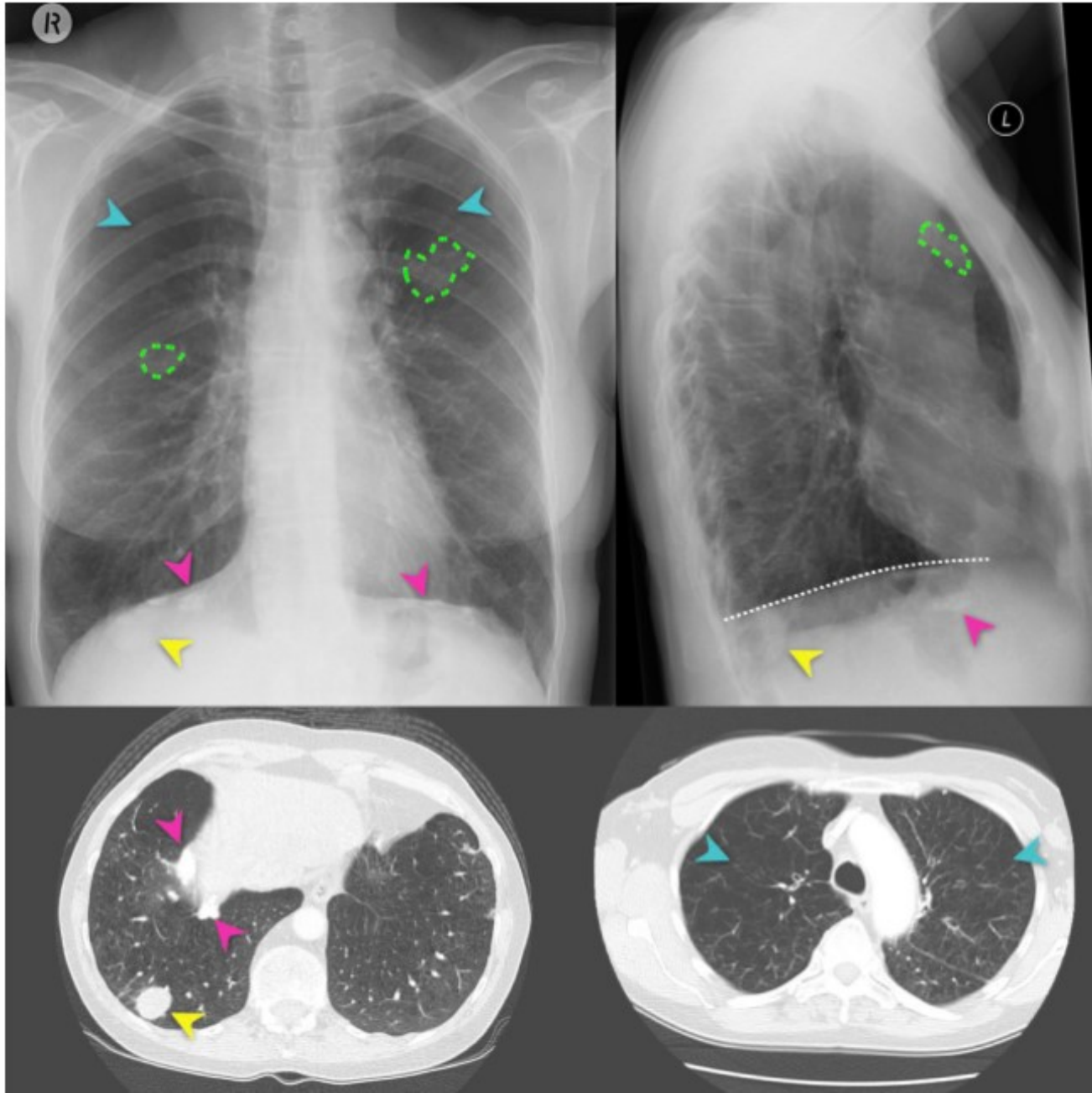


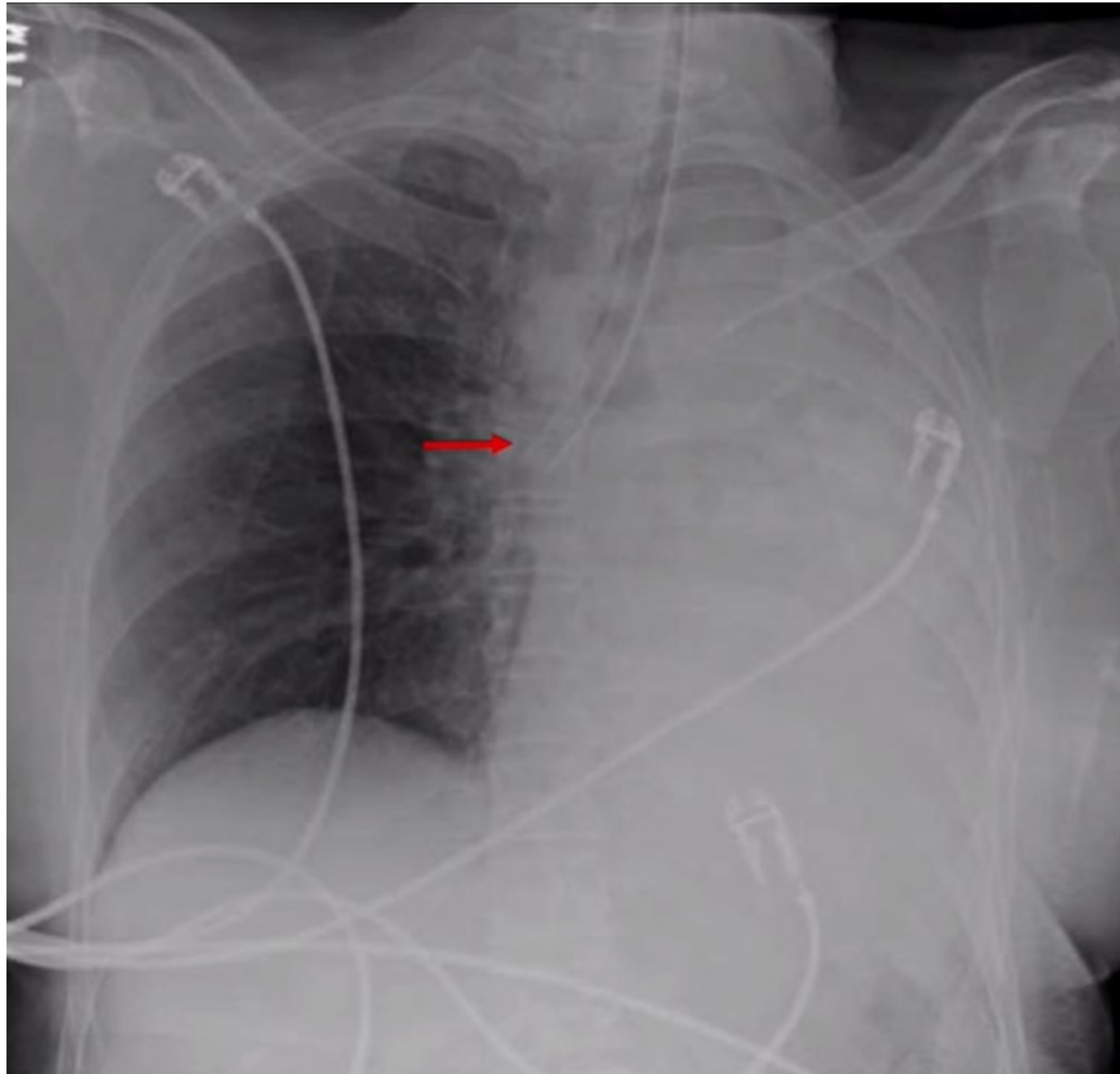


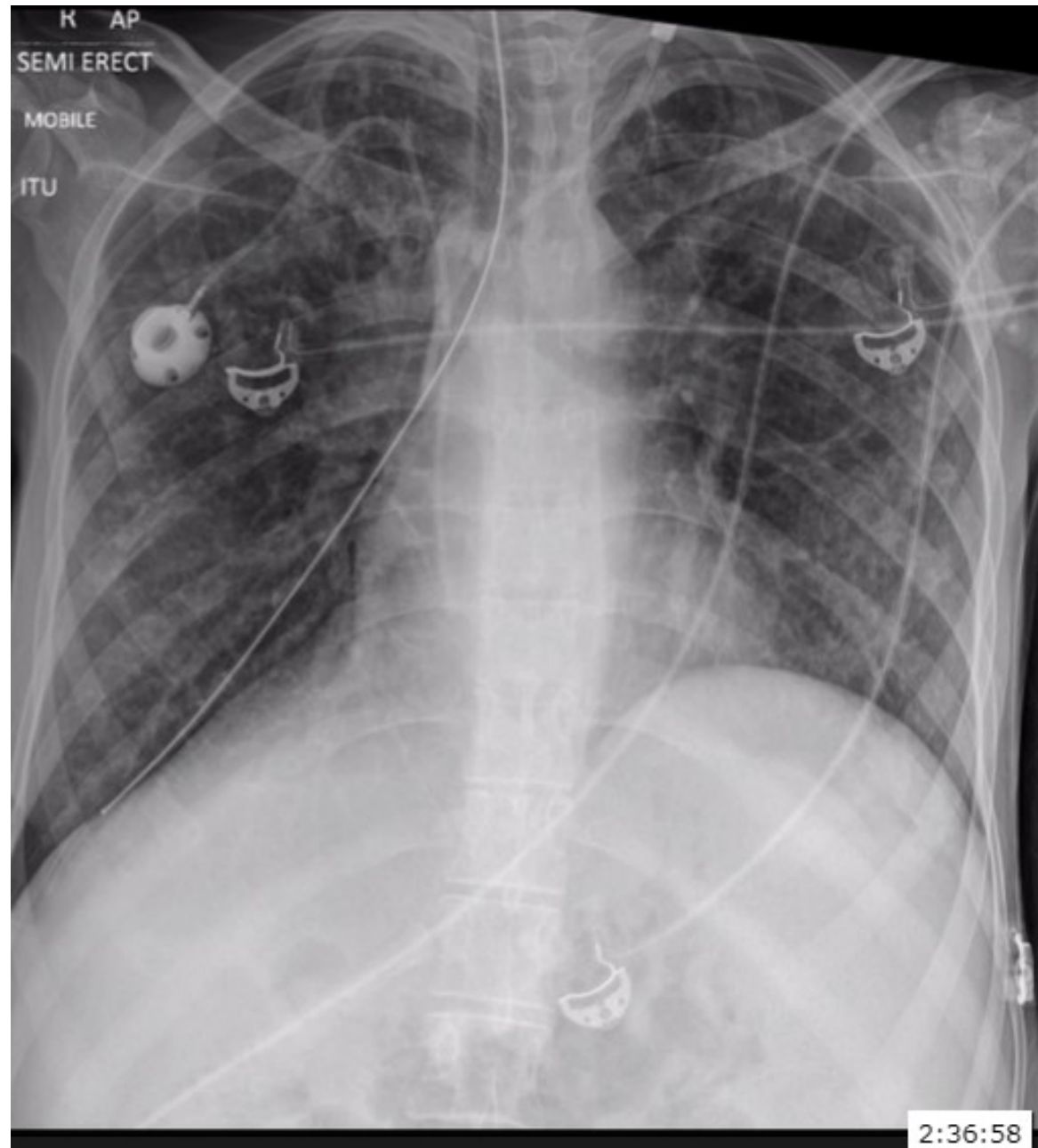



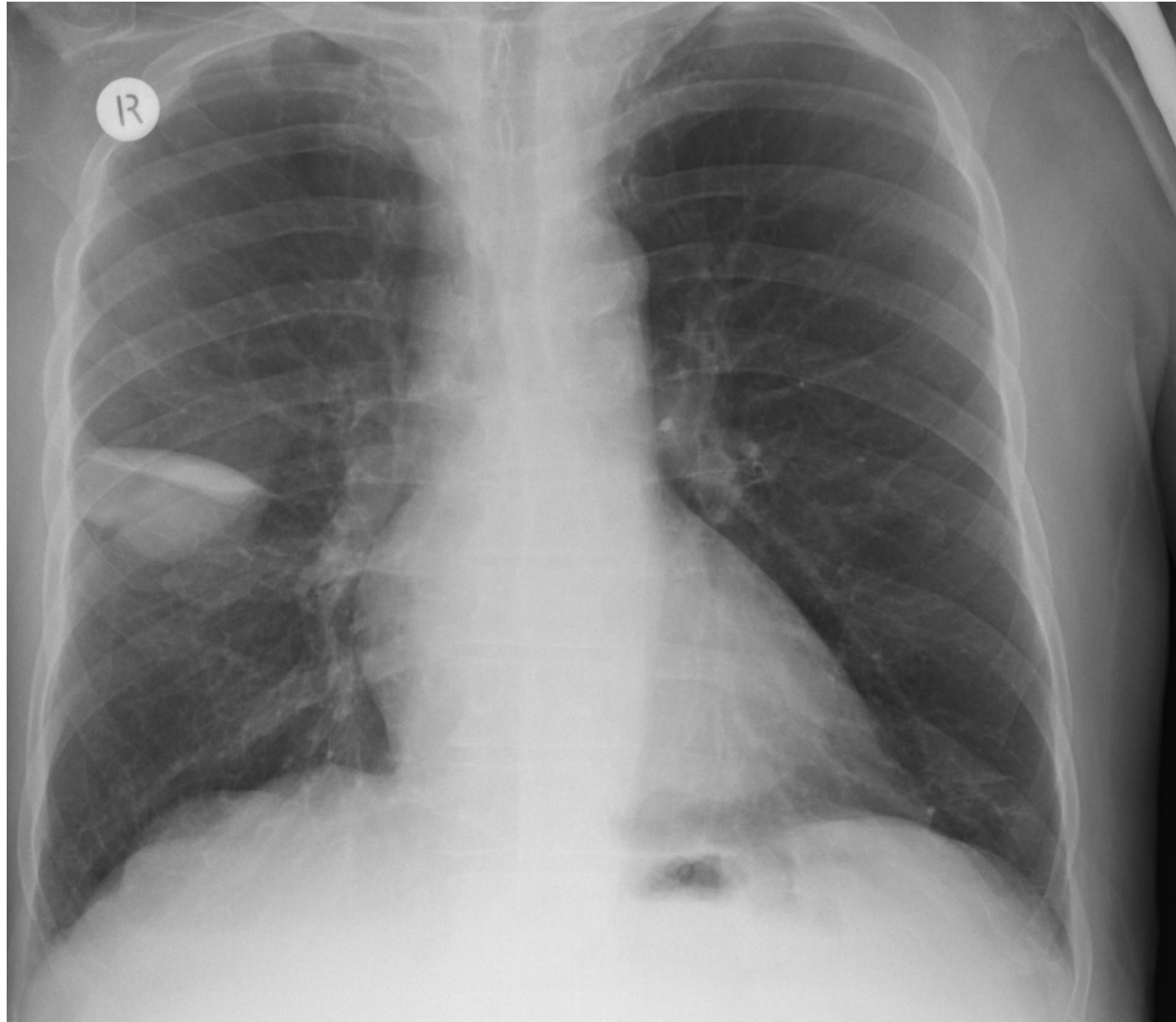


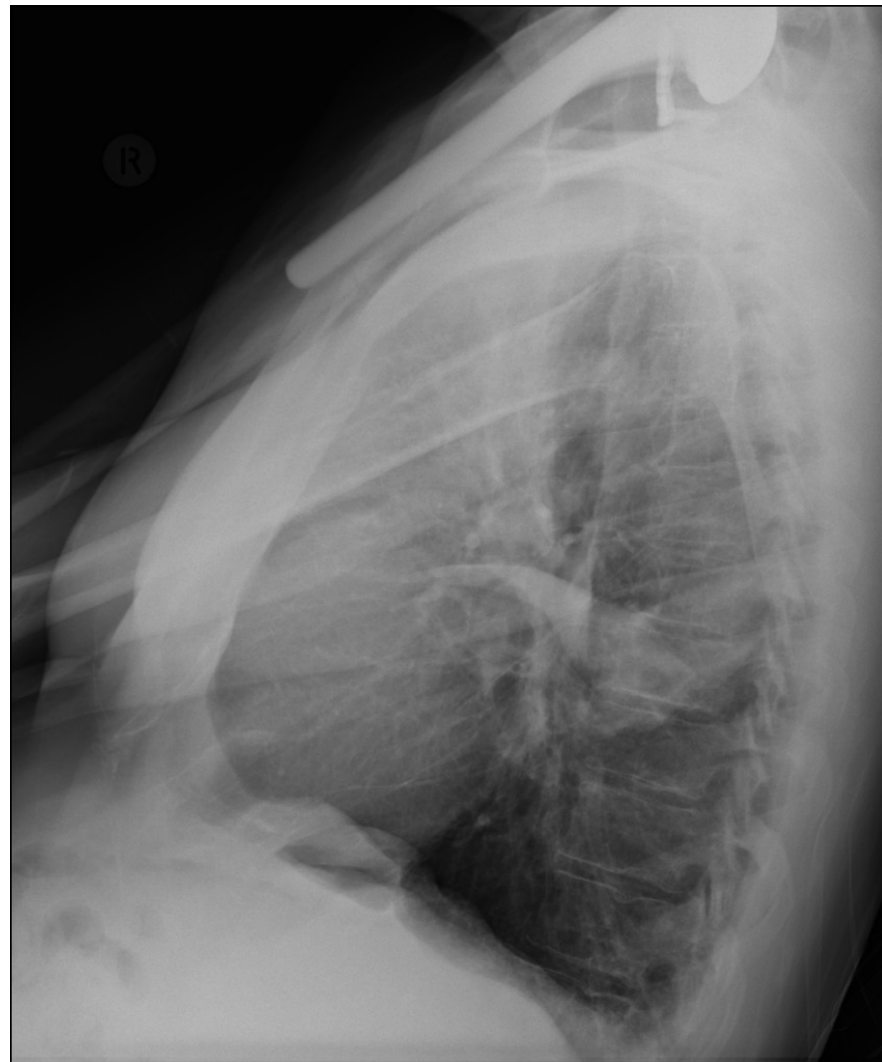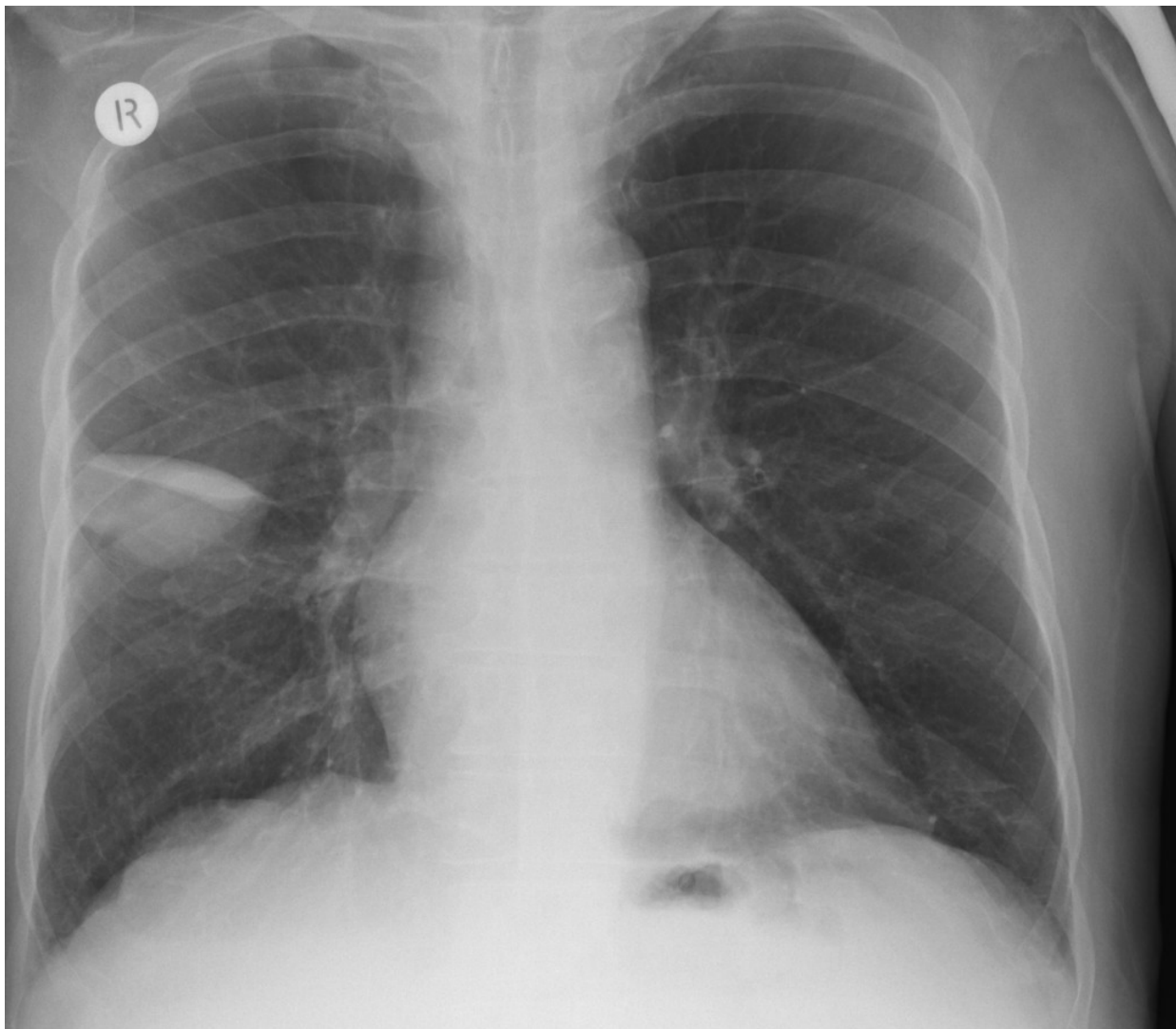


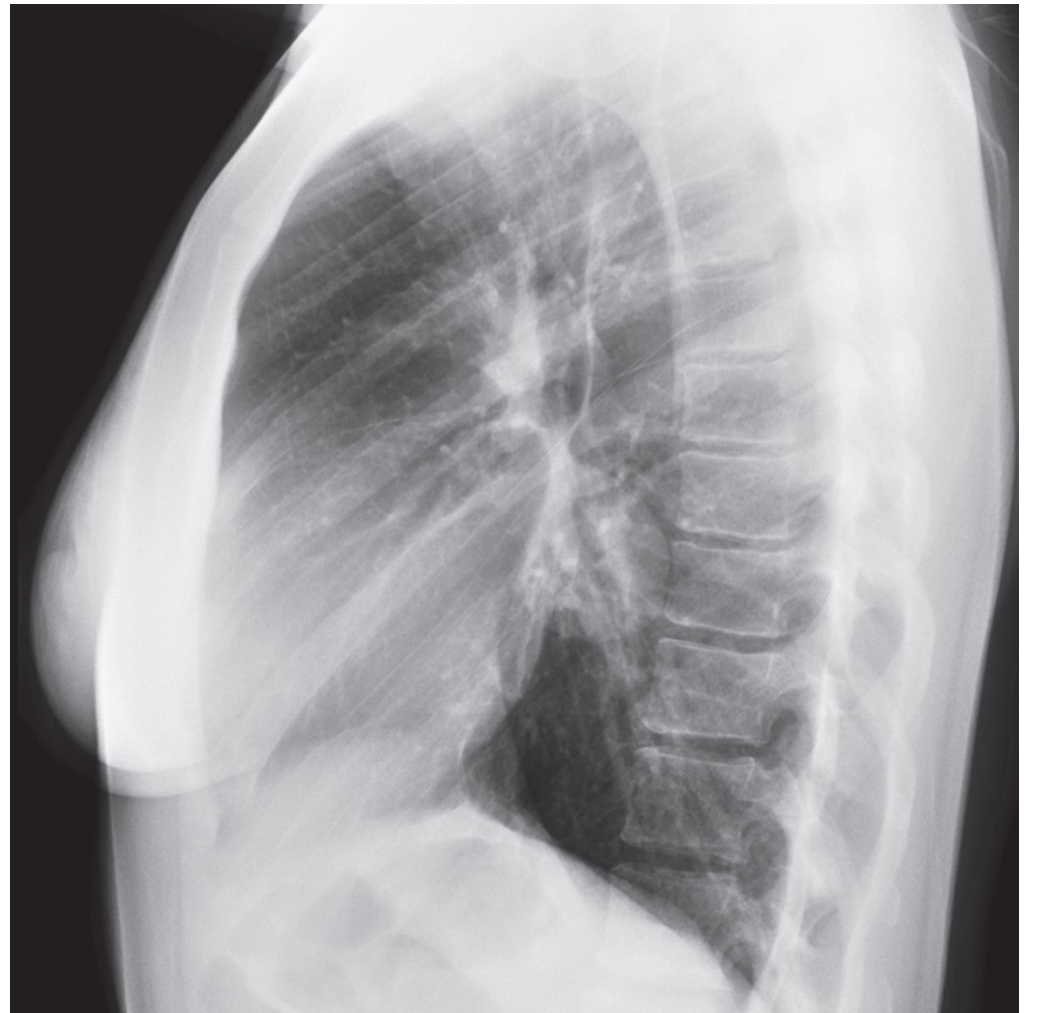
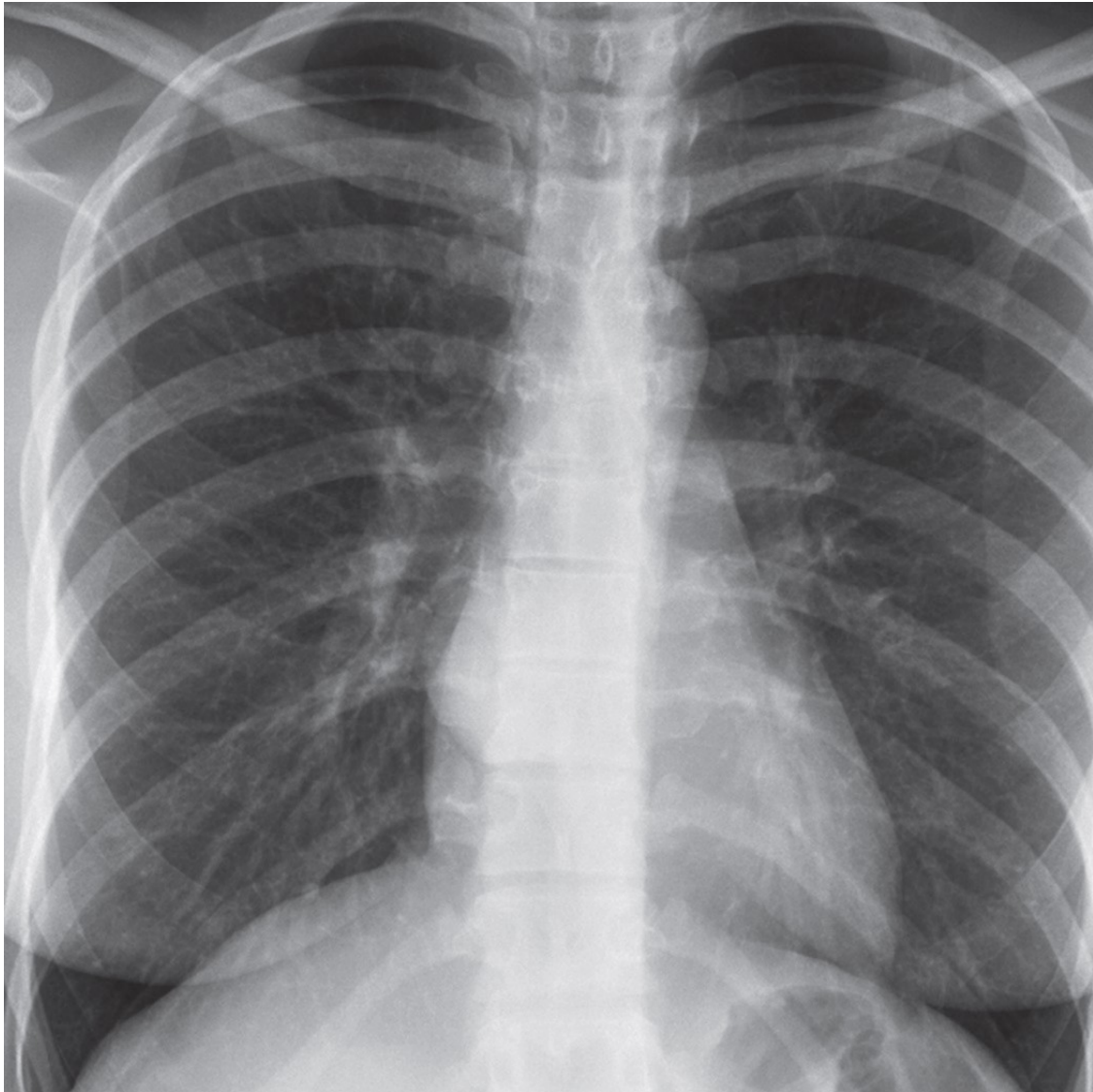


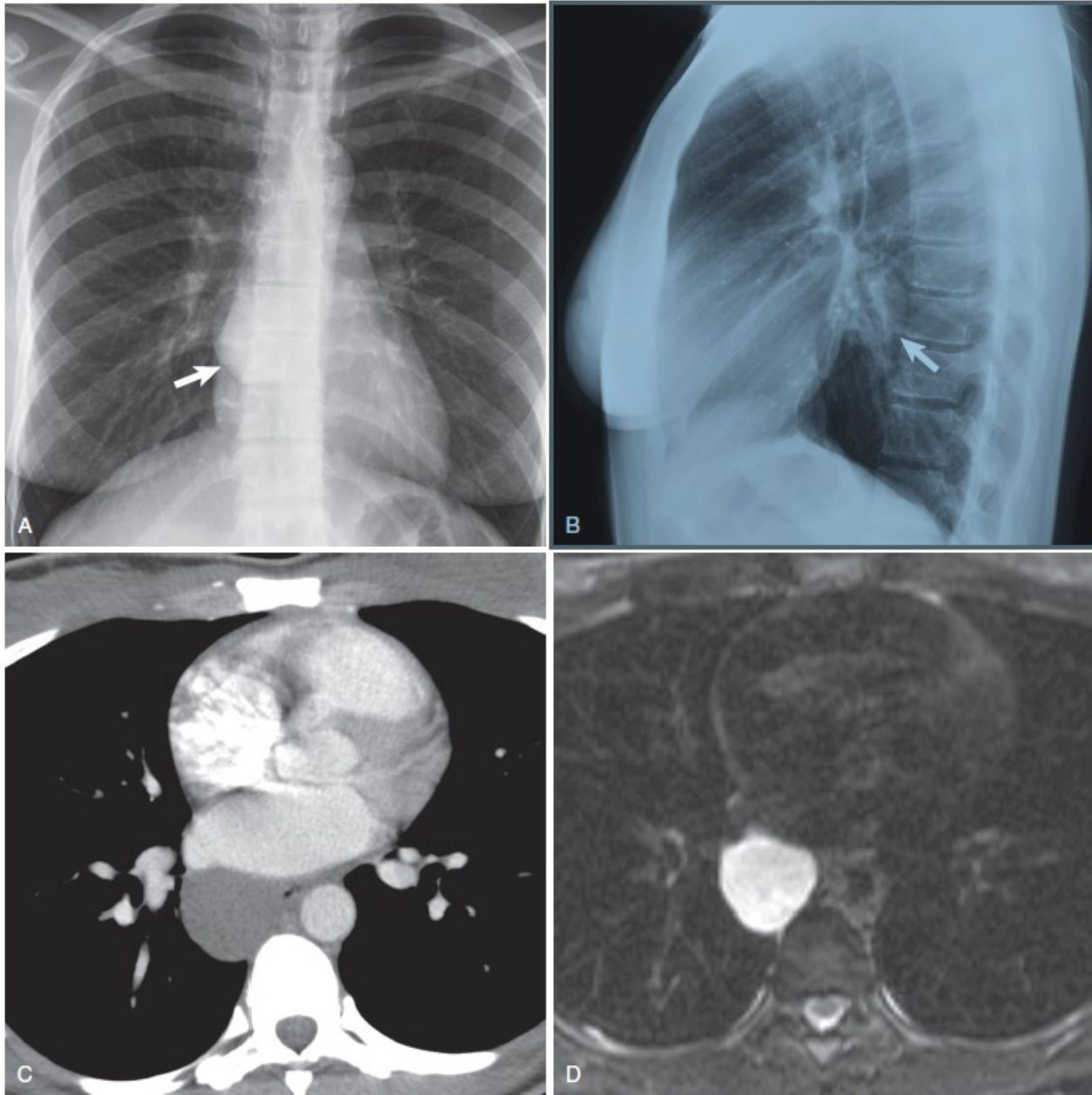




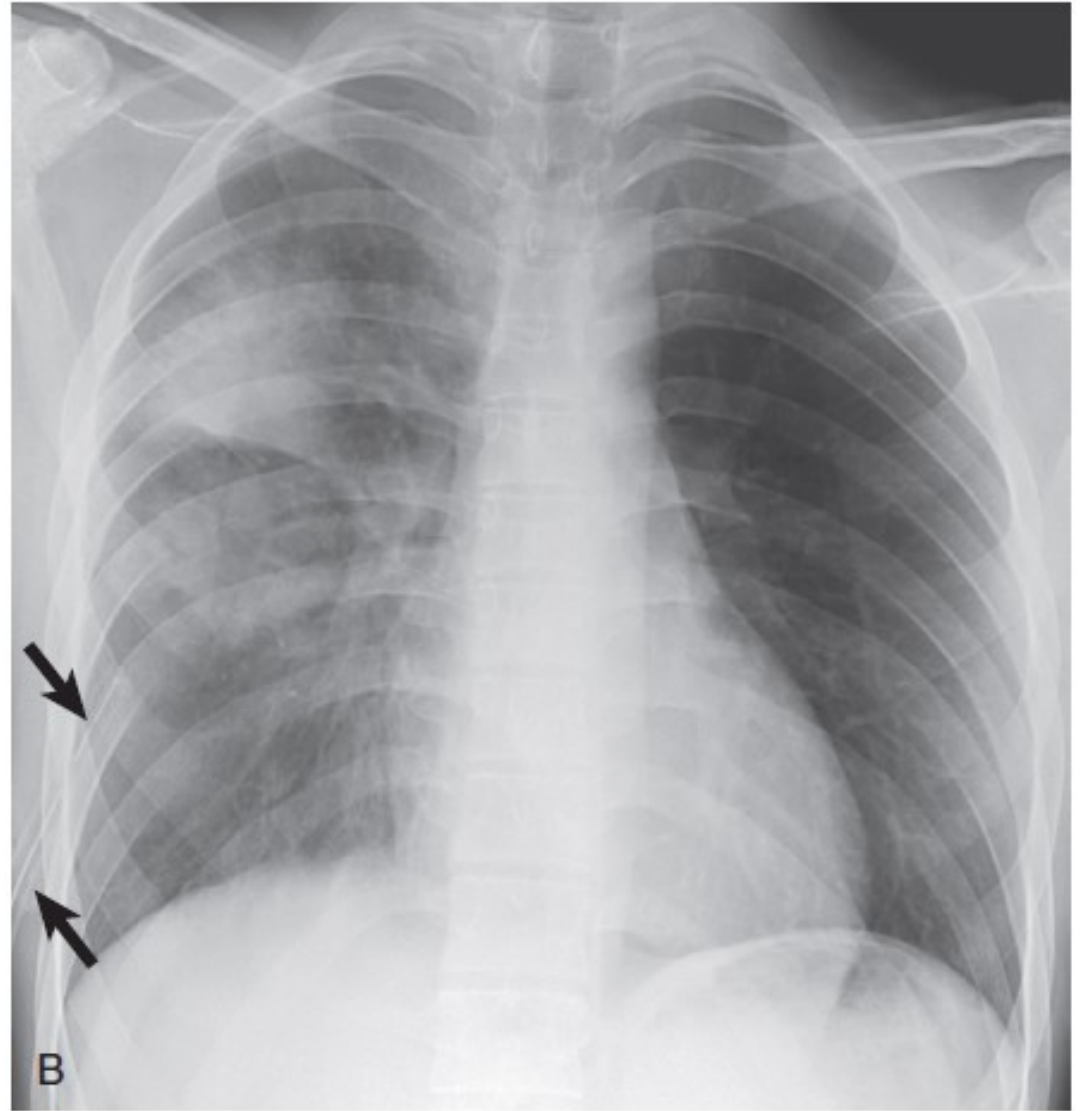


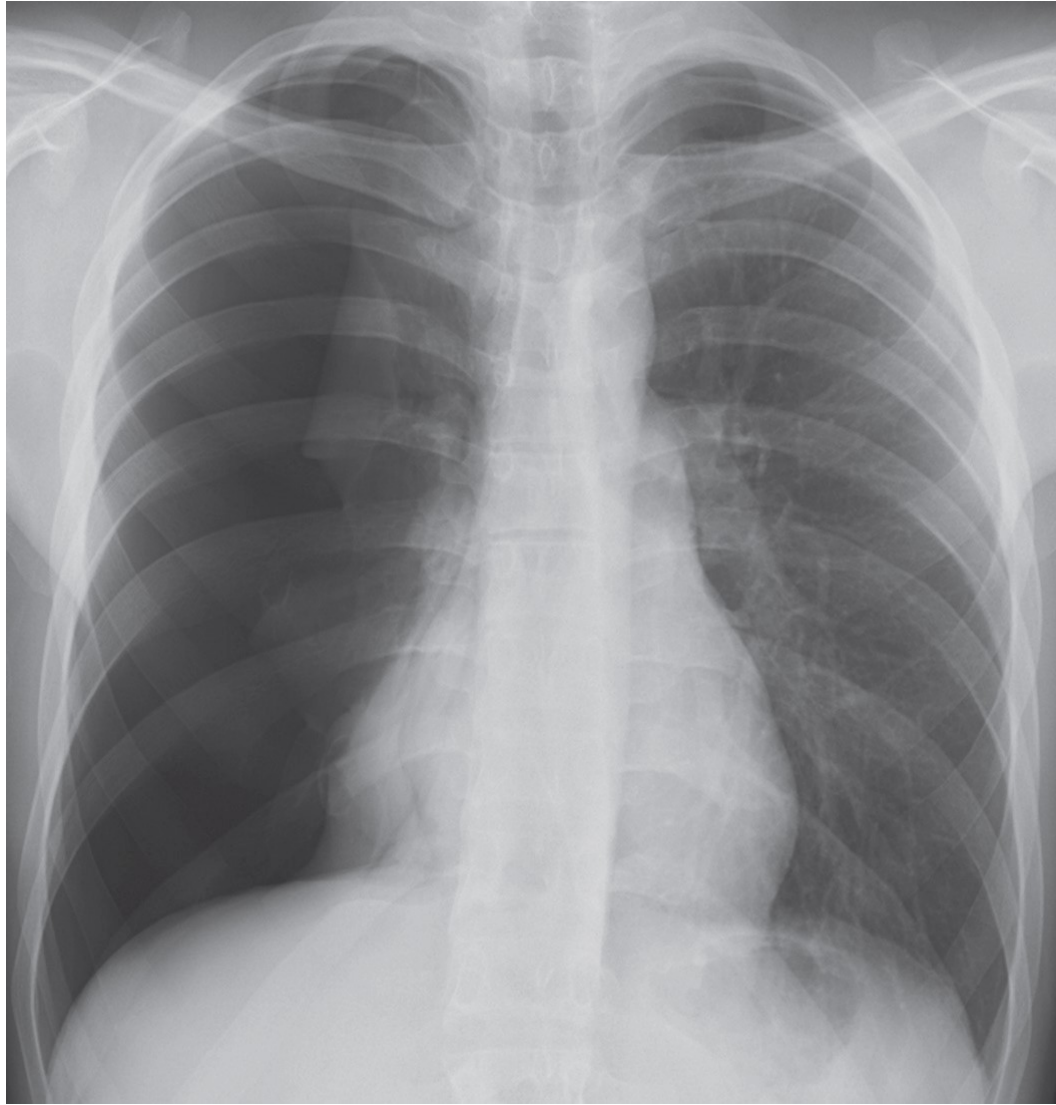

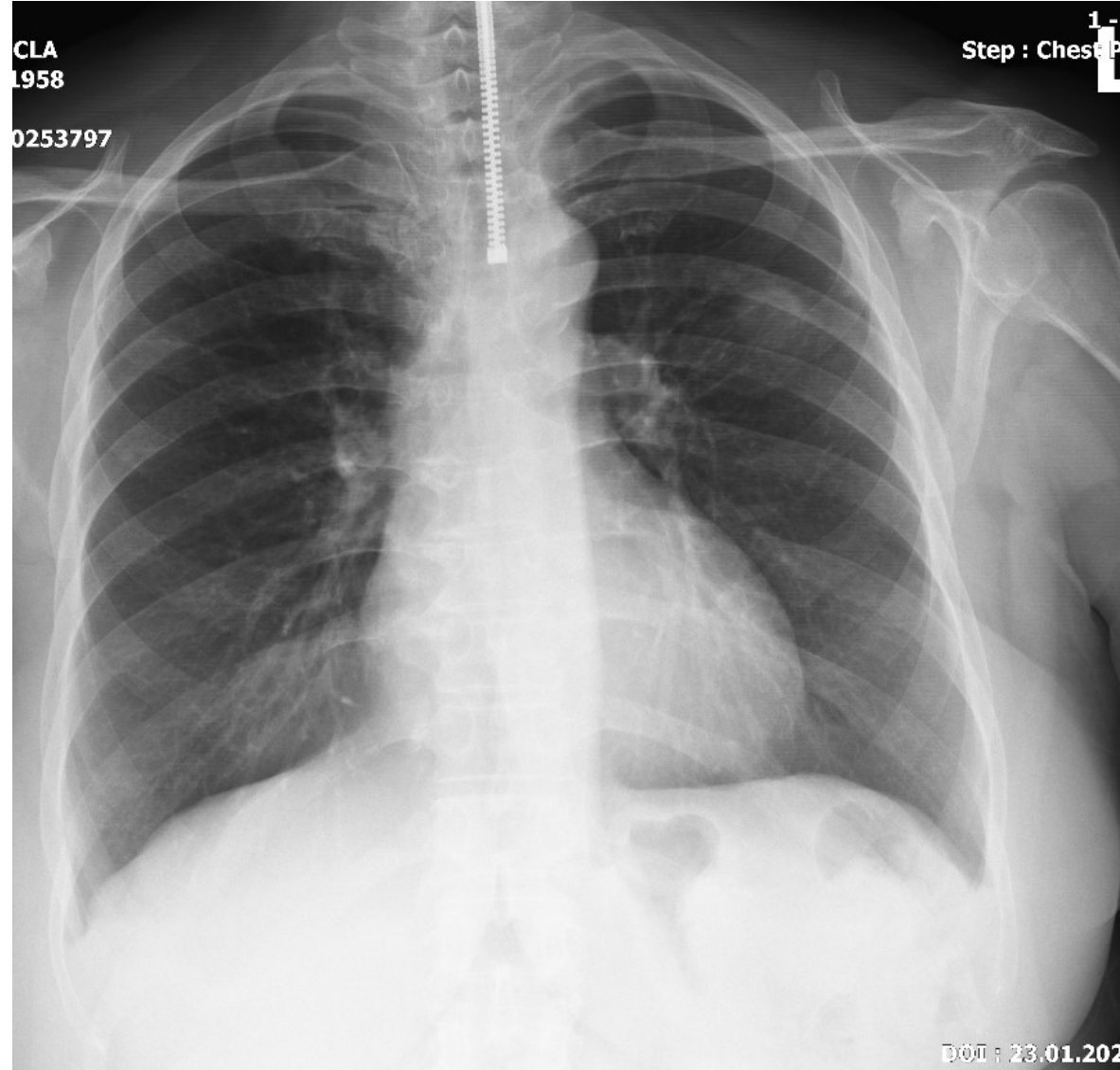


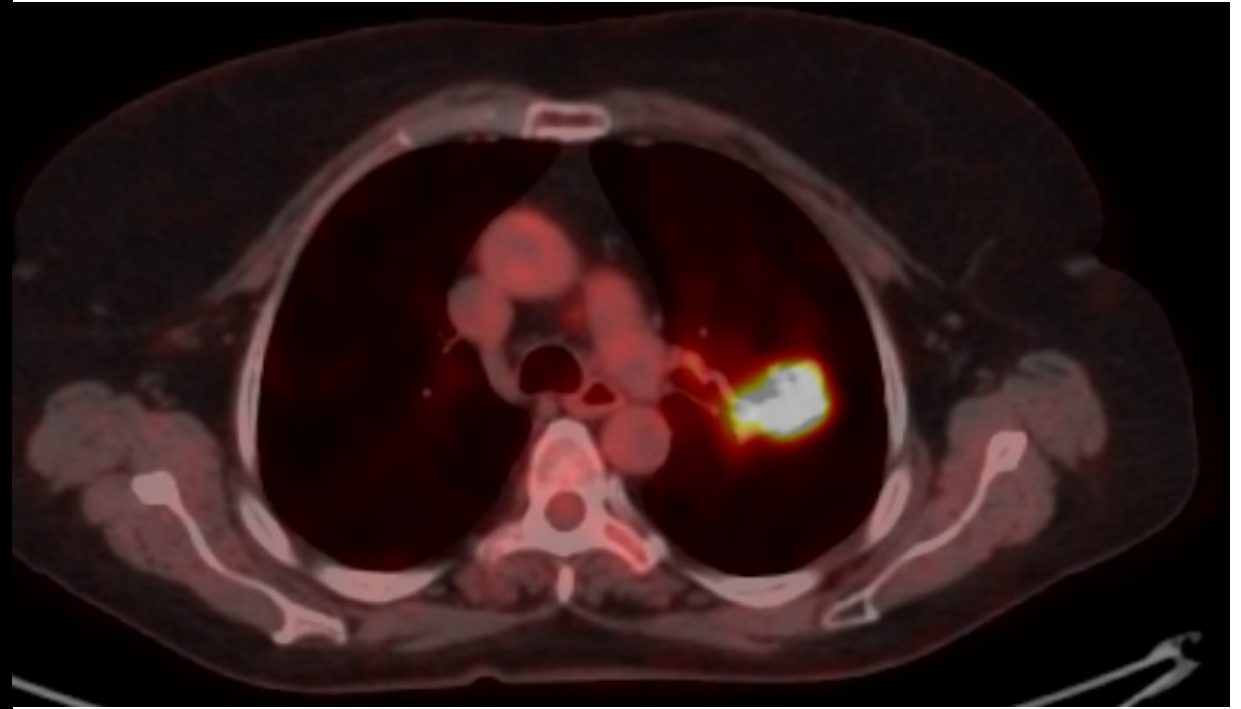


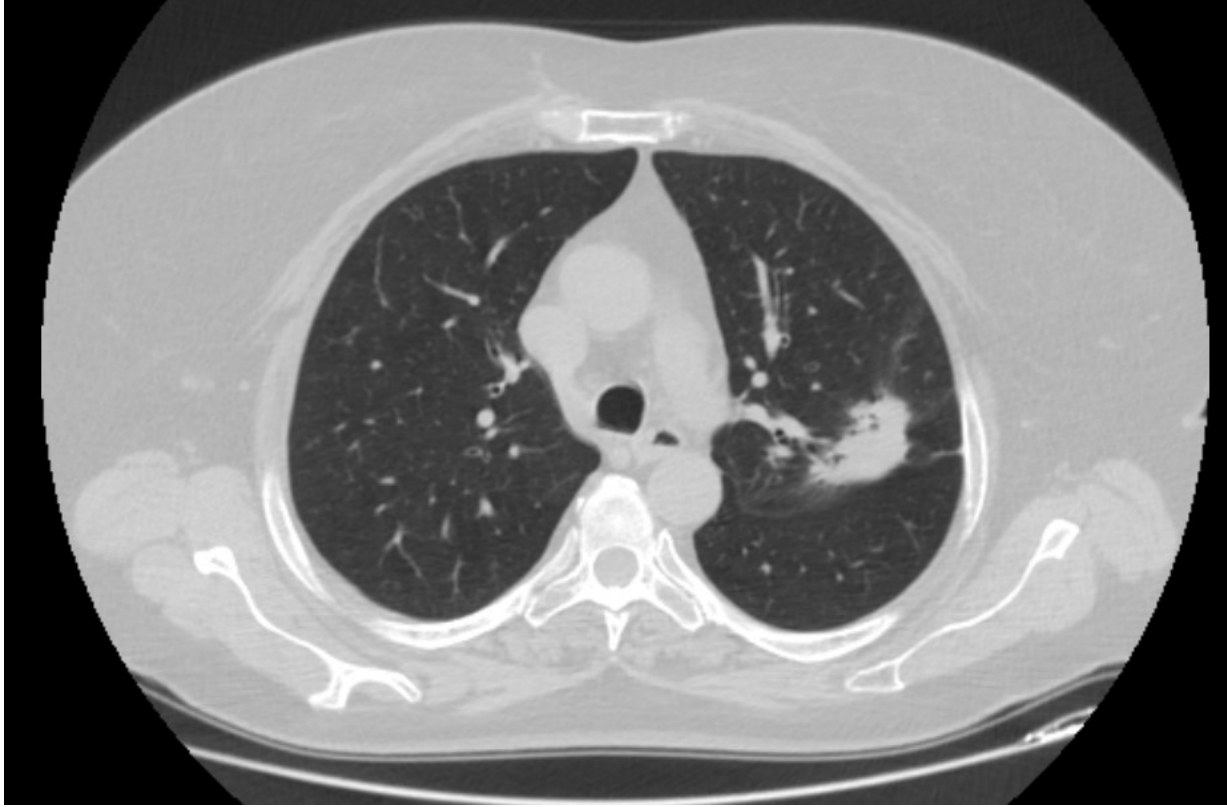**Fig. 7.6** Bronchogenic cyst. Posteroanterior (A) and lateral (B) chest radiographs show a well-circumscribed



65 yaşında kadın hasta uzun süreli öksürük nedeniyle başvurdu.





02670319

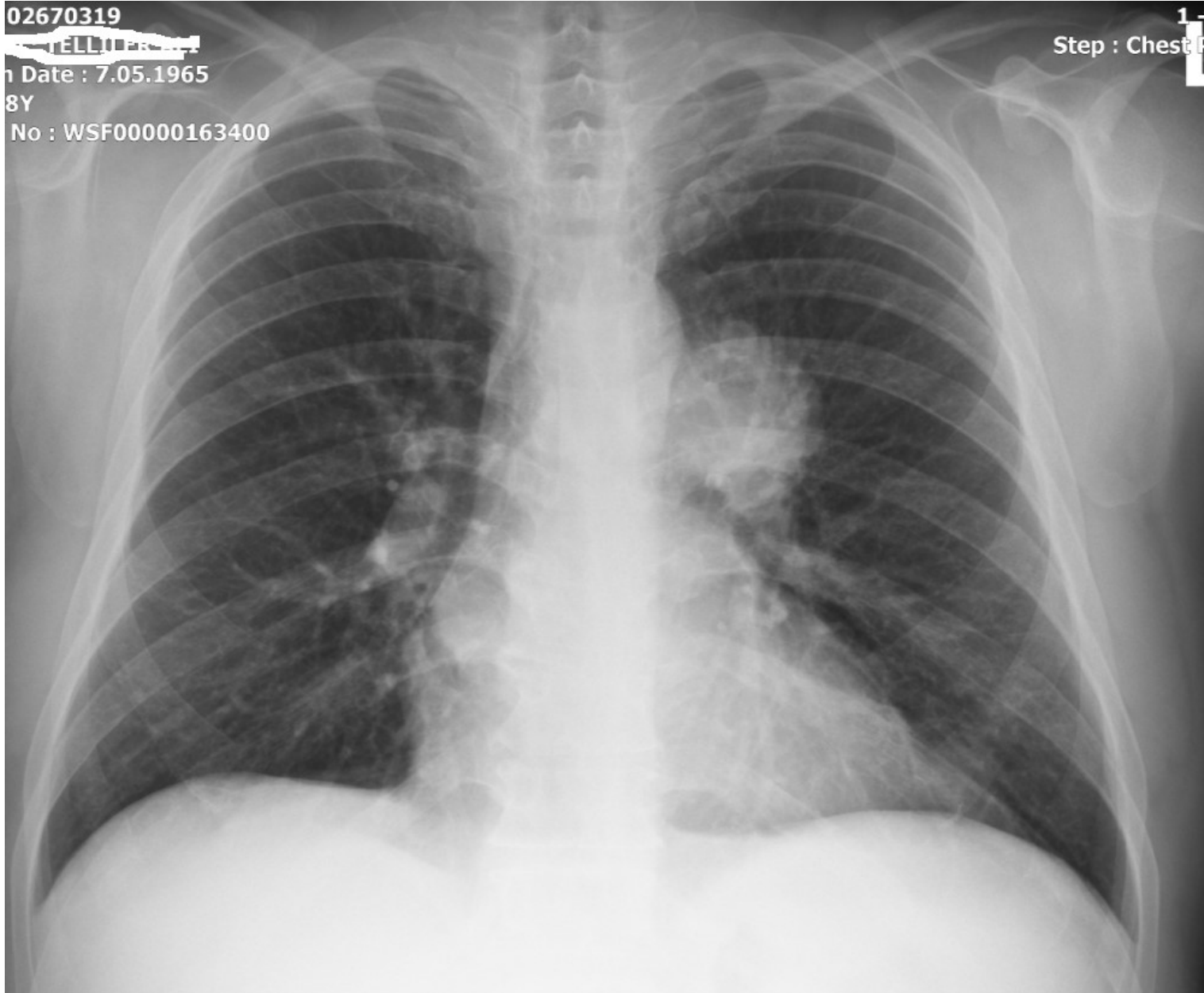
TELLIPR...

n Date : 7.05.1965

8Y

No : WSF00000163400

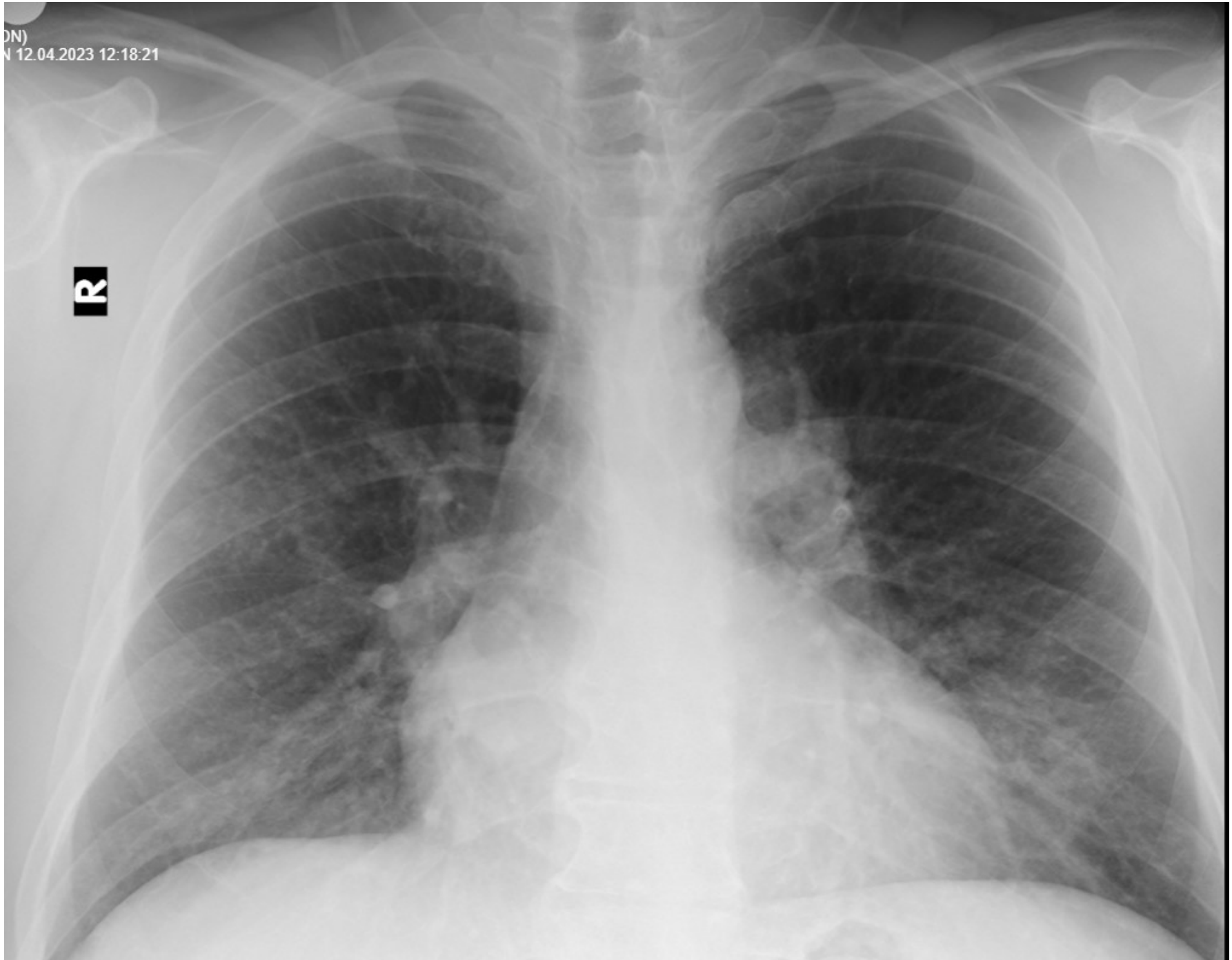1 -  
Step : Chest P





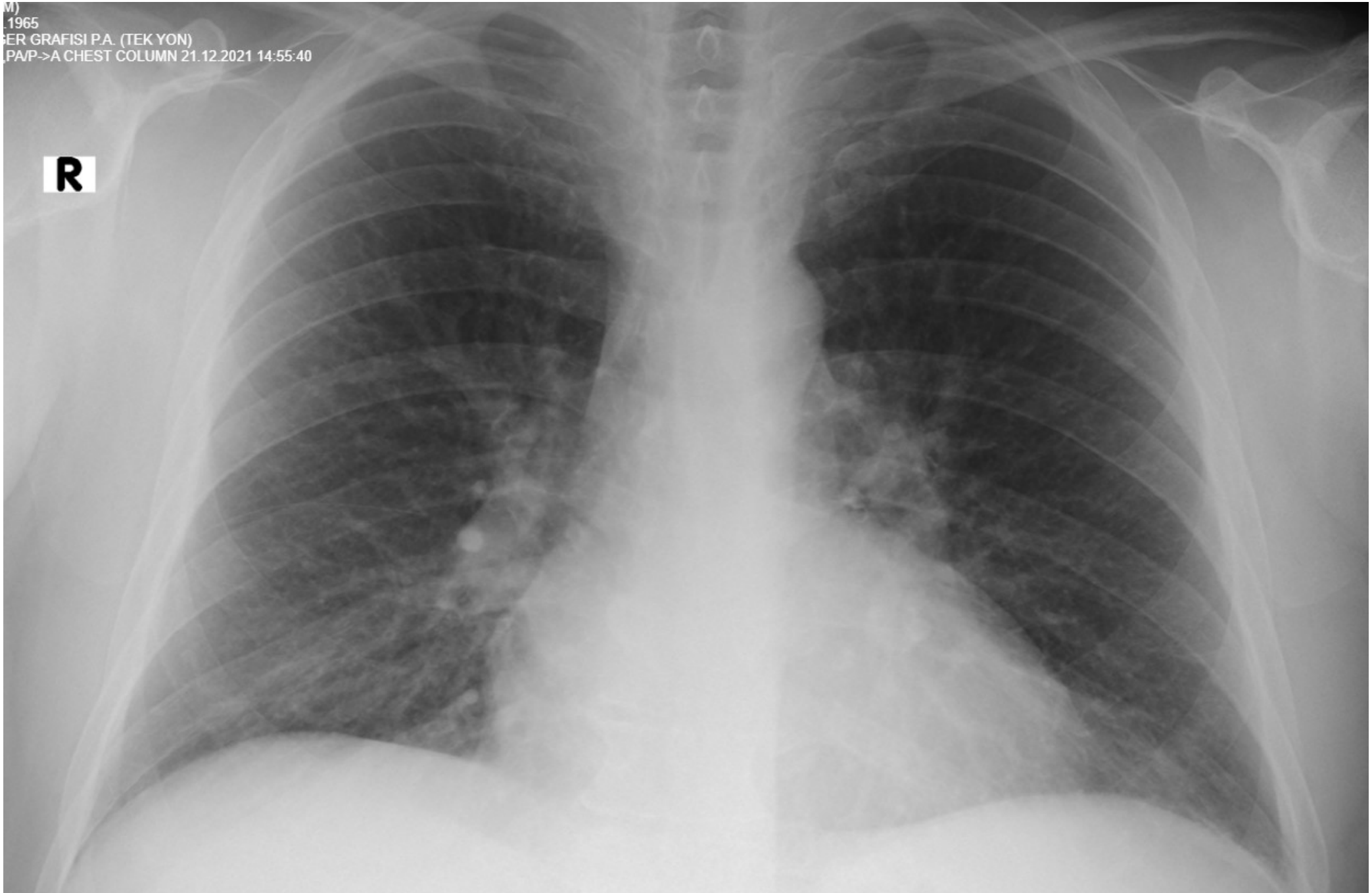DN)  
N 12.04.2023 12:18:21

**R**



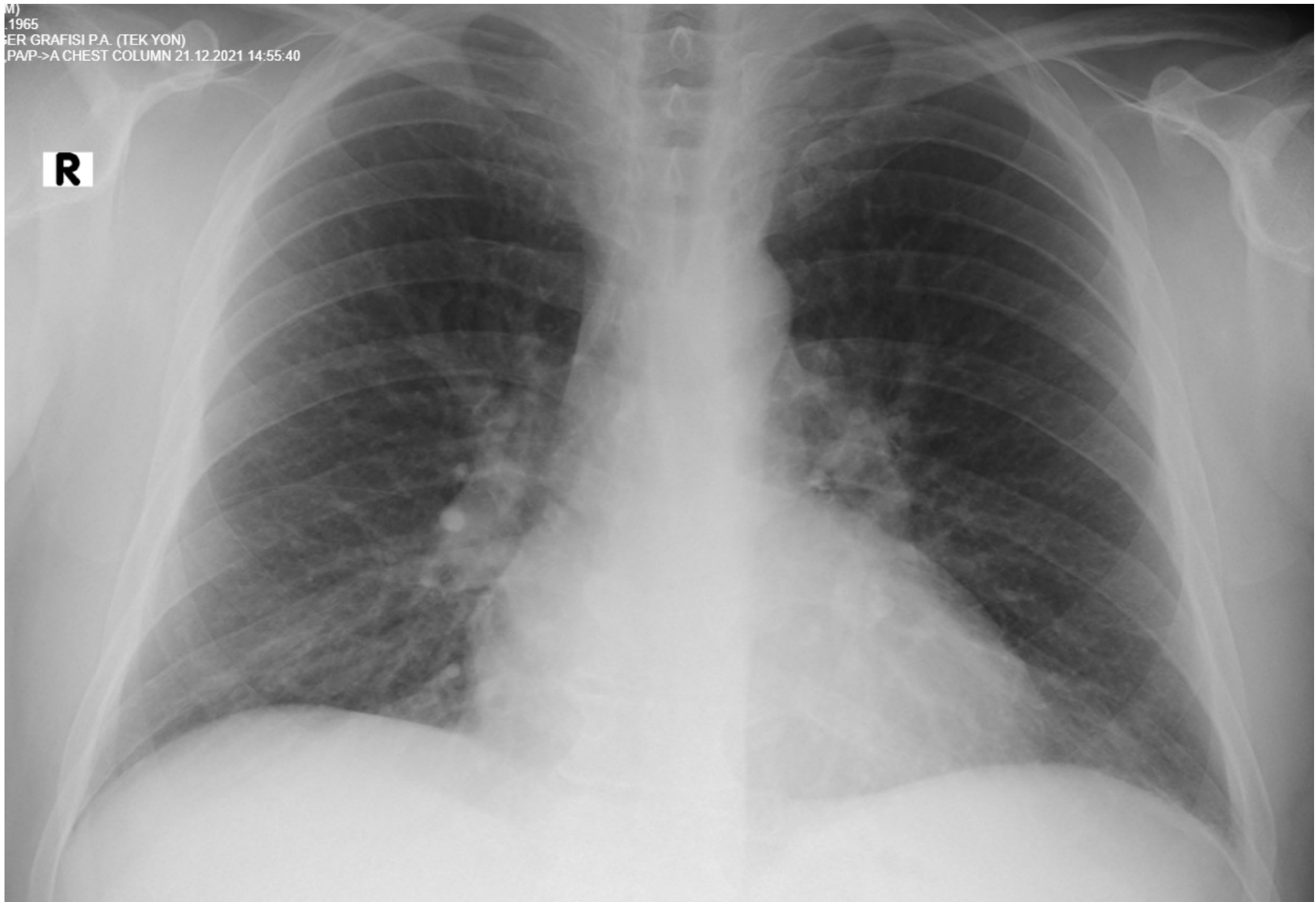M)  
1965  
ER GRAFISI P.A. (TEK YON)  
PA/P->A CHEST COLUMN 21.12.2021 14:55:40

**R**

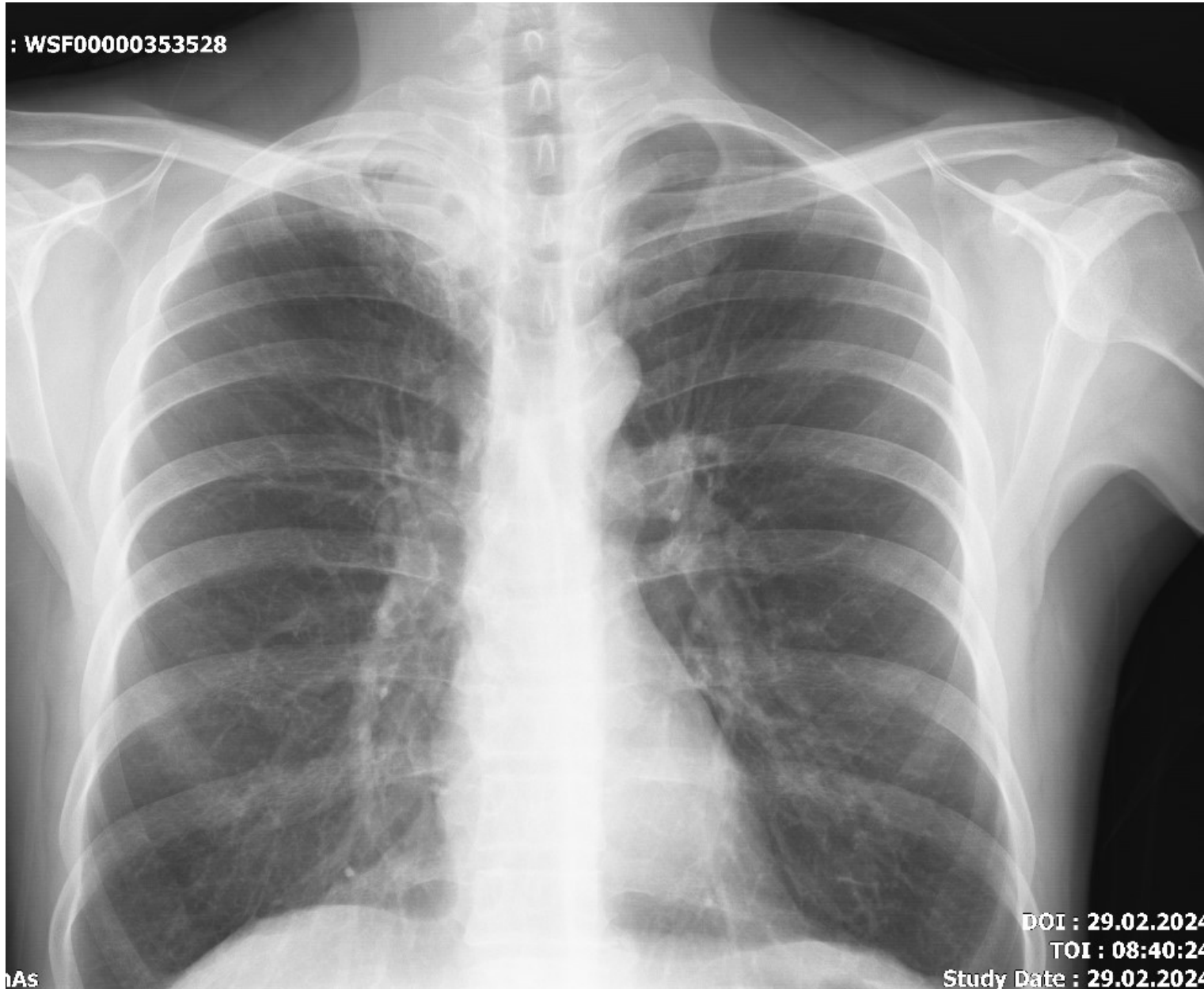


M)  
.1965  
ER GRAFISI P.A. (TEK YON)  
PAP->A CHEST COLUMN 21.12.2021 14:55:40

**R**



: WSF00000353528

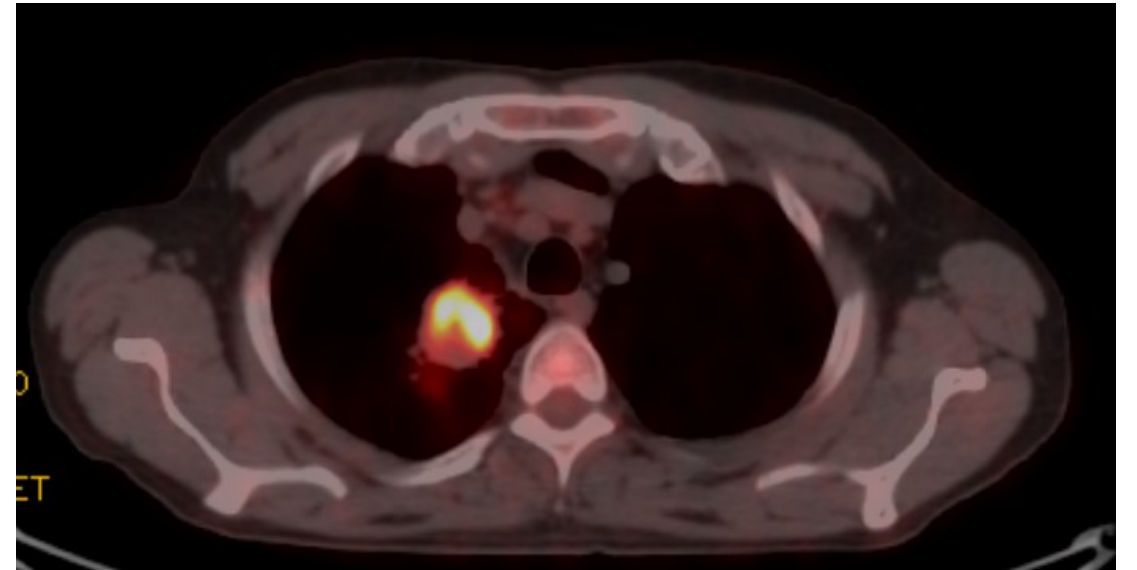
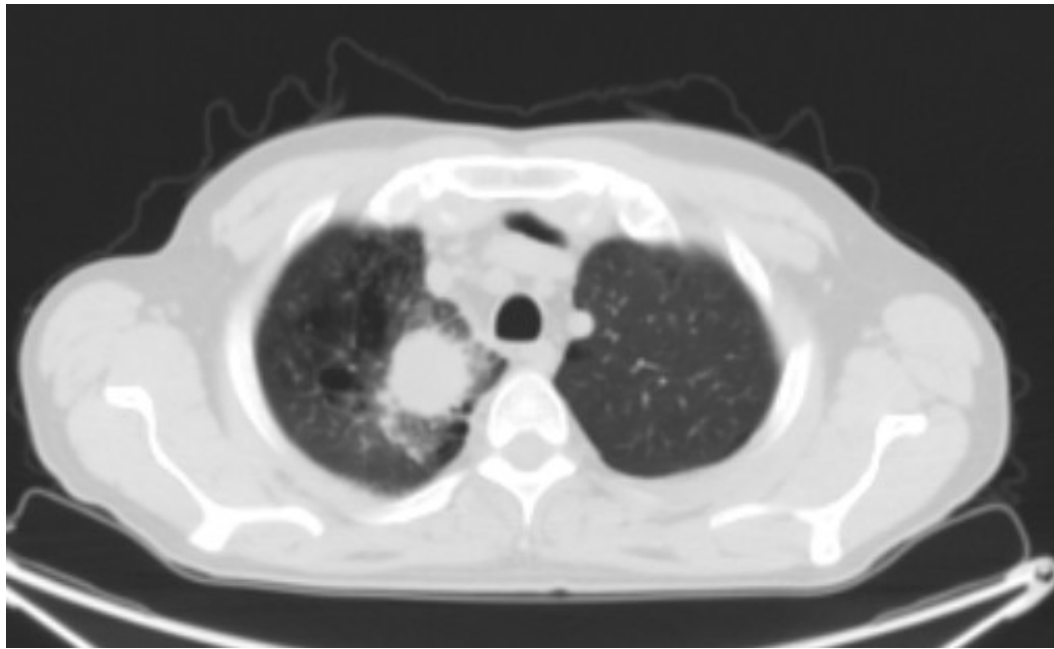
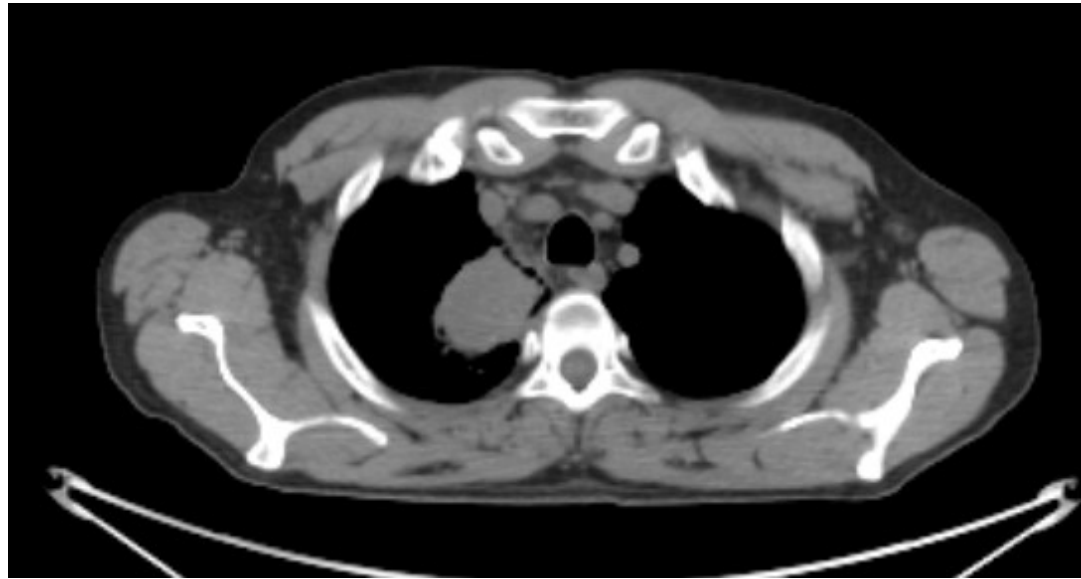


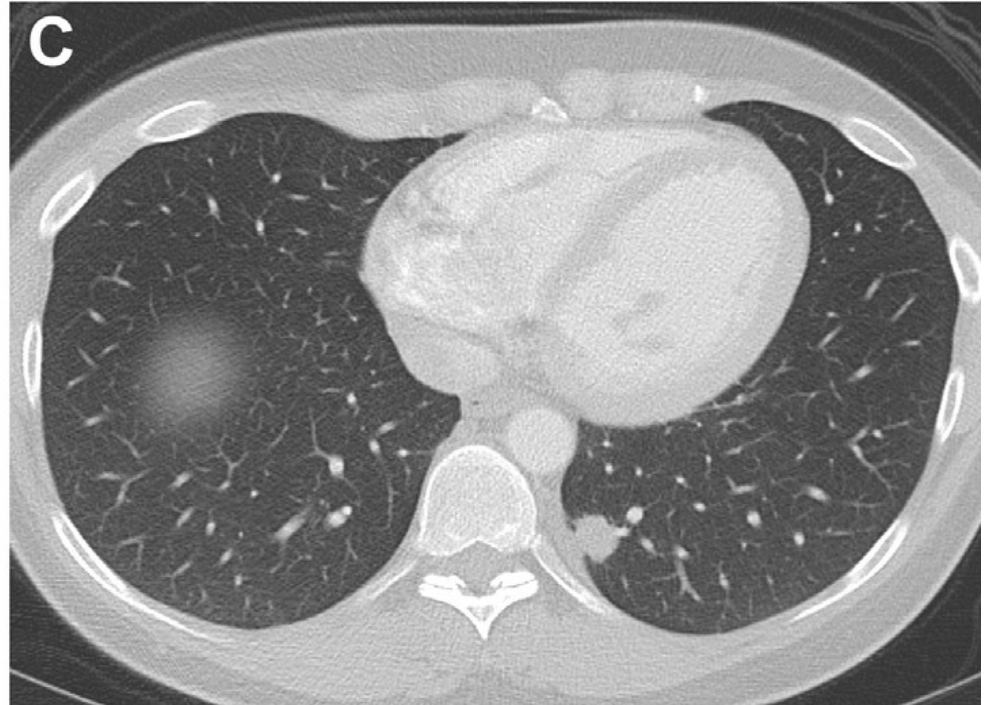
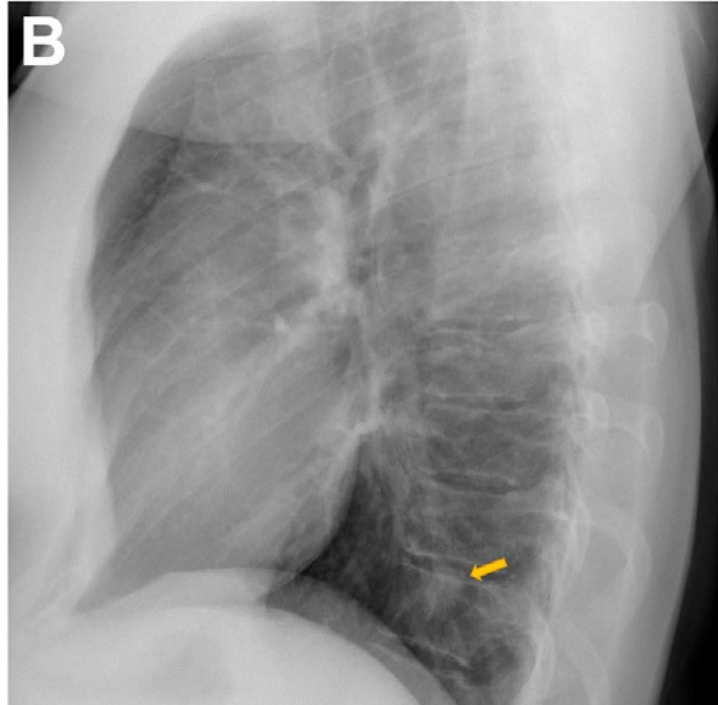
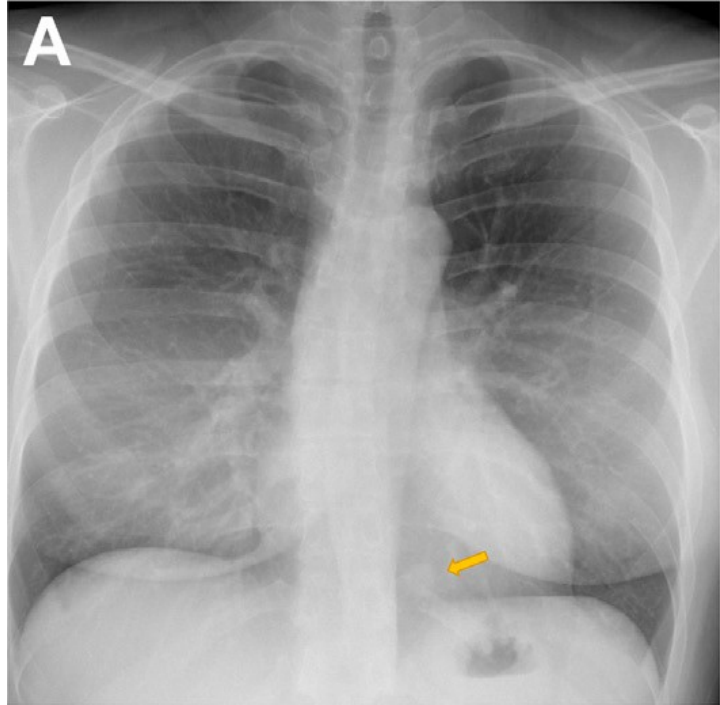
DOI : 29.02.2024

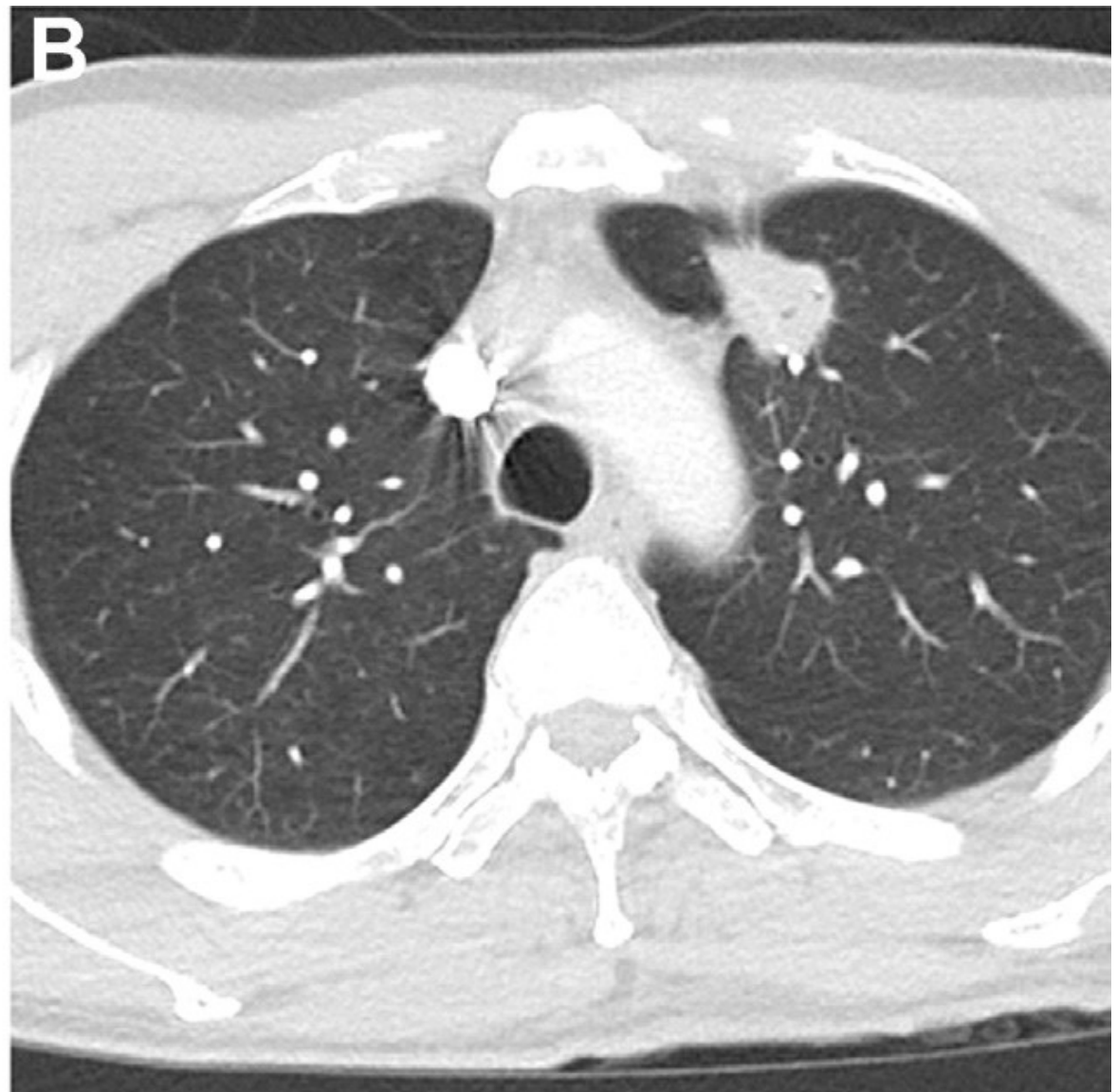
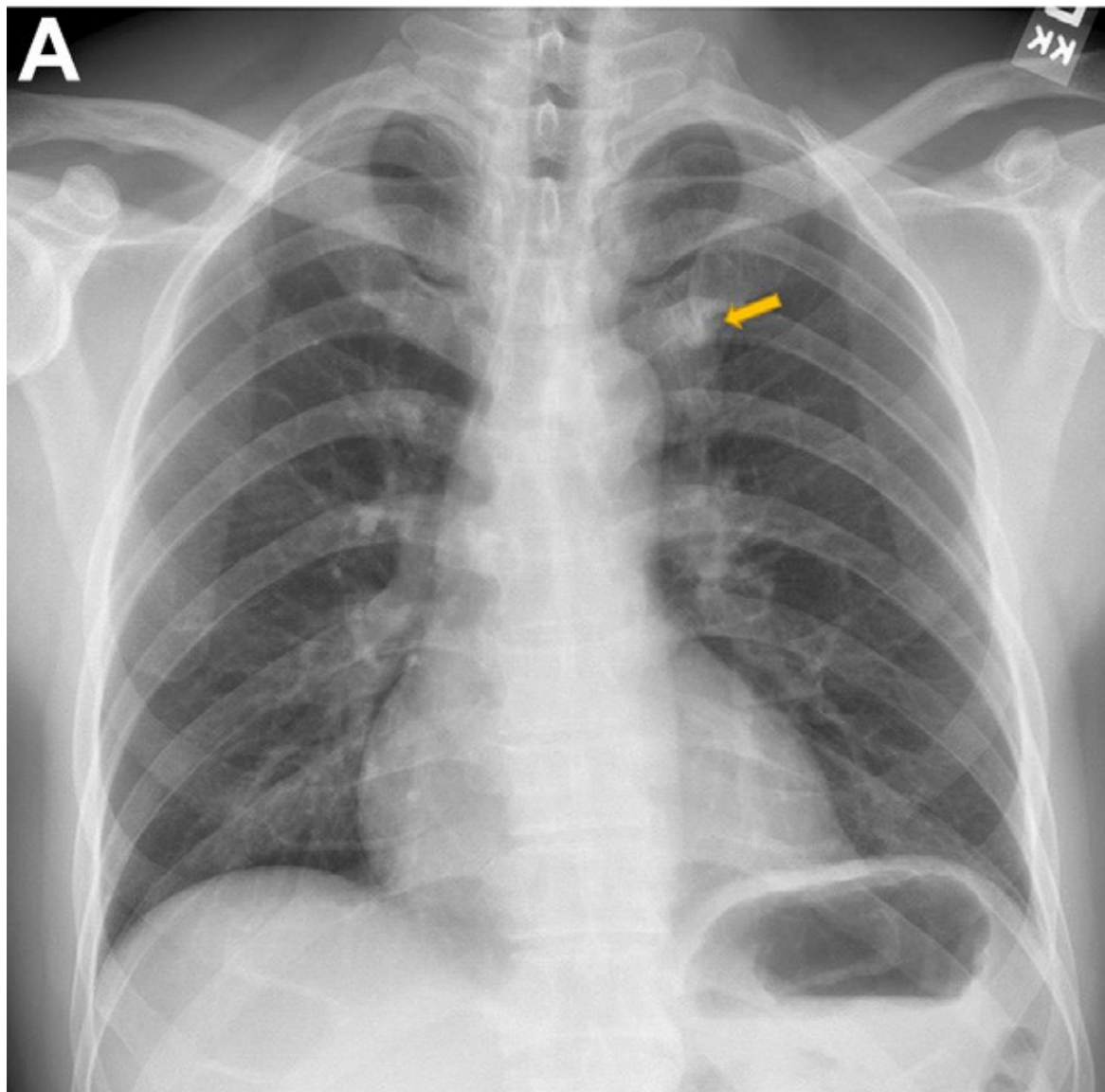
TOI : 08:40:24

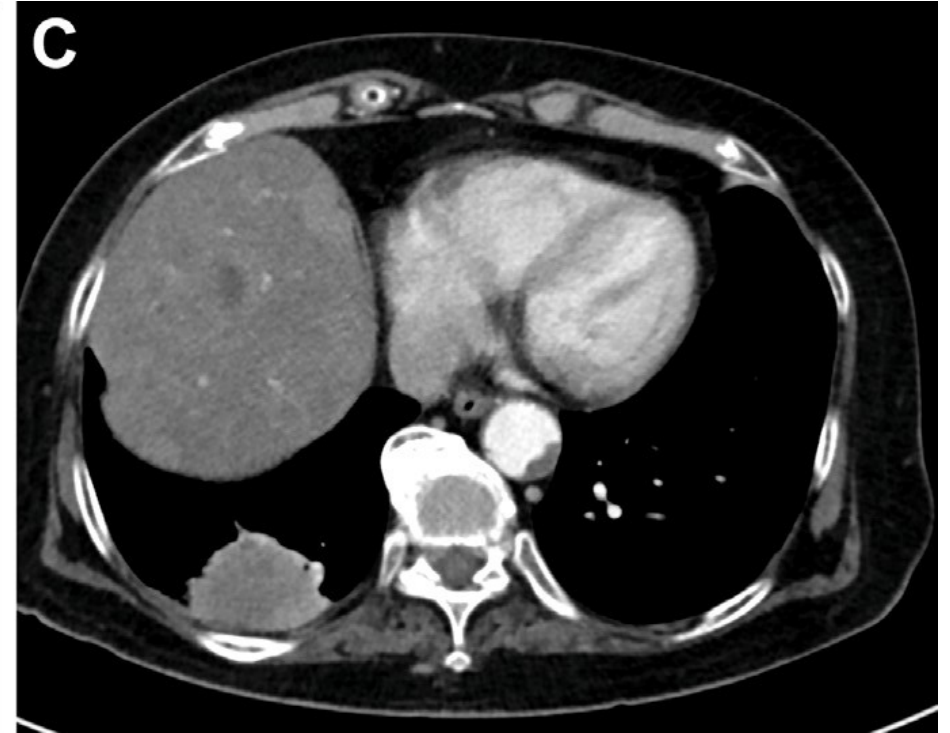
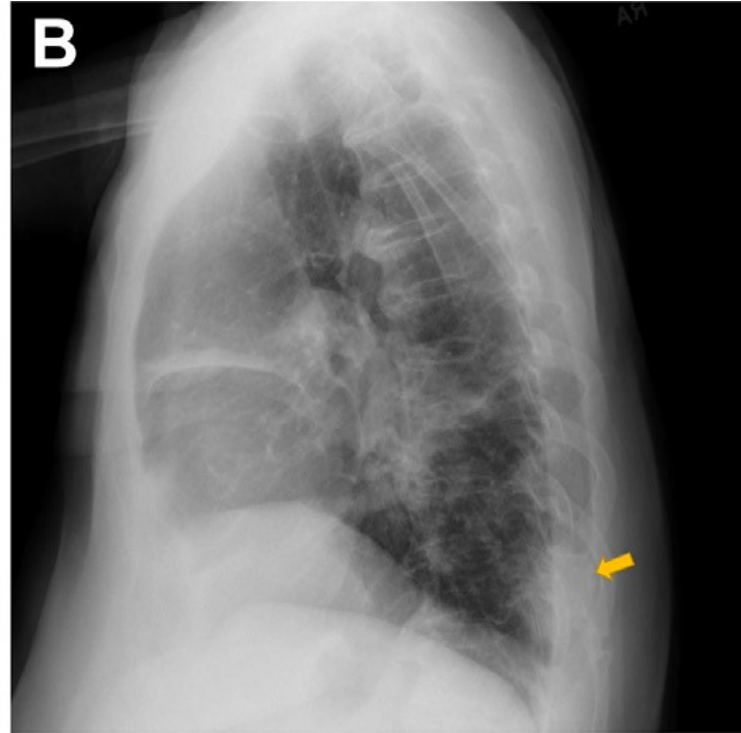
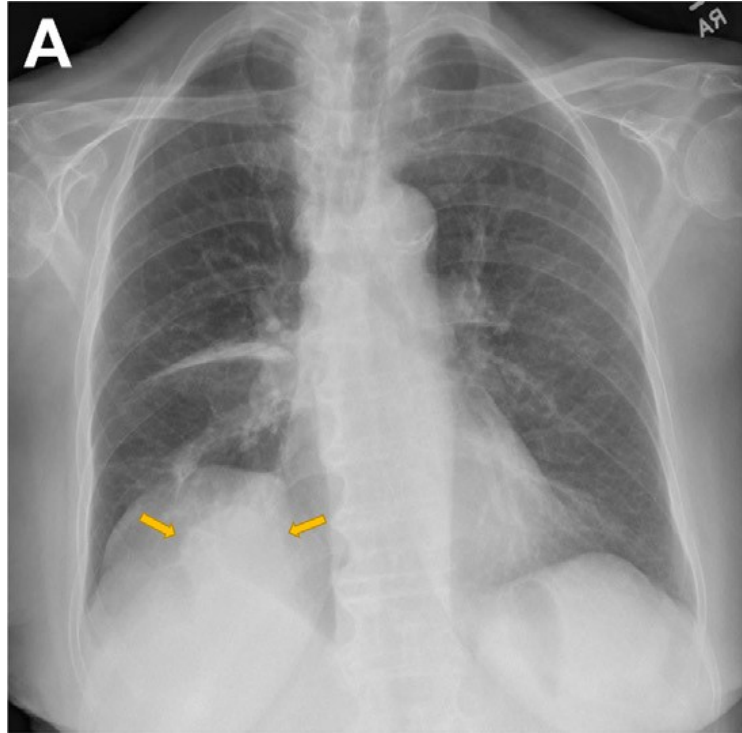
Study Date : 29.02.2024

As

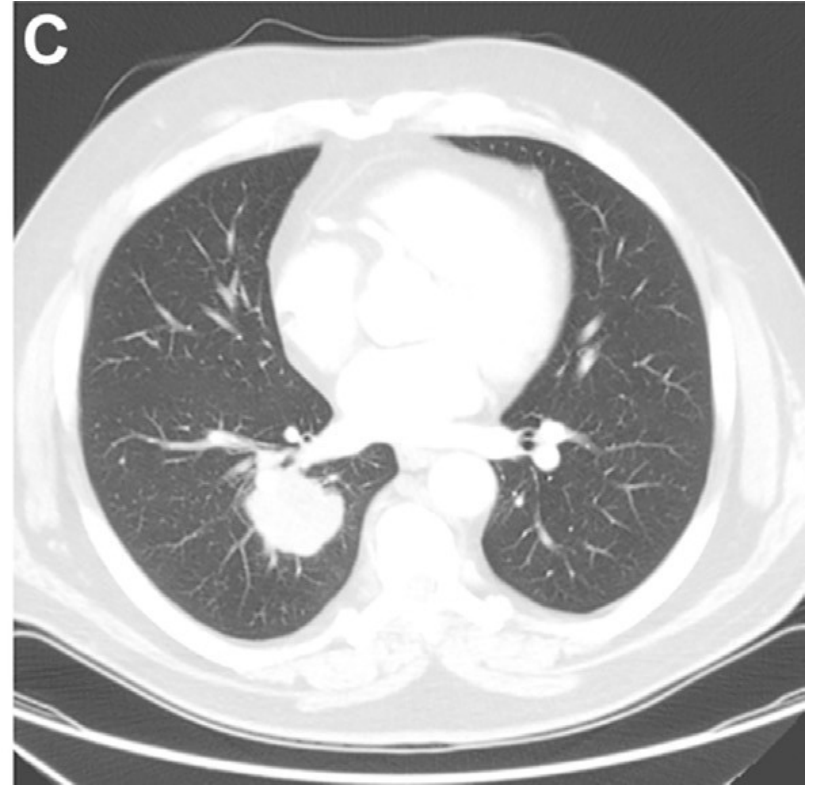
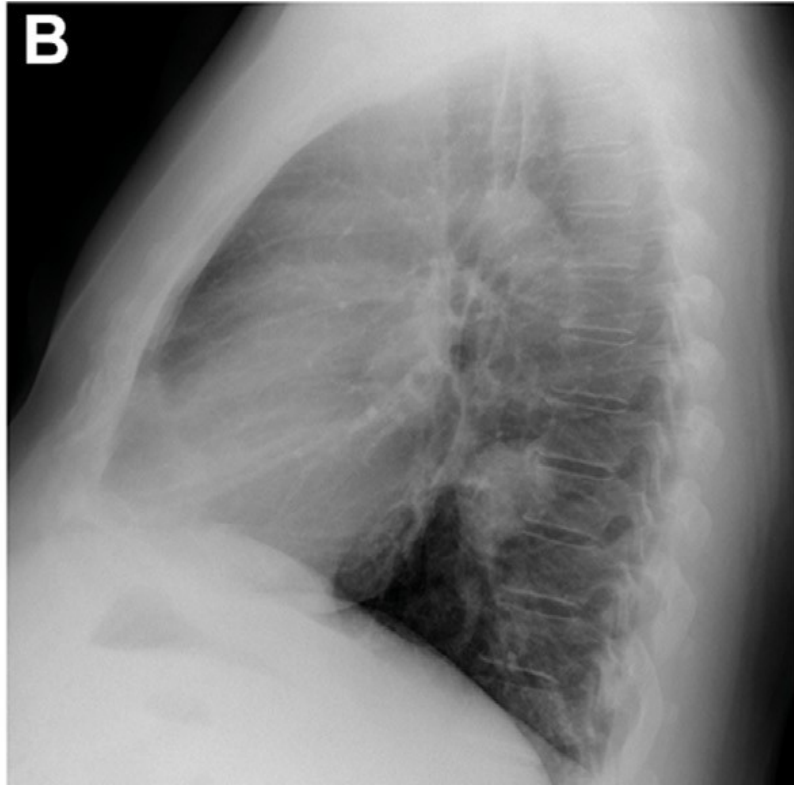
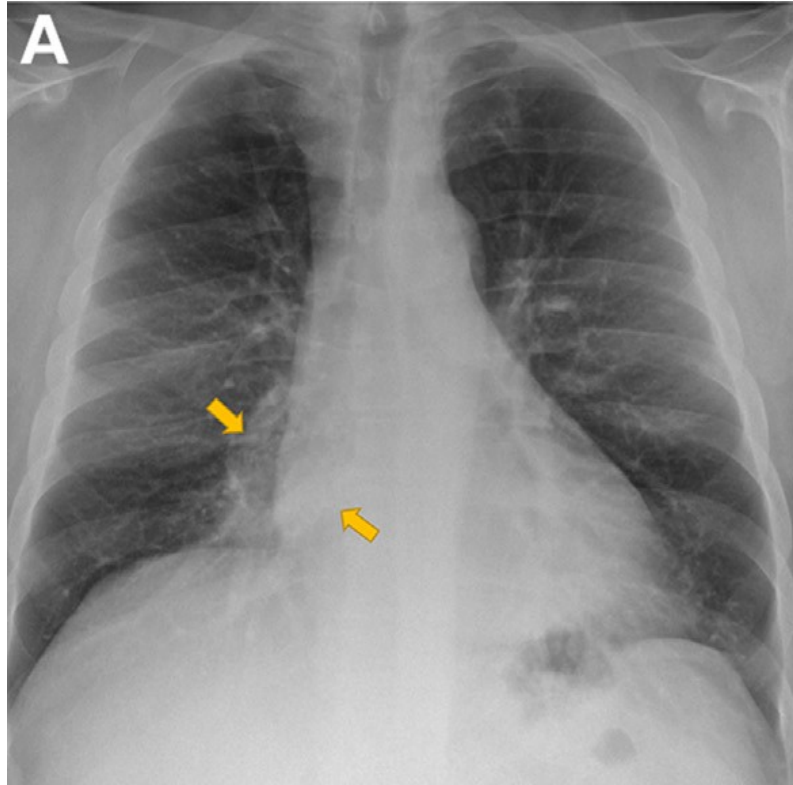


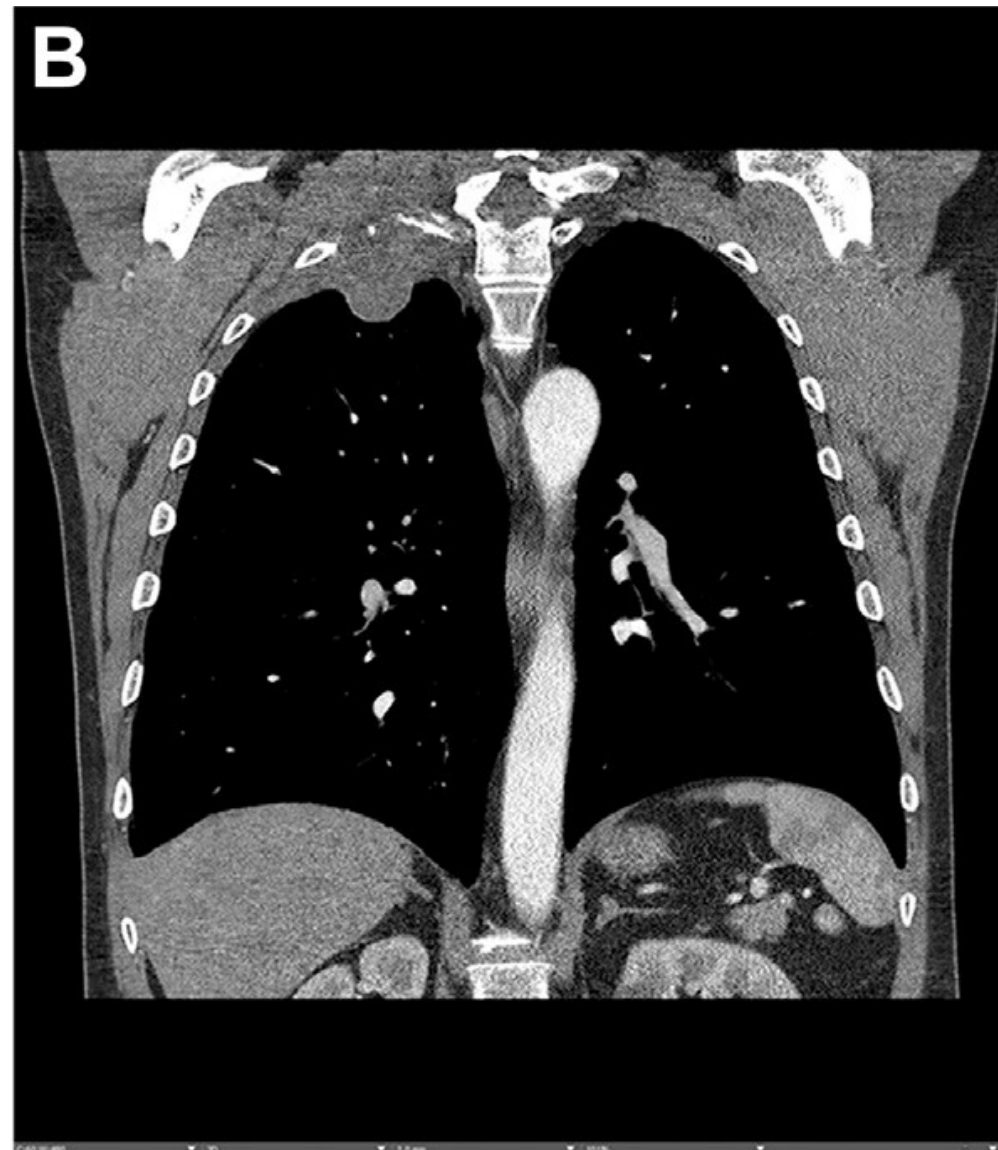
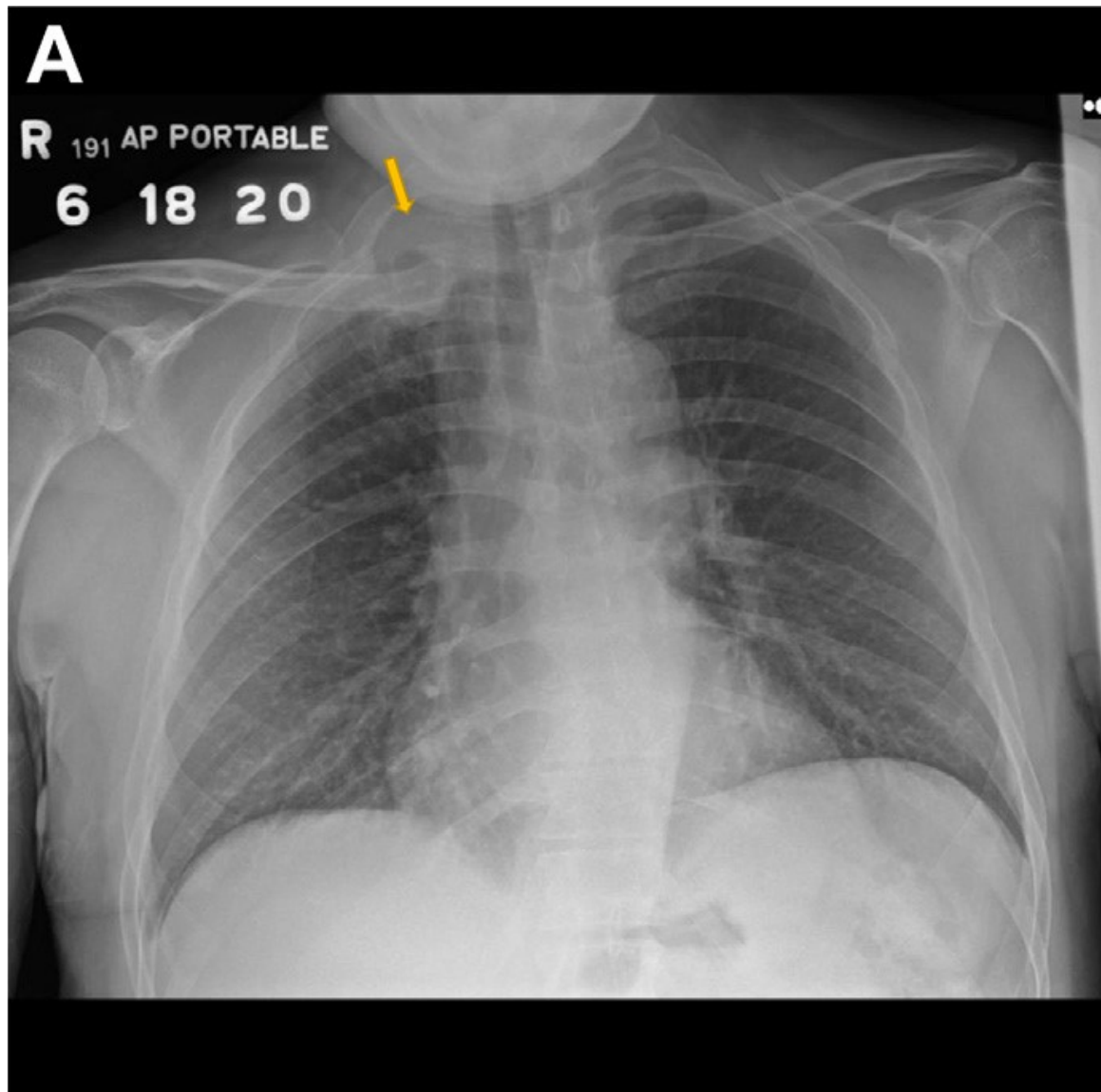


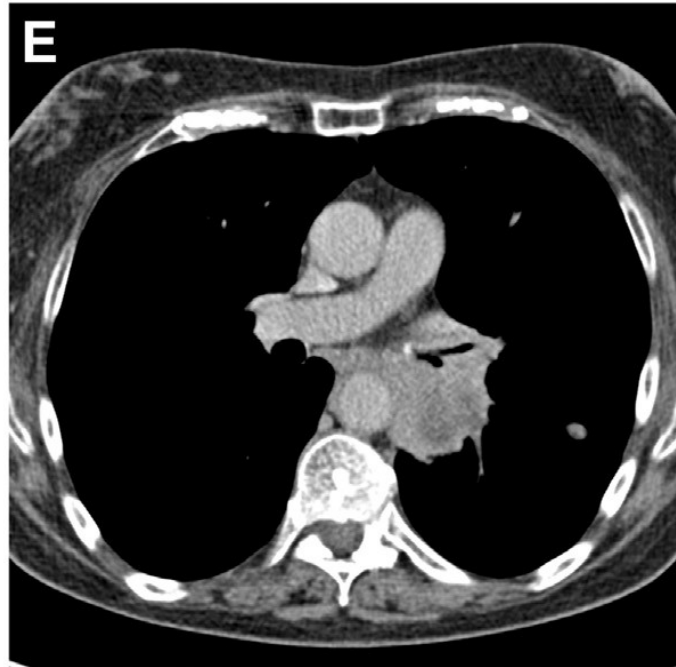
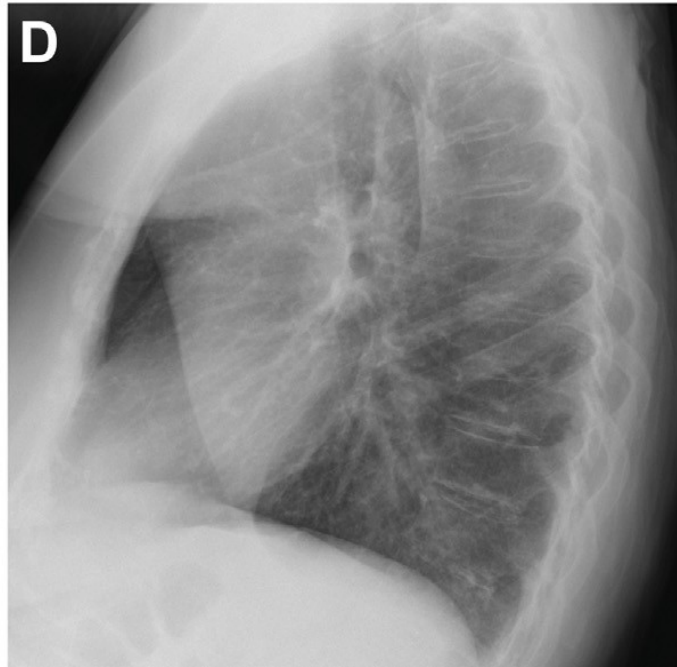
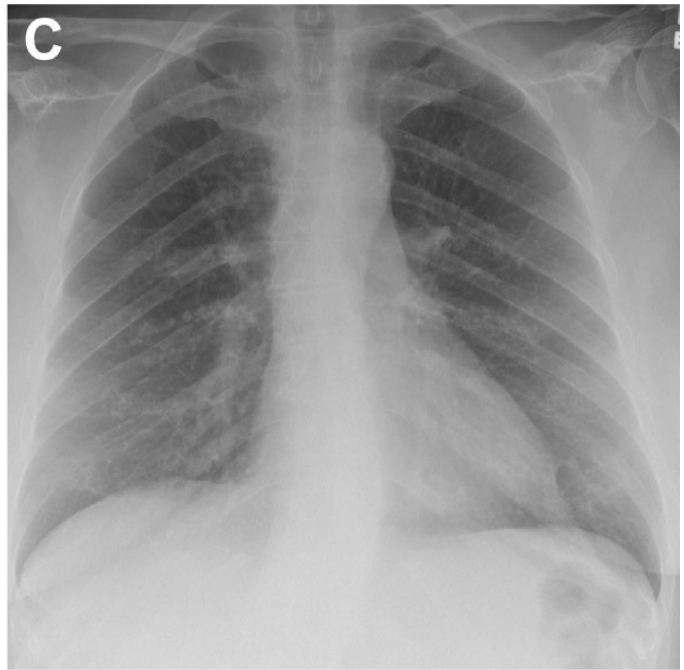
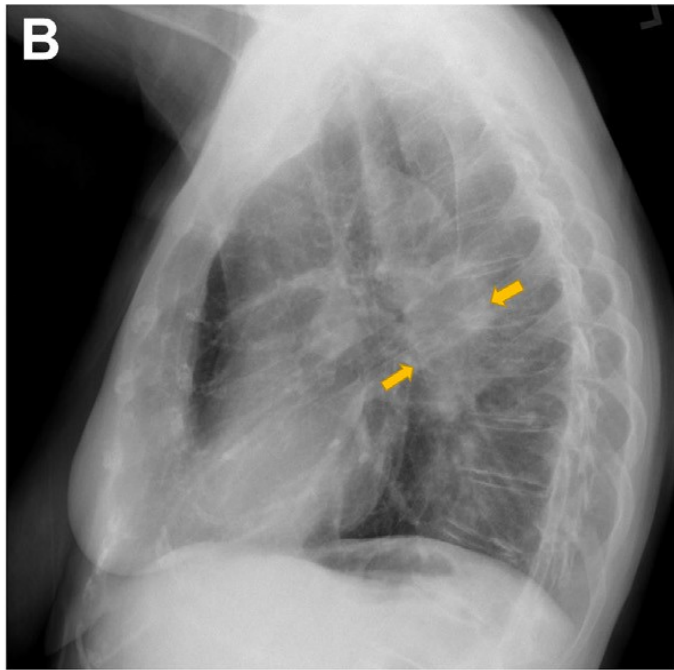
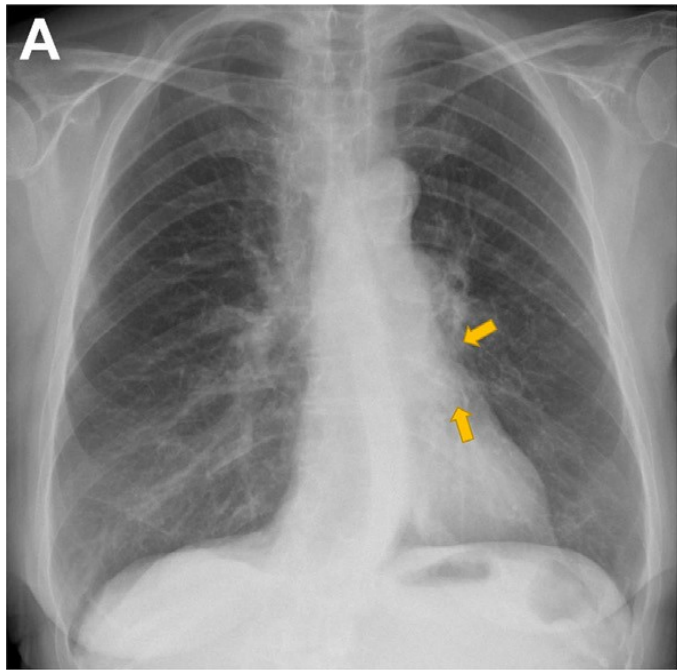


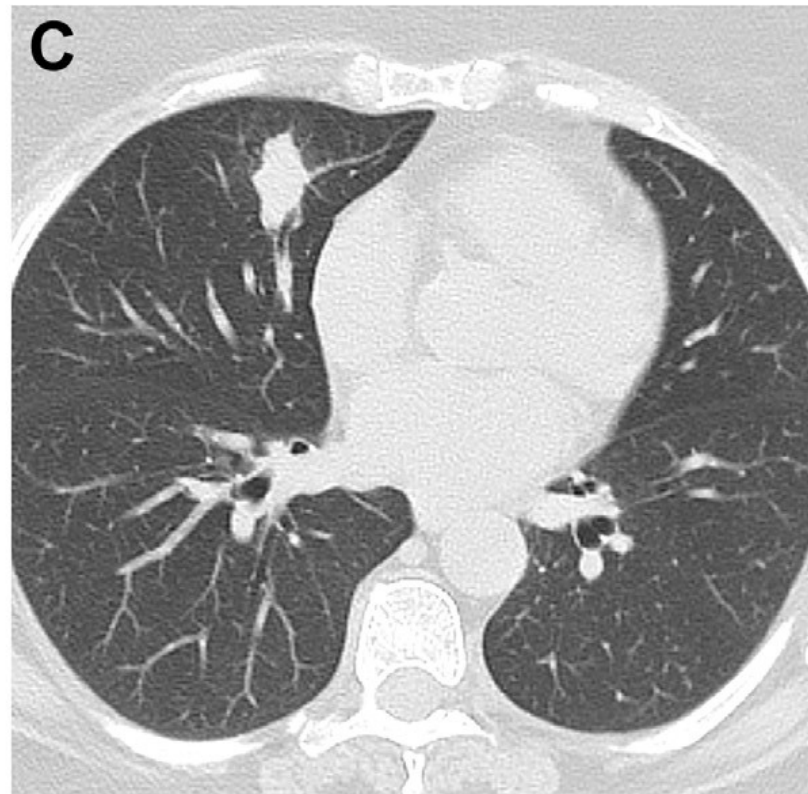
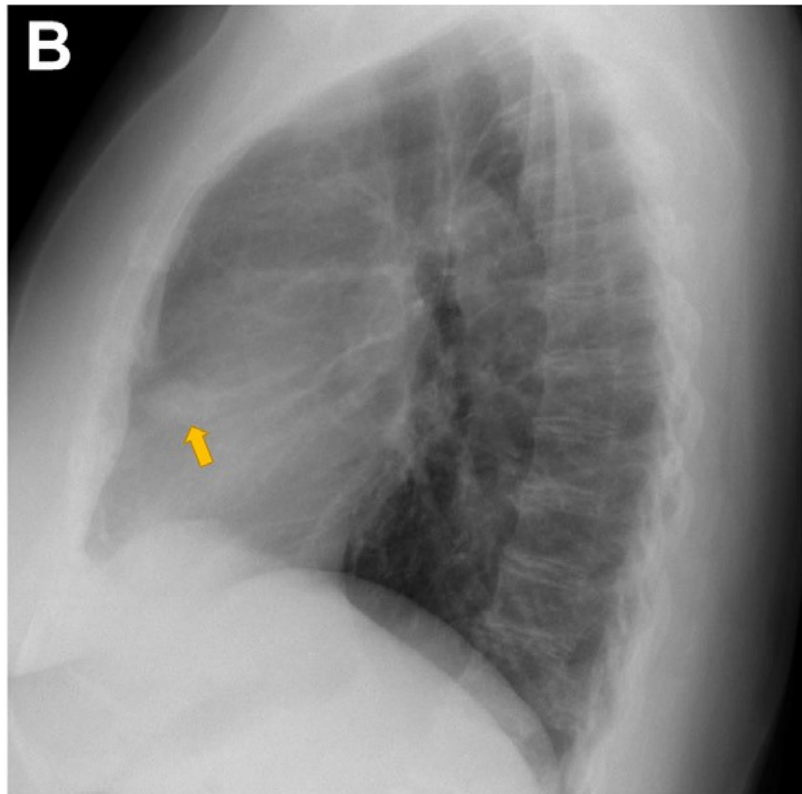
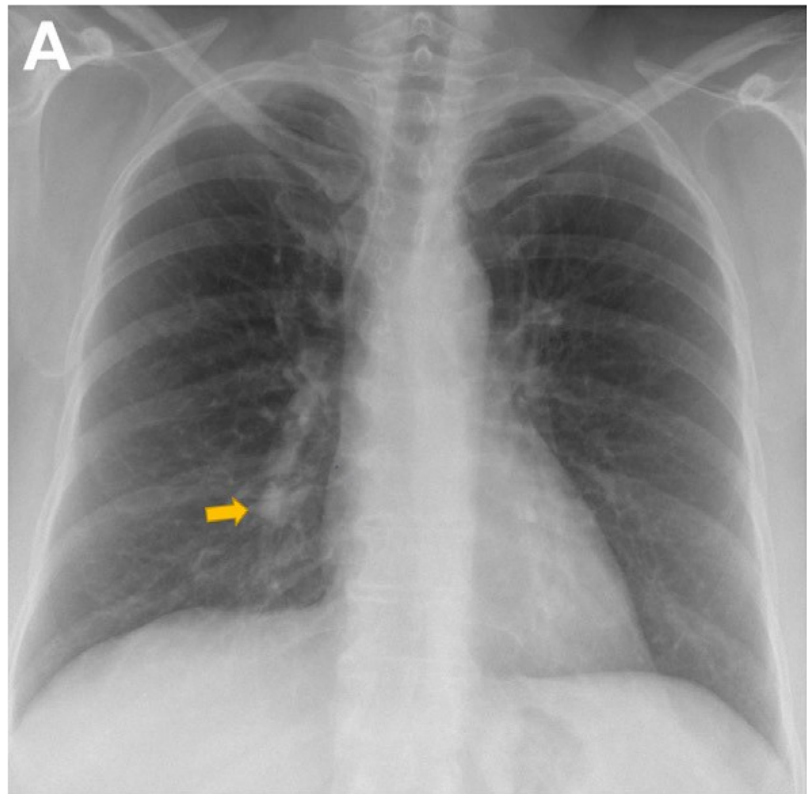


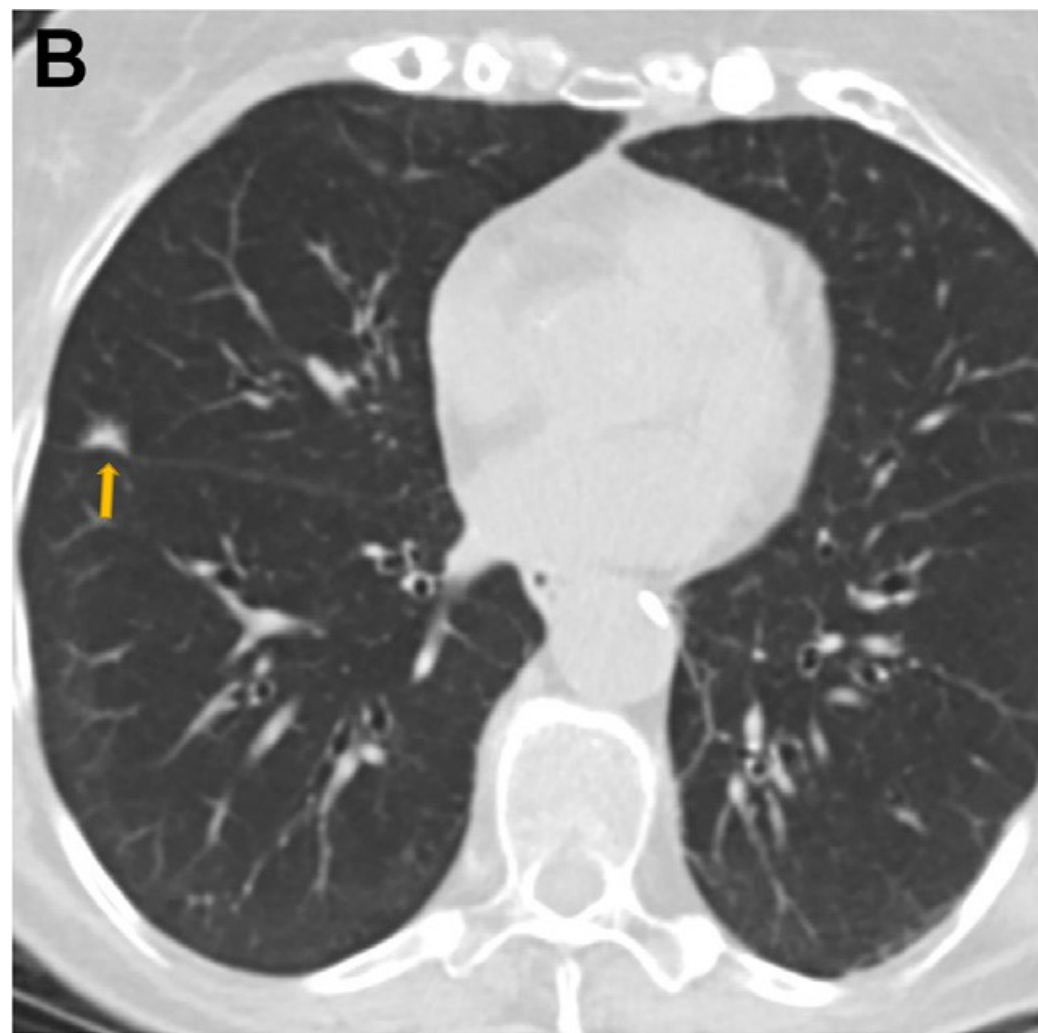
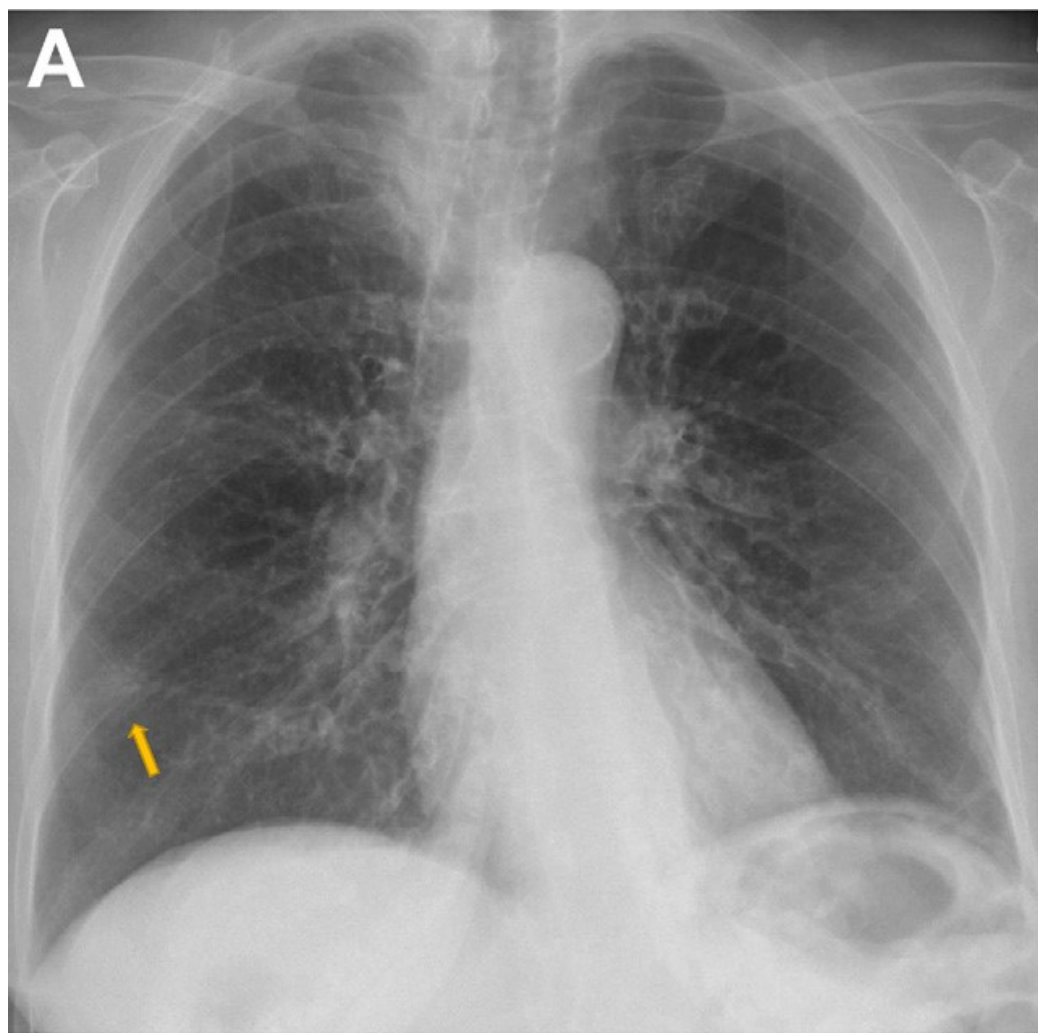


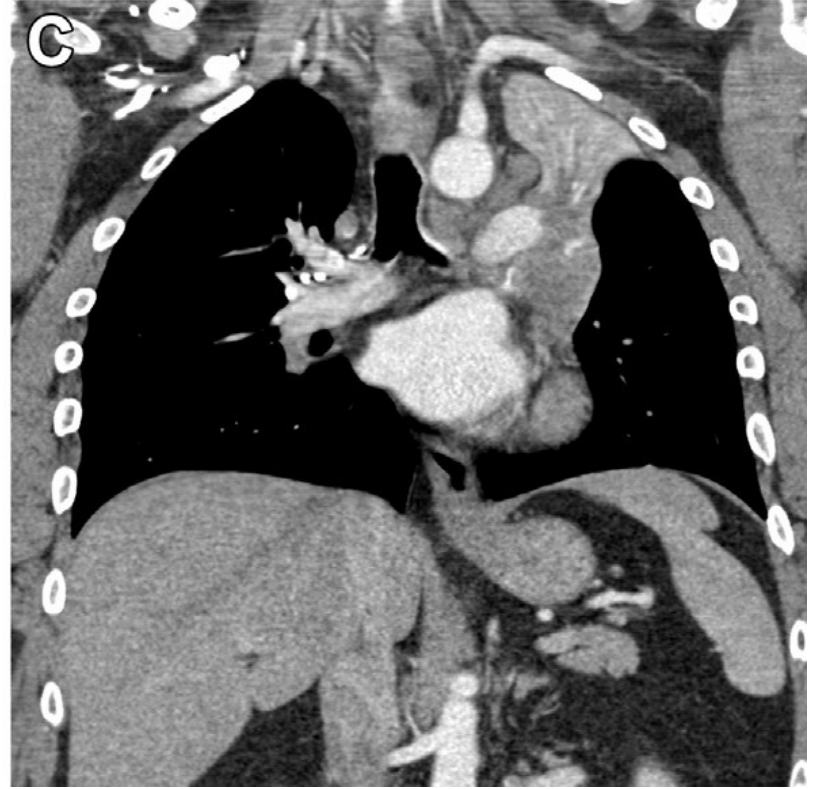
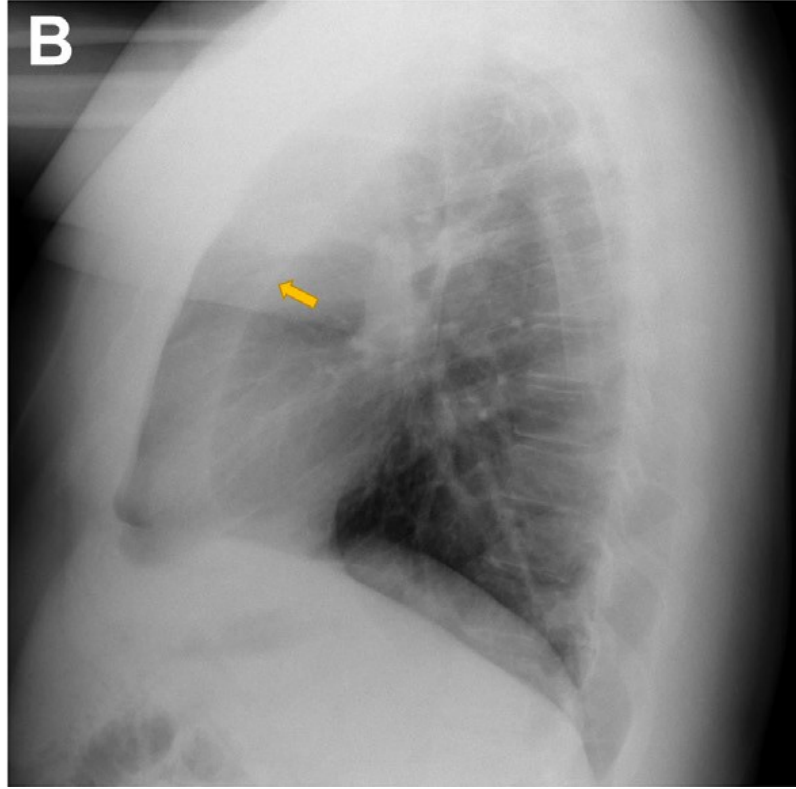
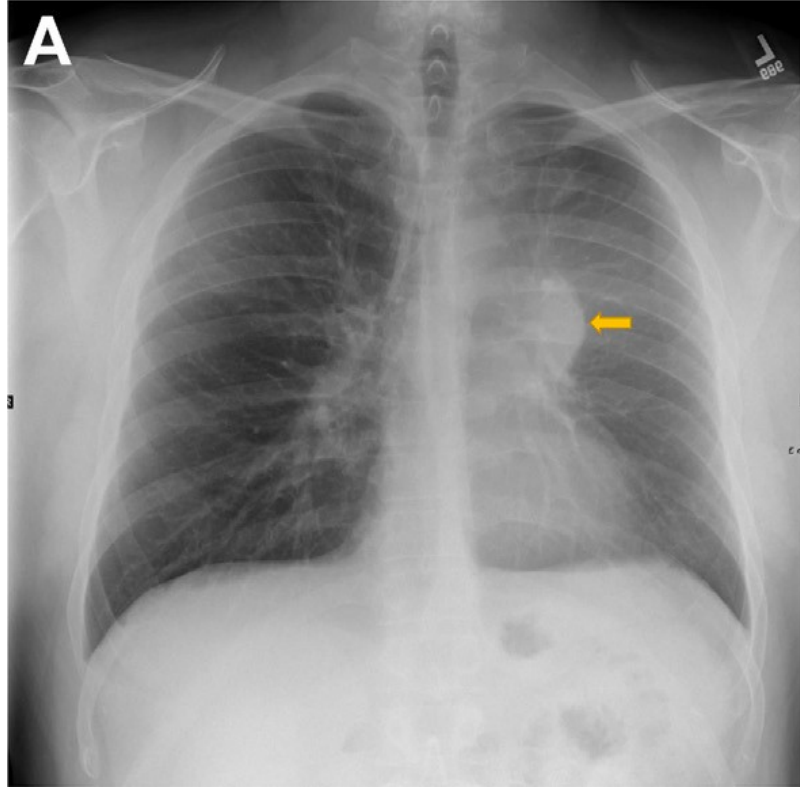


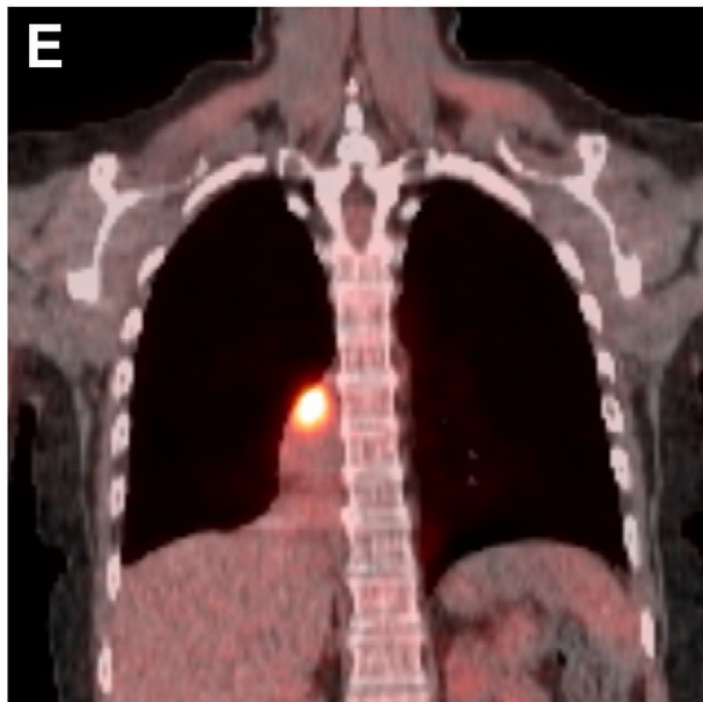
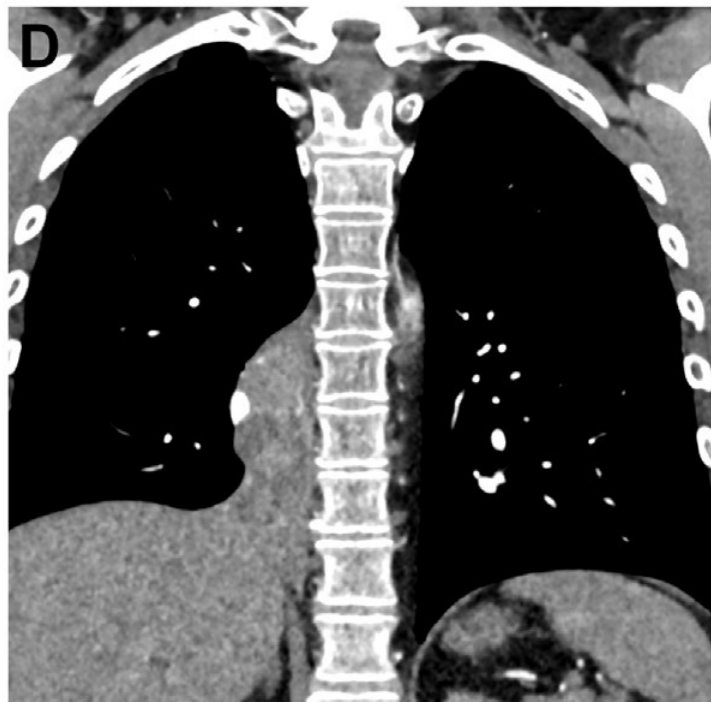
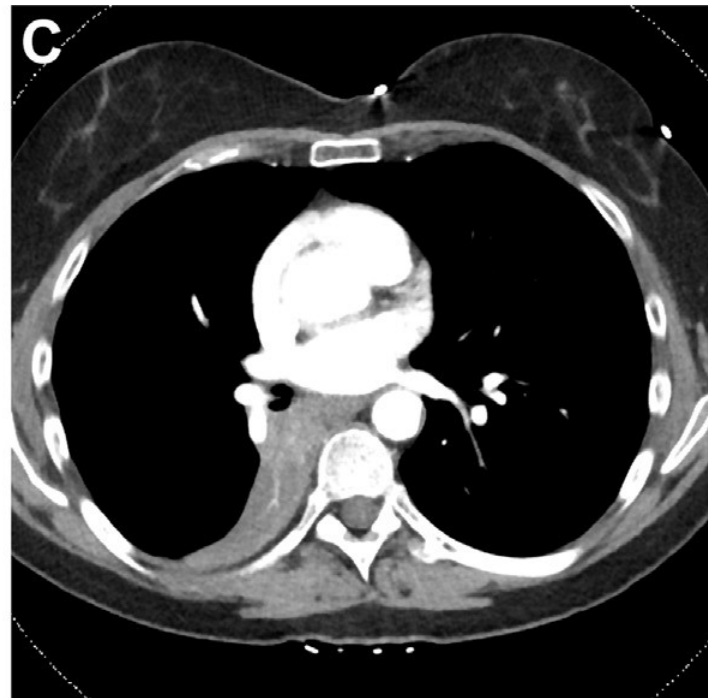
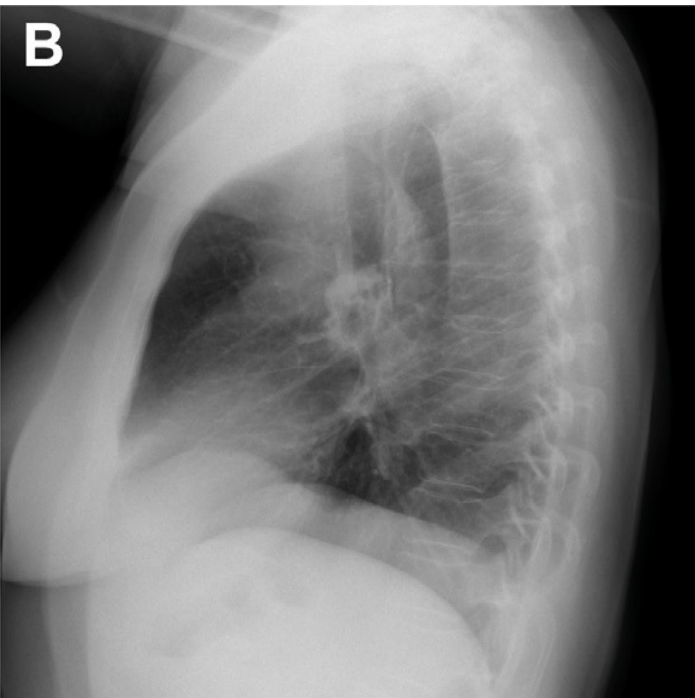
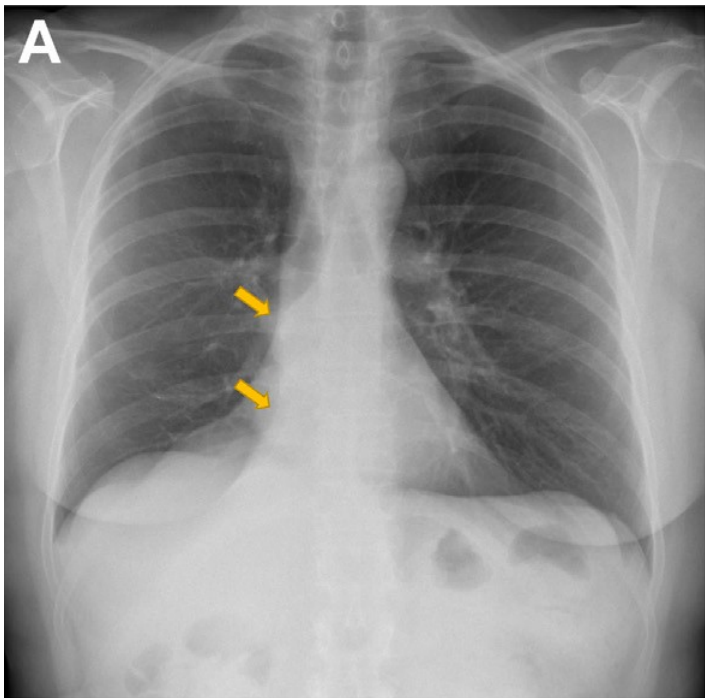


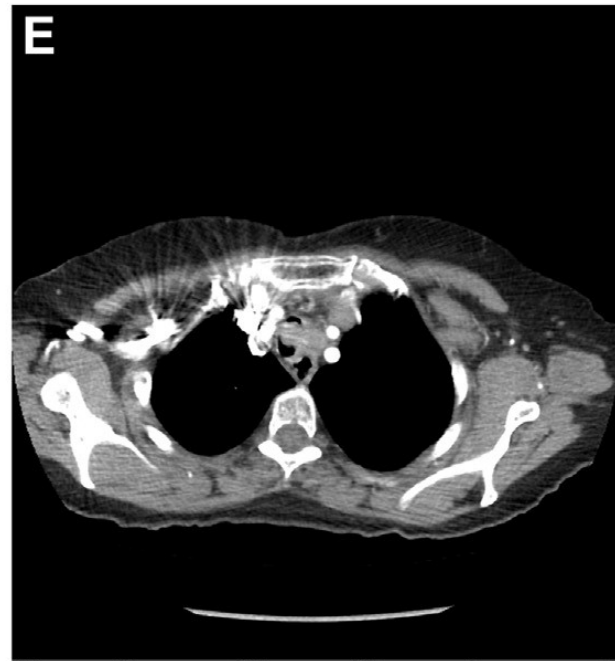
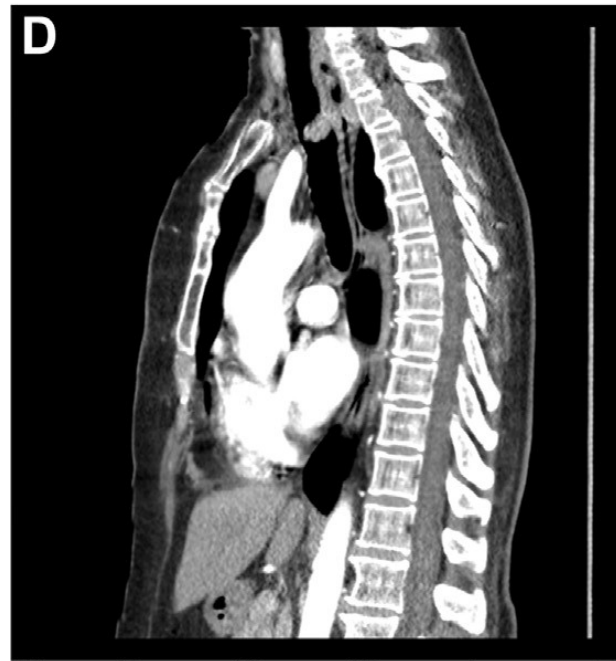
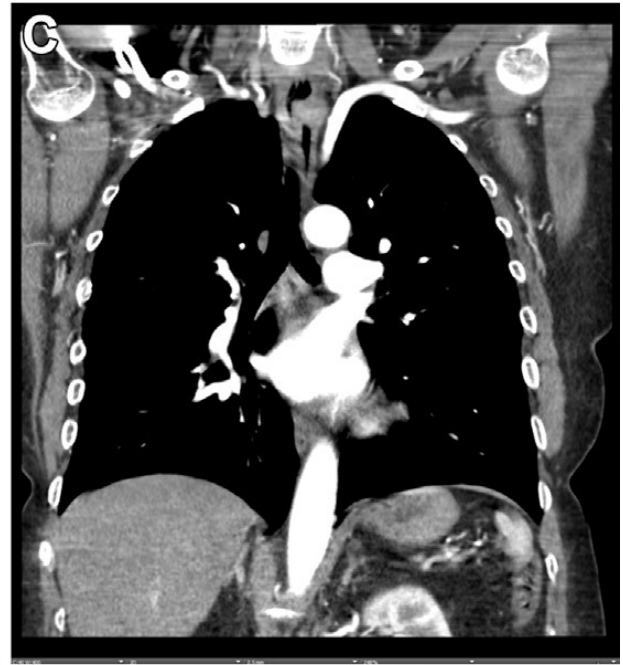
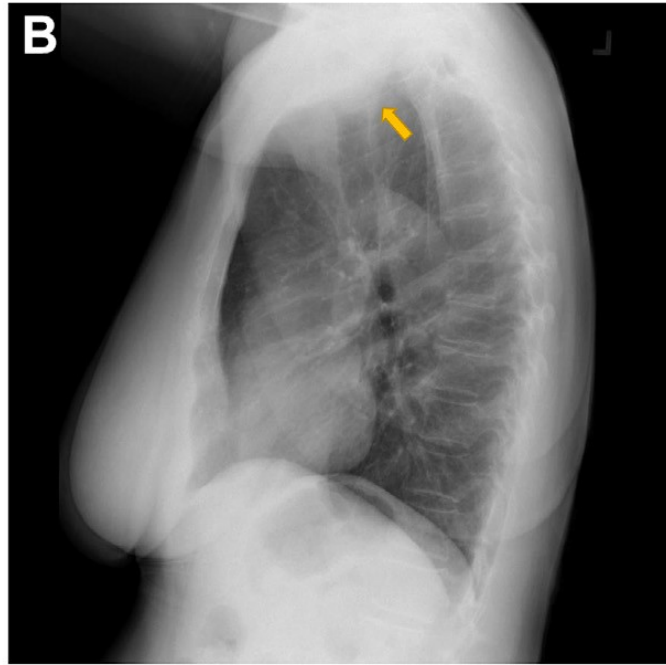
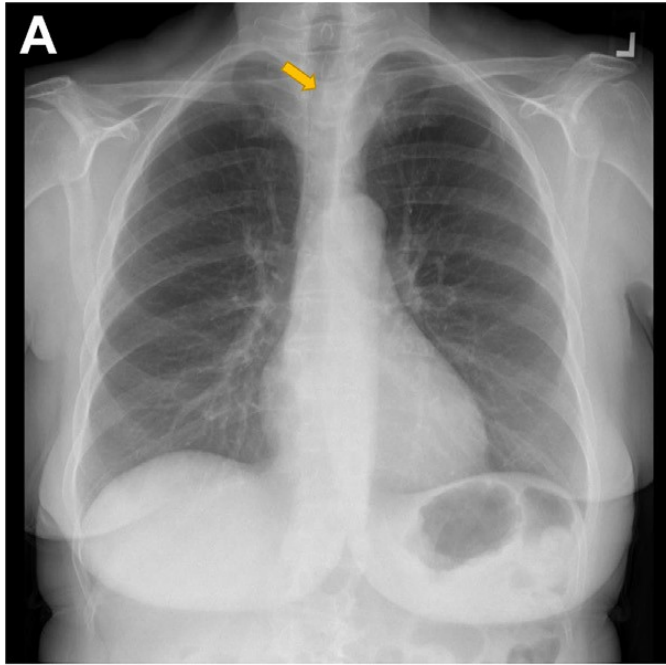




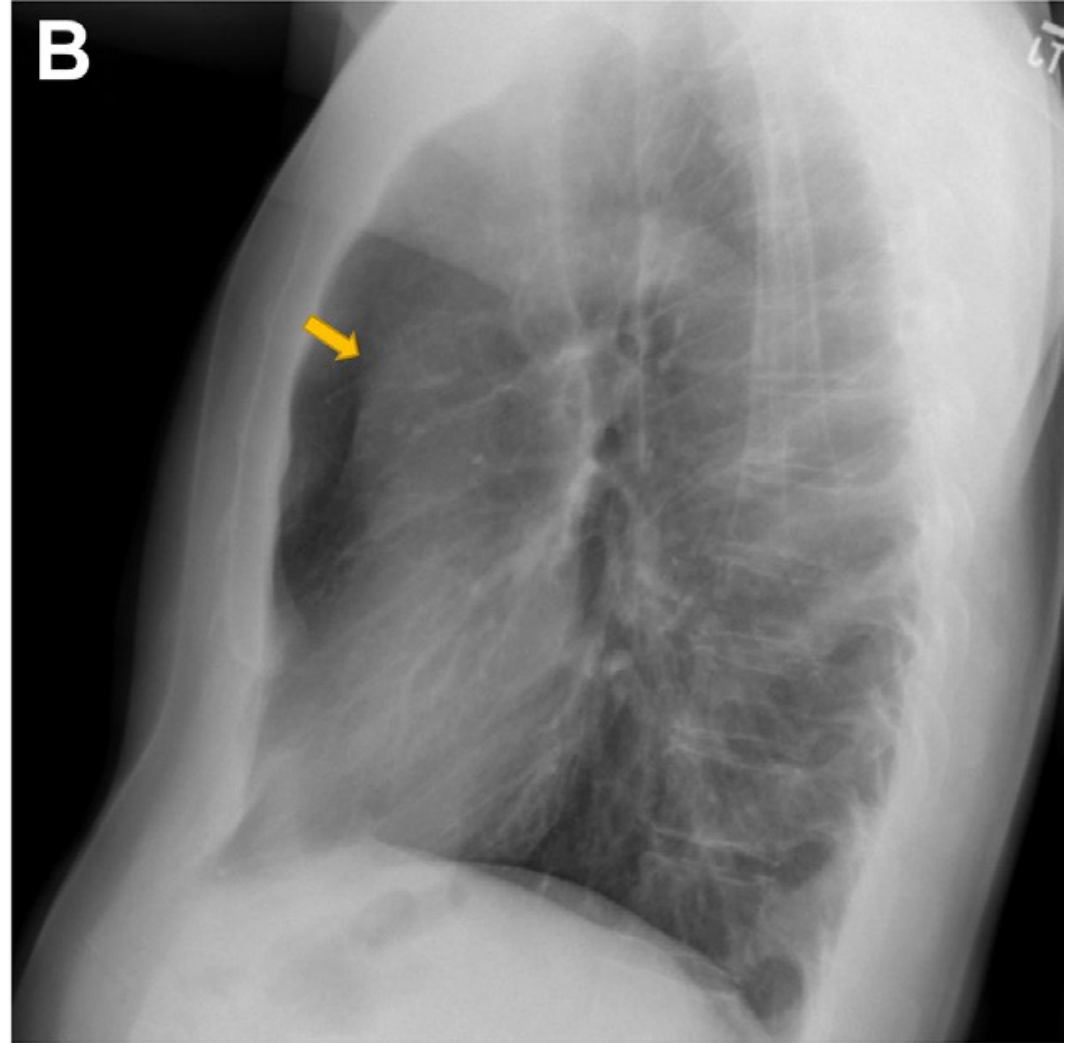
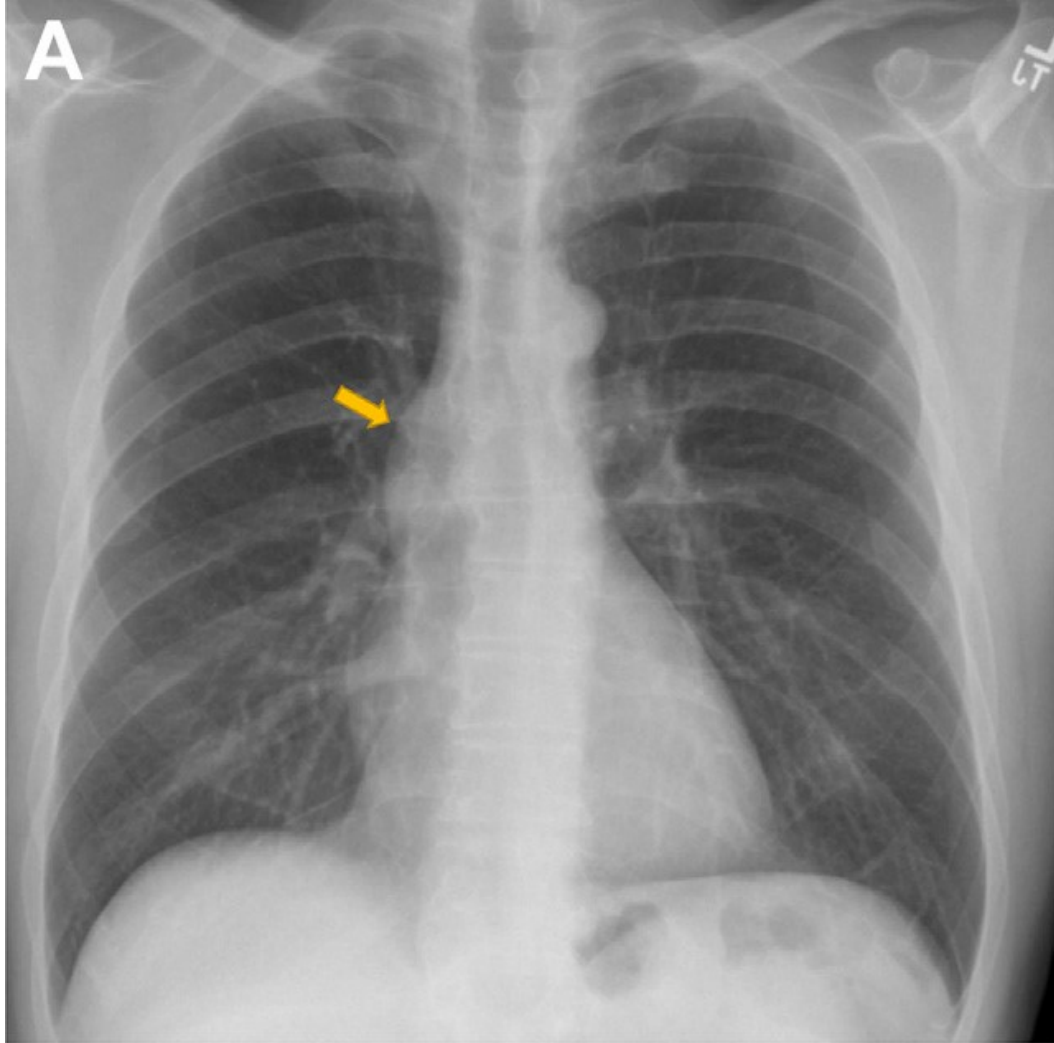


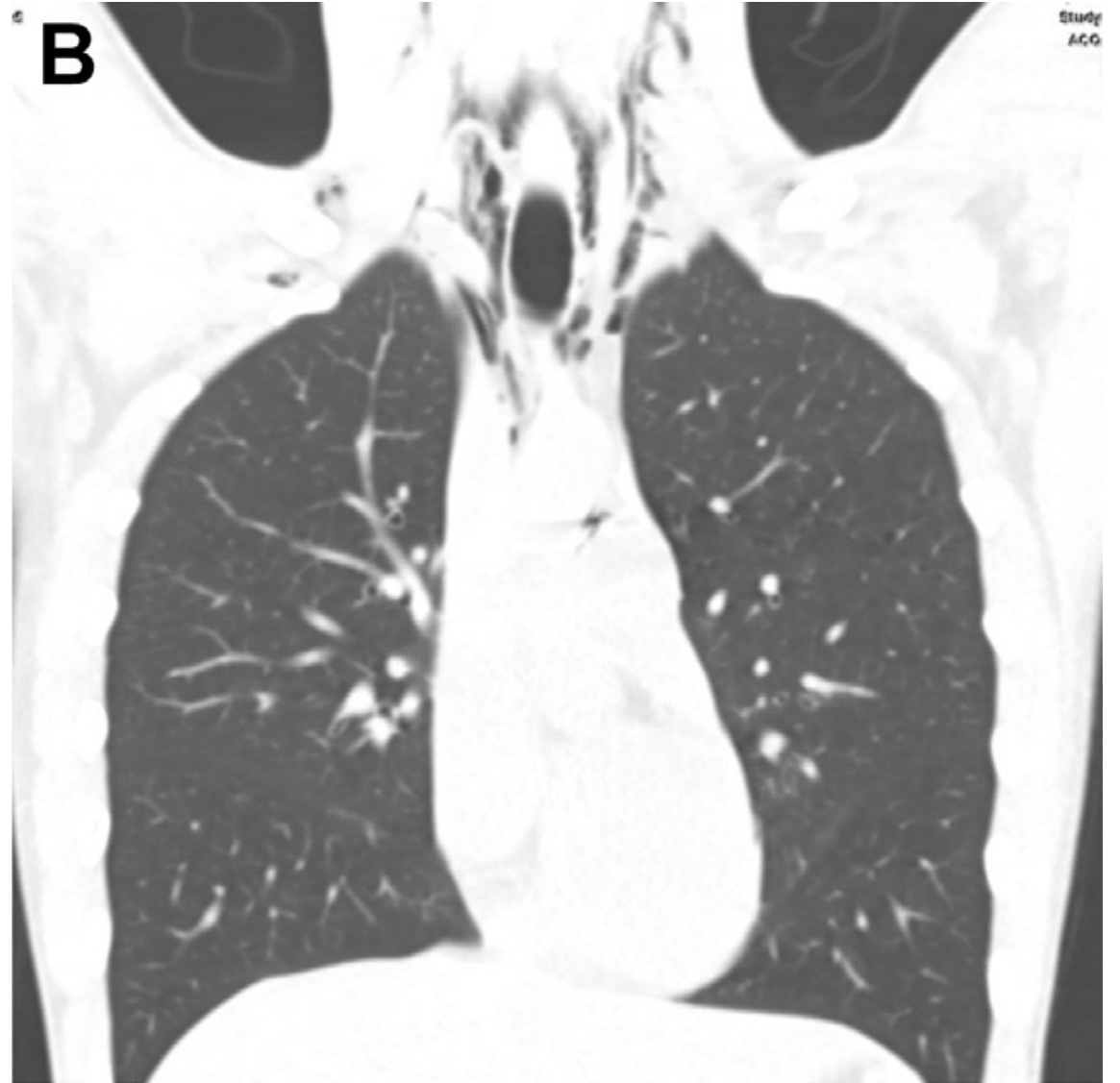
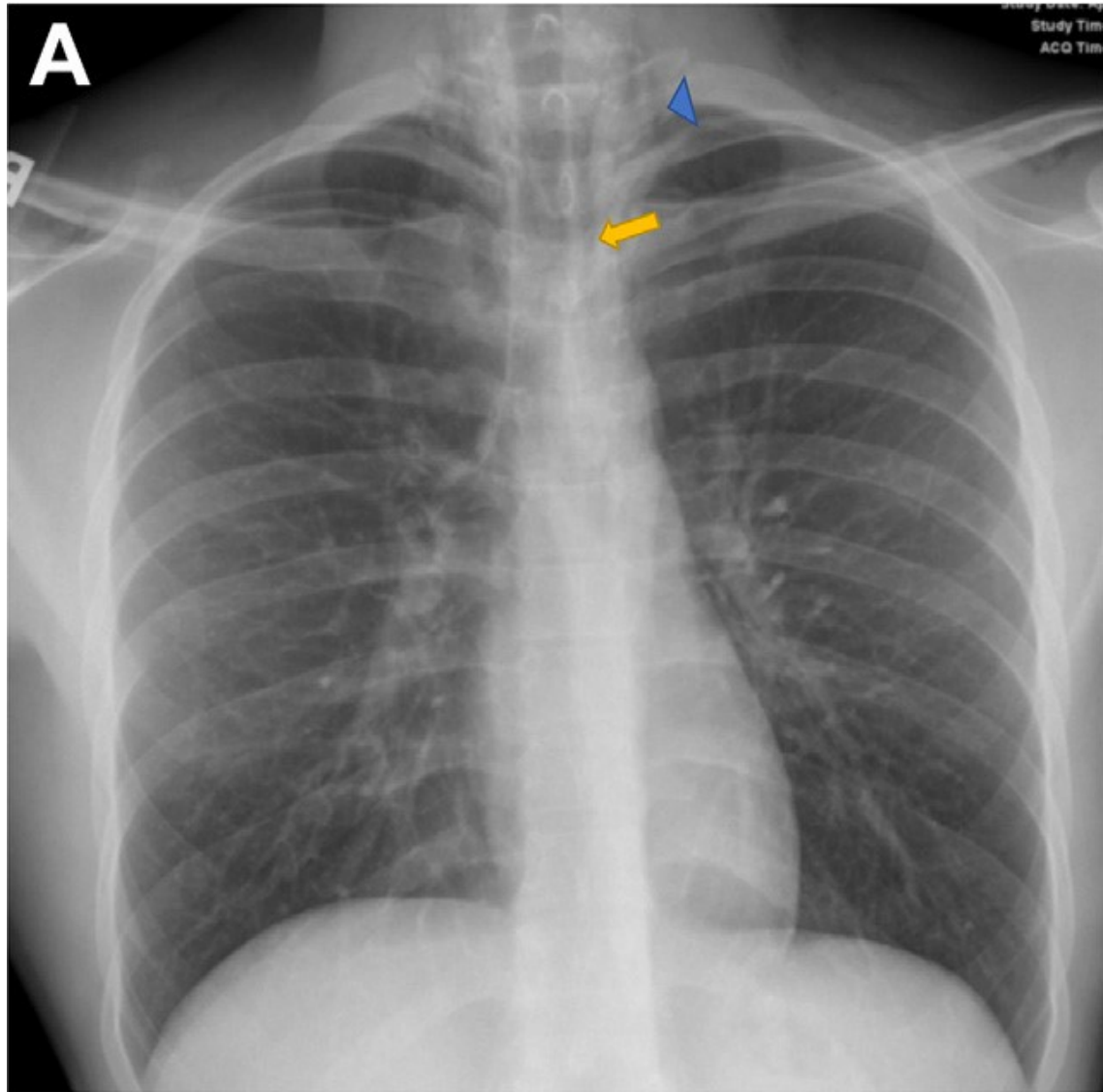


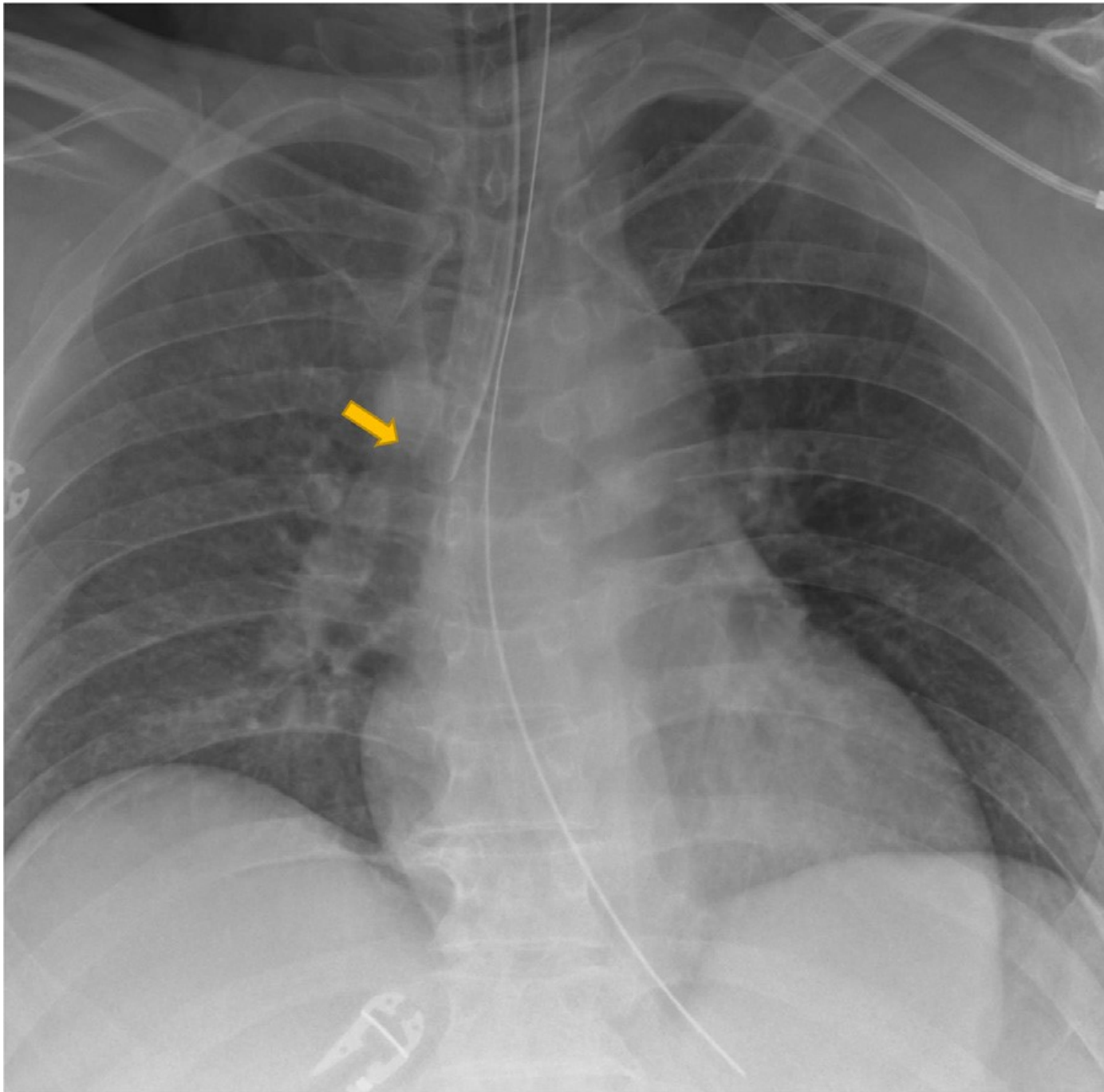


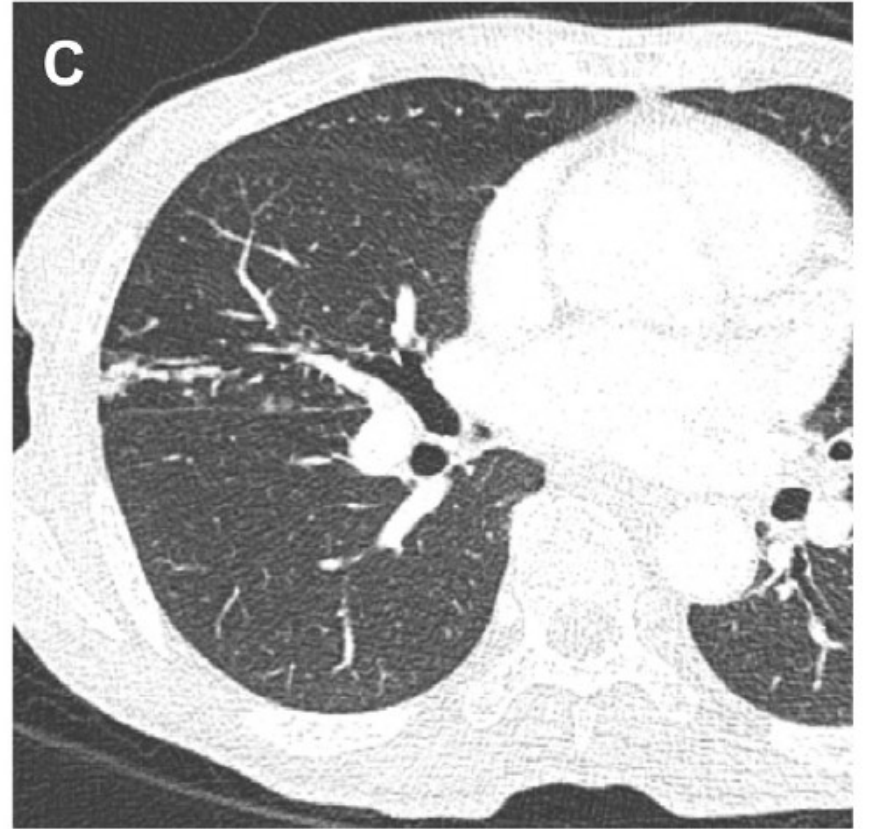
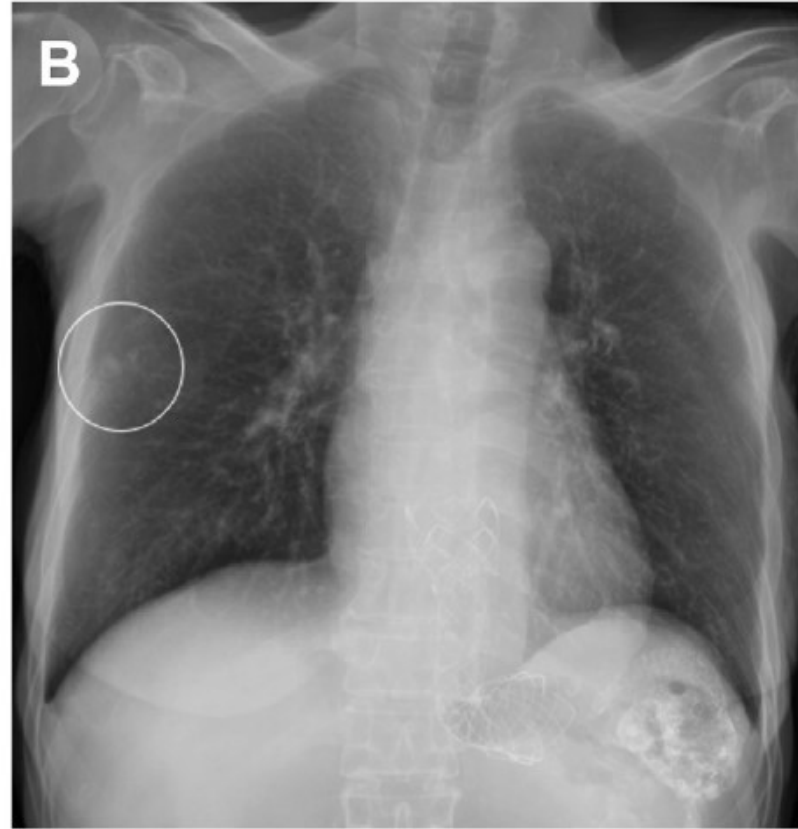
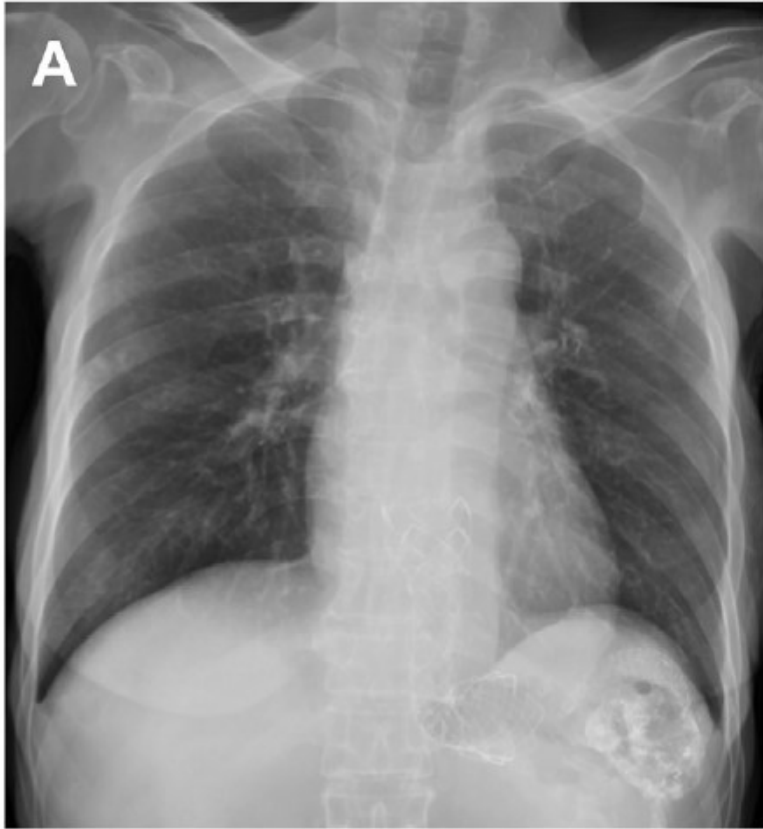


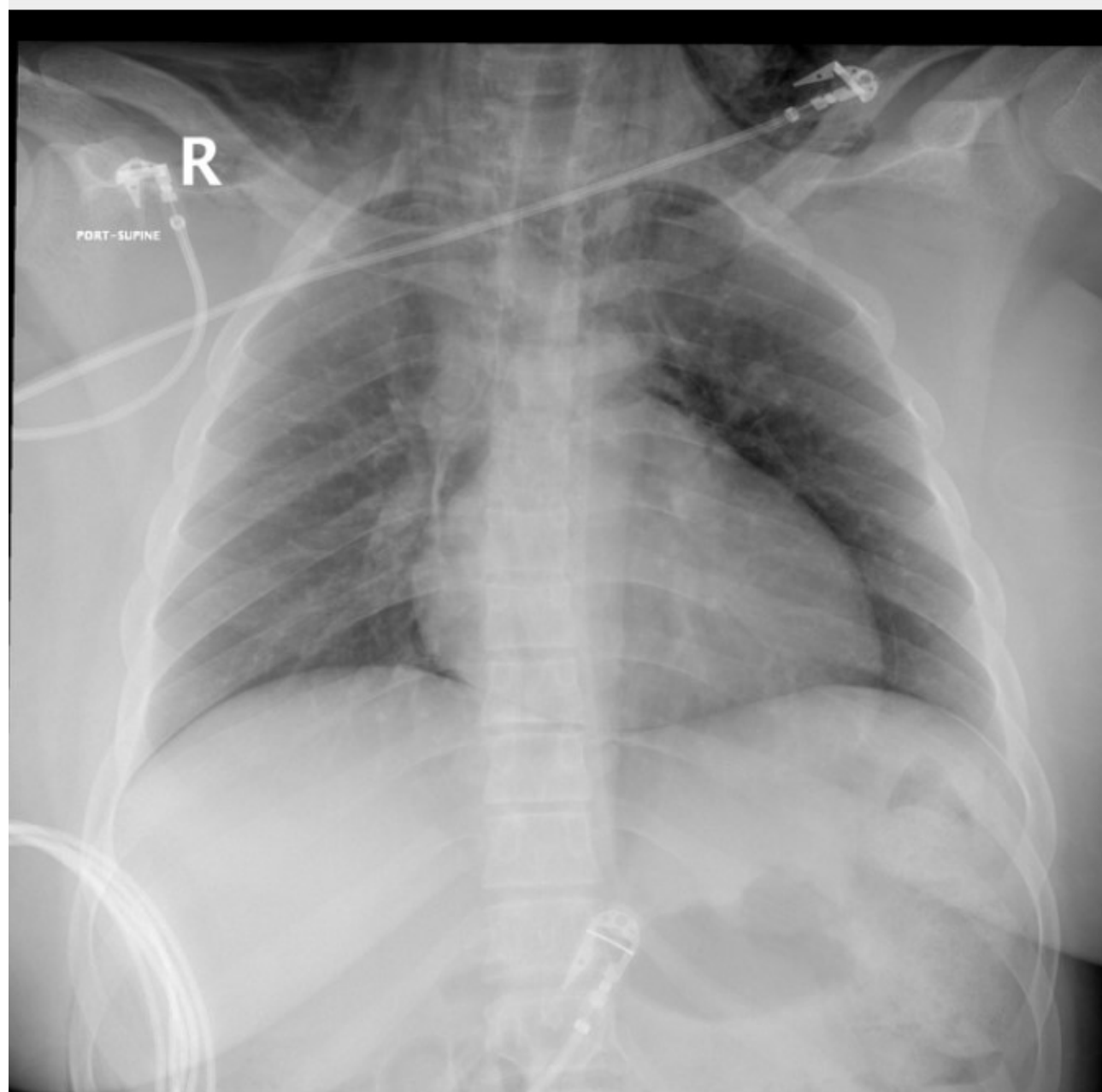


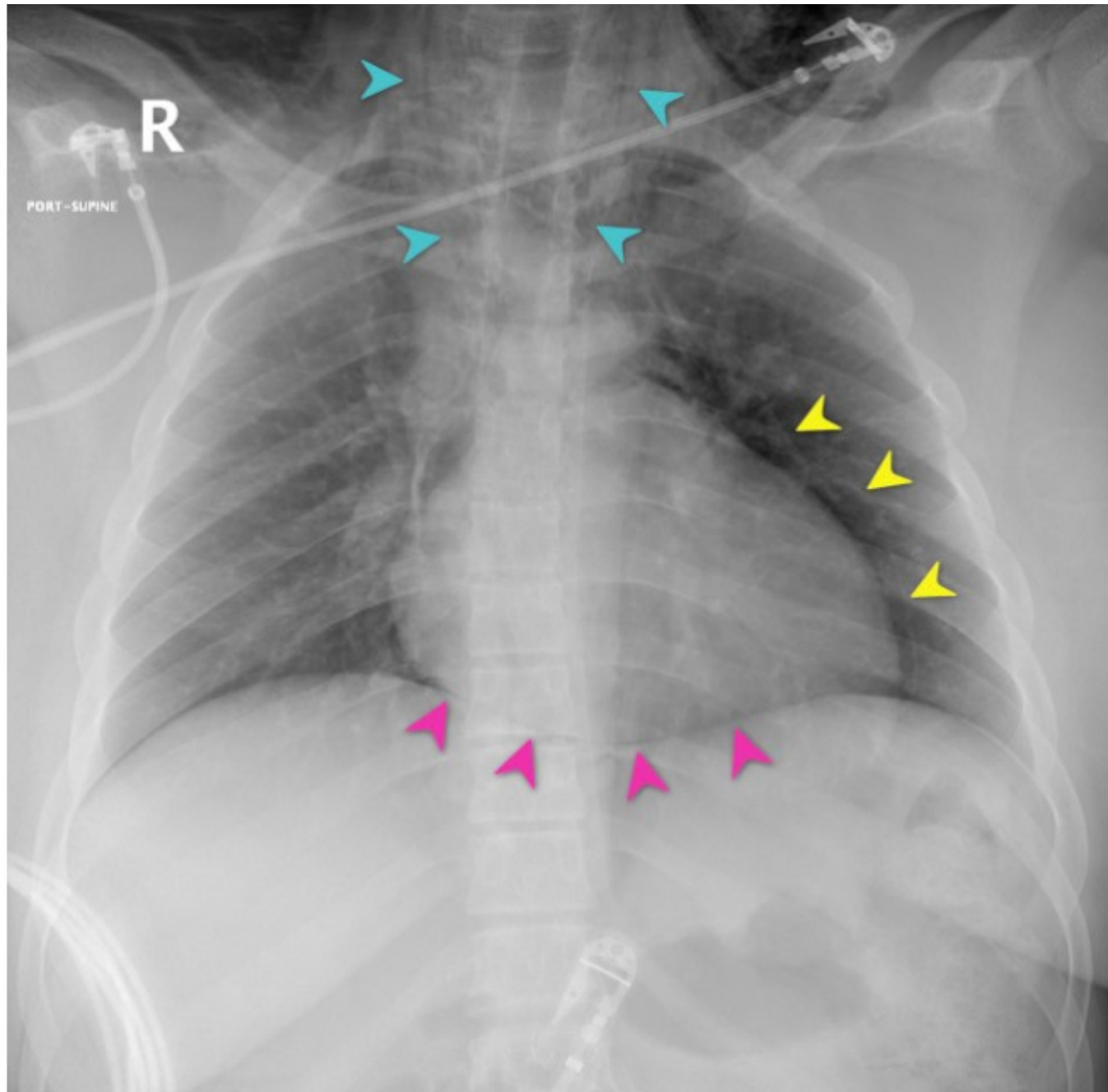




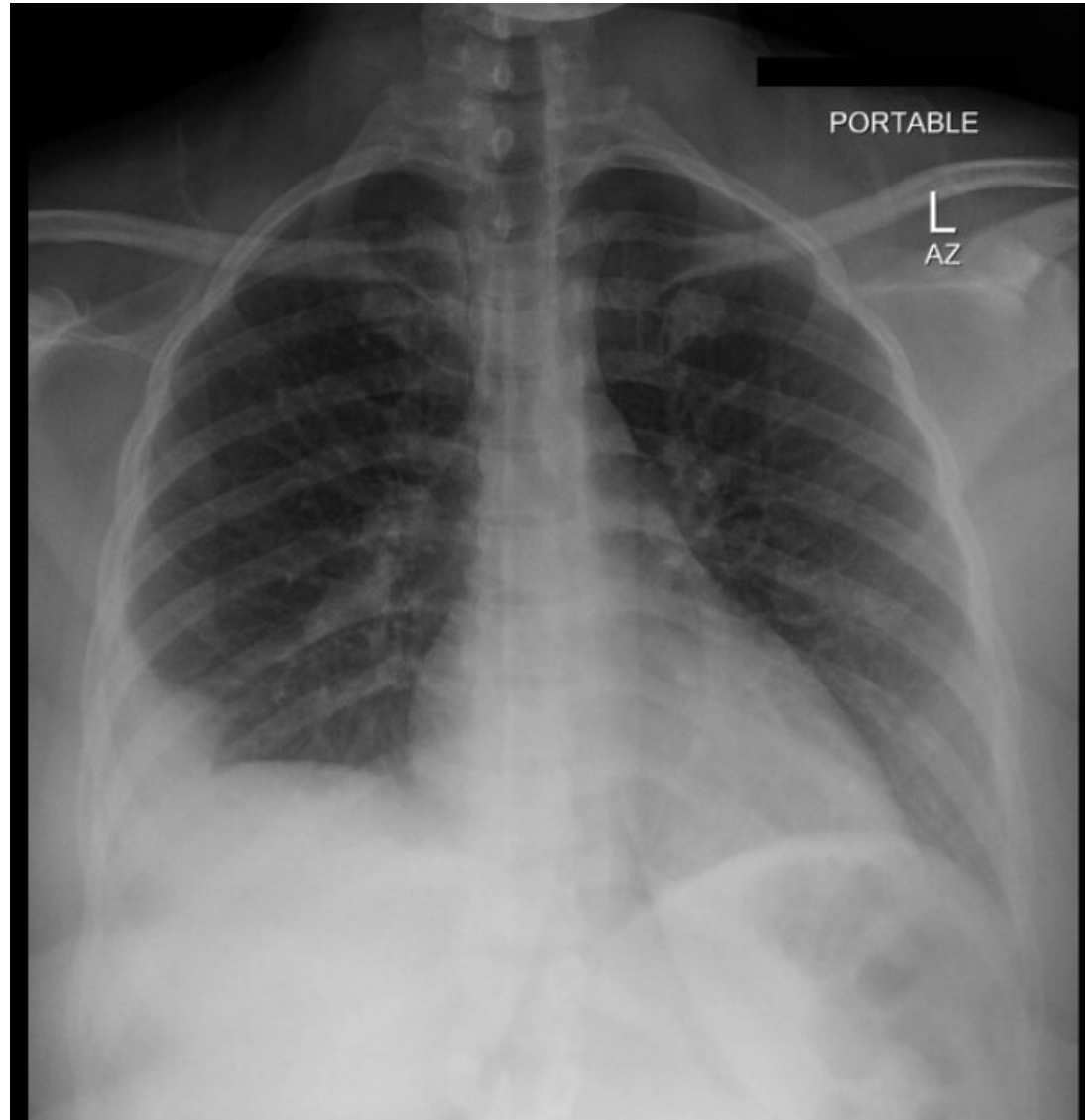








30 Y K Akut dispne, hemoptizi

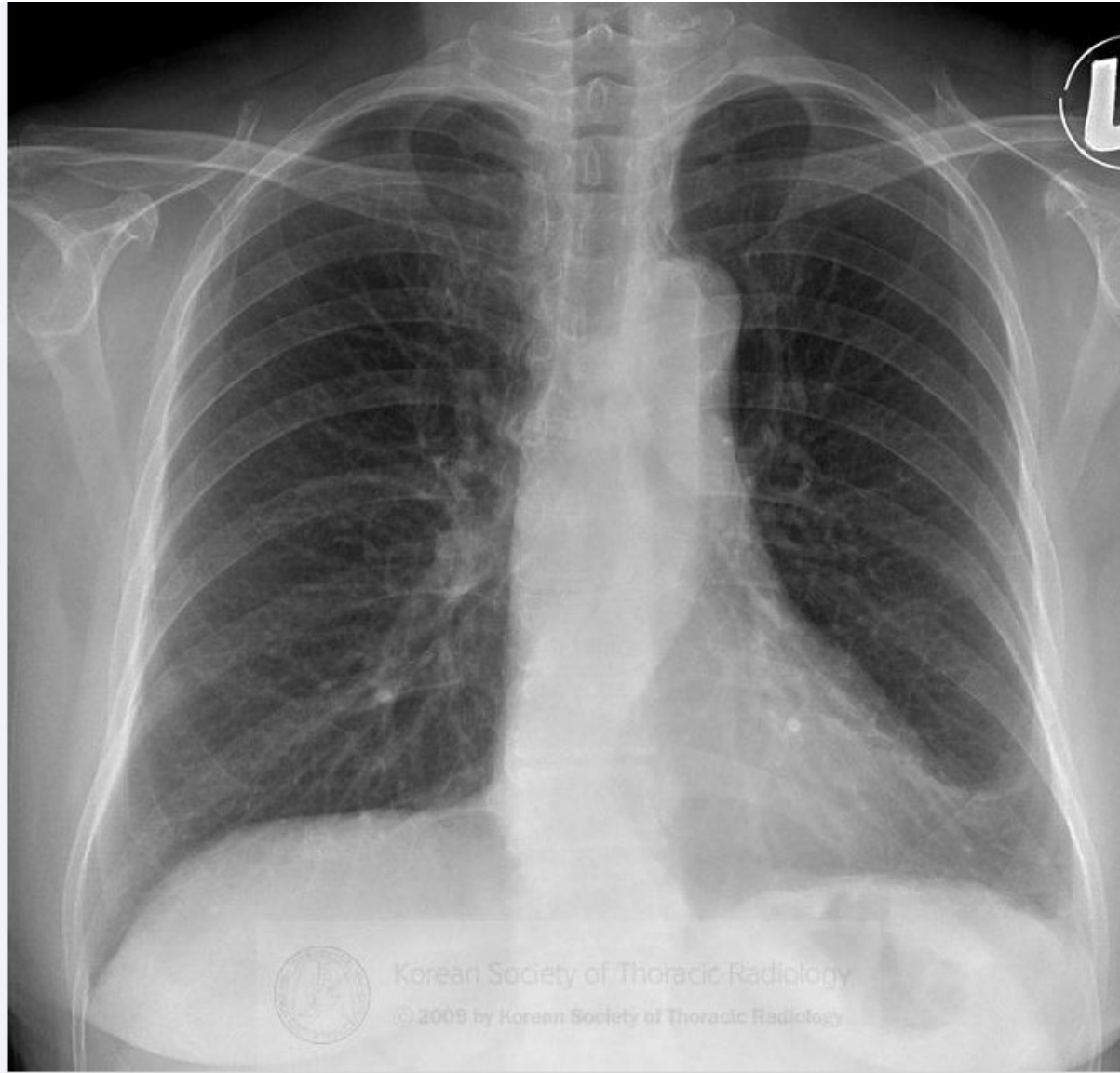


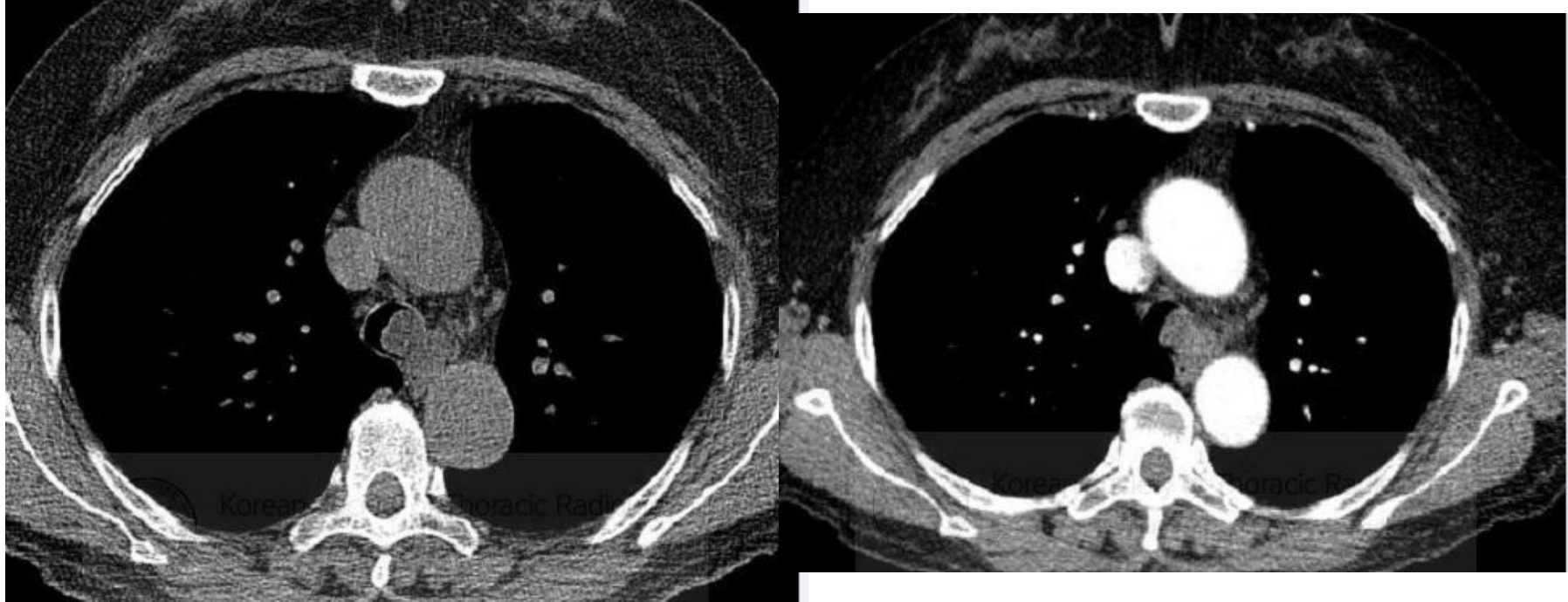
64 yaşında F

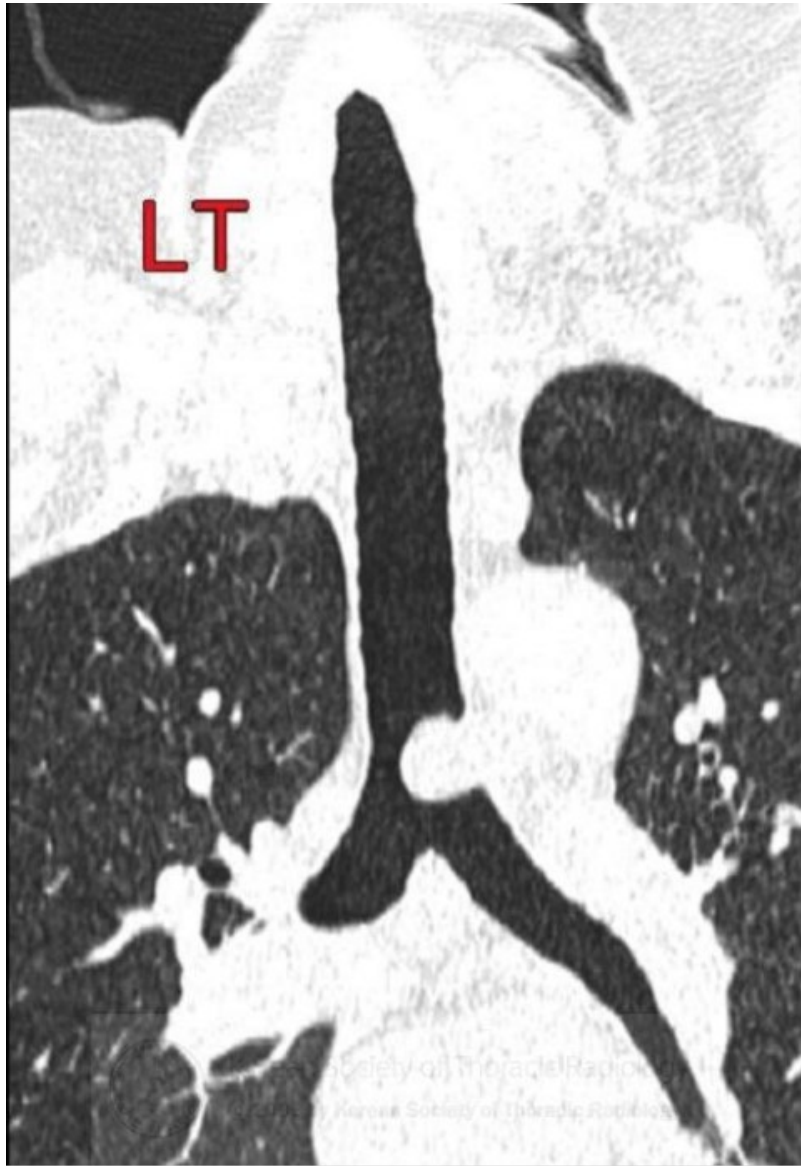

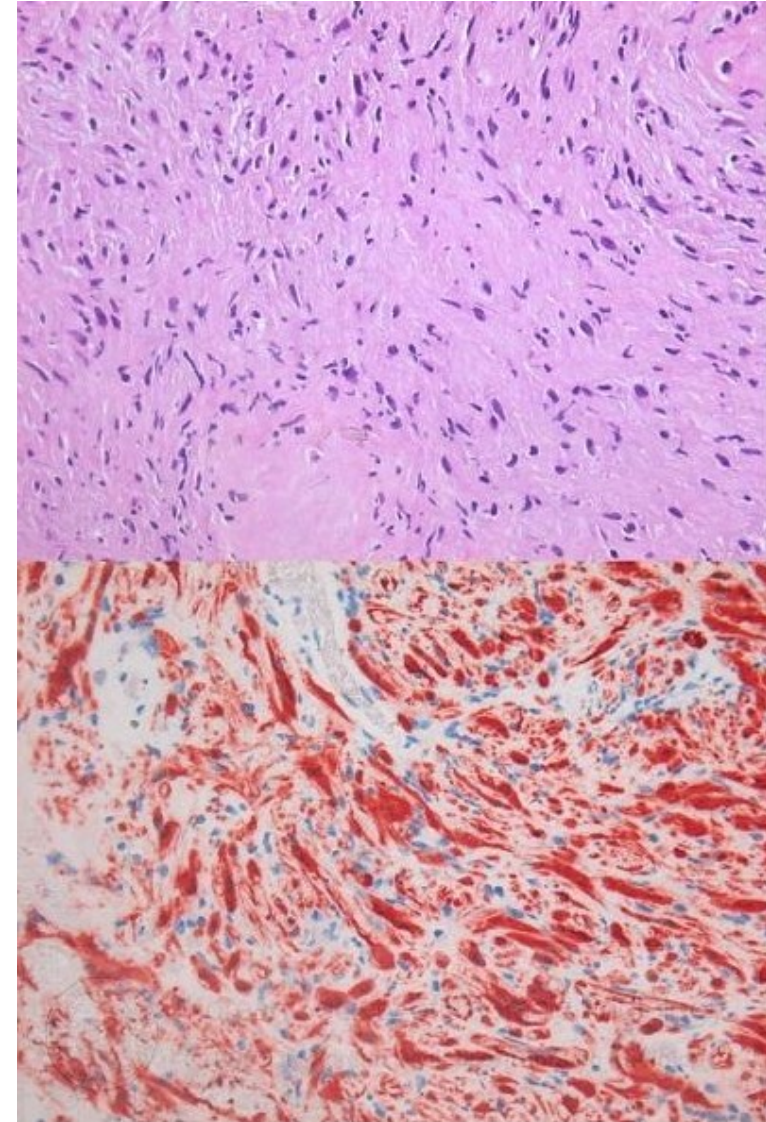
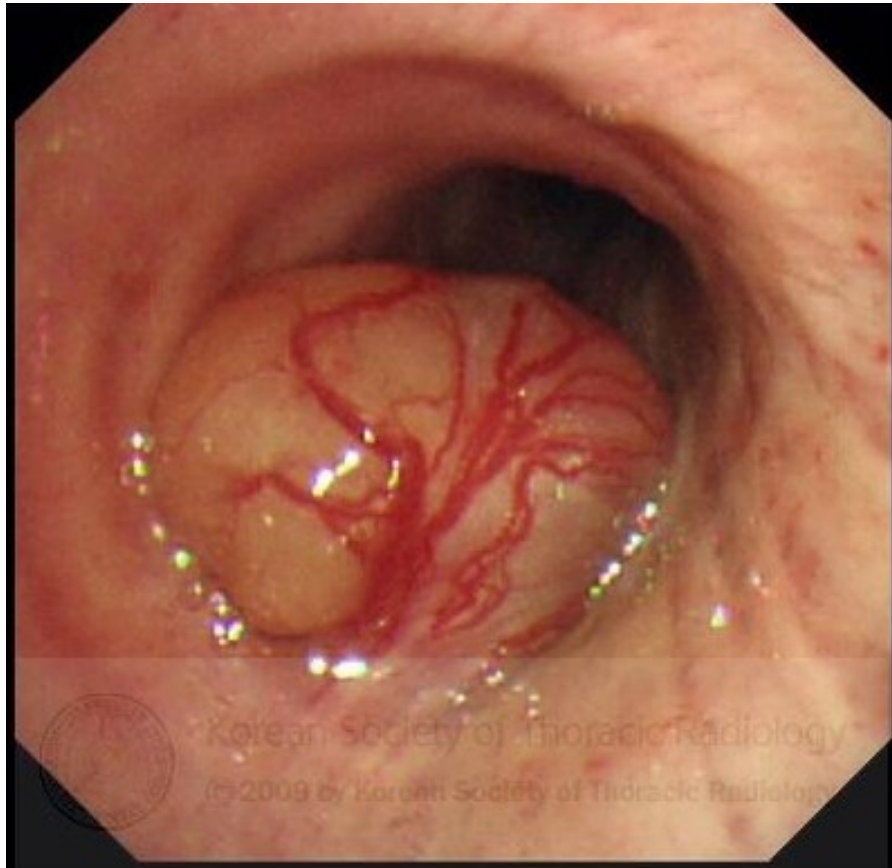
64 yaşında bayan hasta nefes darlığı ve wheezing ile başvurdu. Tanı?

- A. Endotrakeal Hemanjiyoma
- B. Endotrakeal Granüler Hücreli Tümör
- C. Endotrakeal Nörofibroma
- D. Endotrakeal Lipoma
- E. Endotrakeal Hamartom

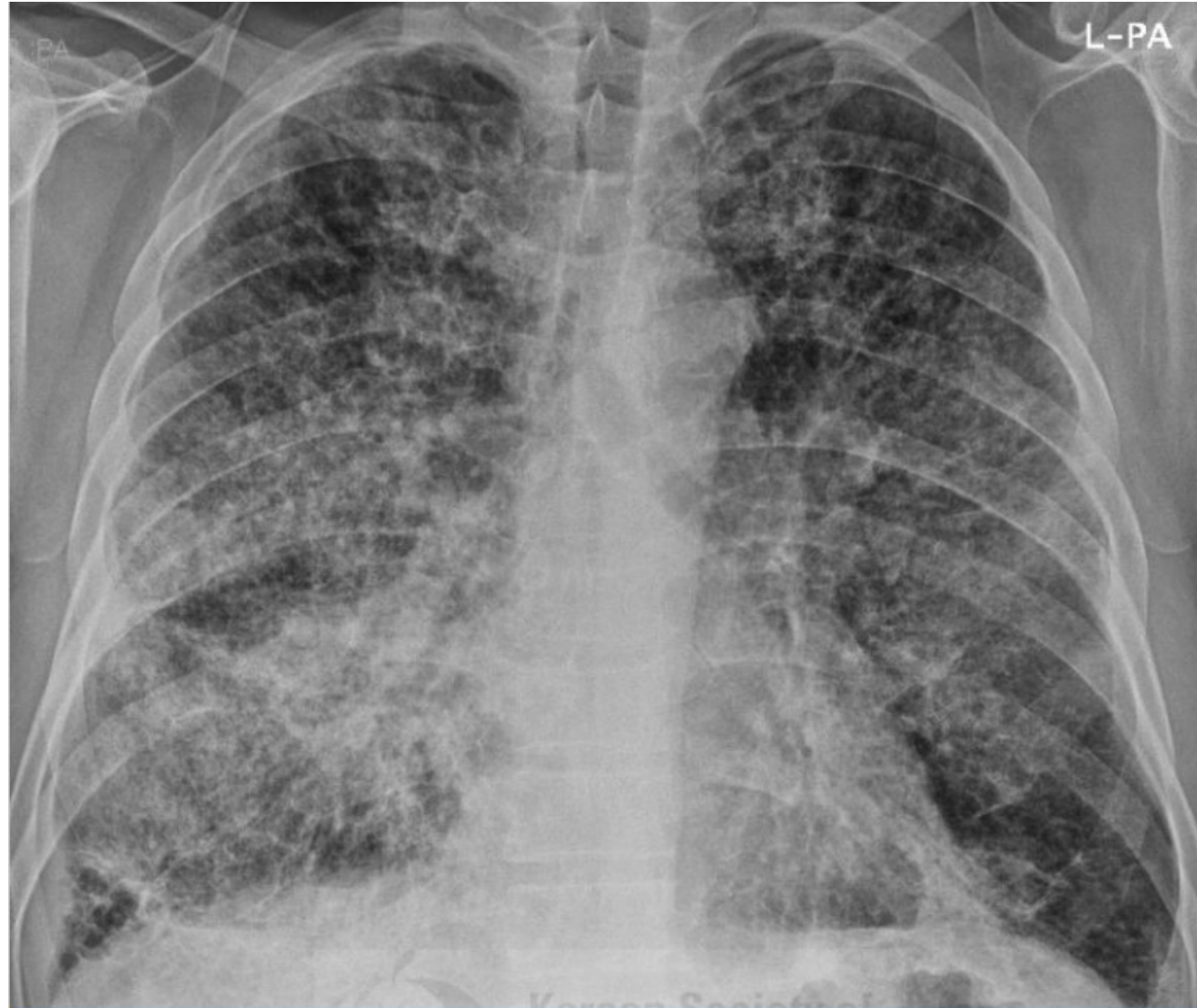

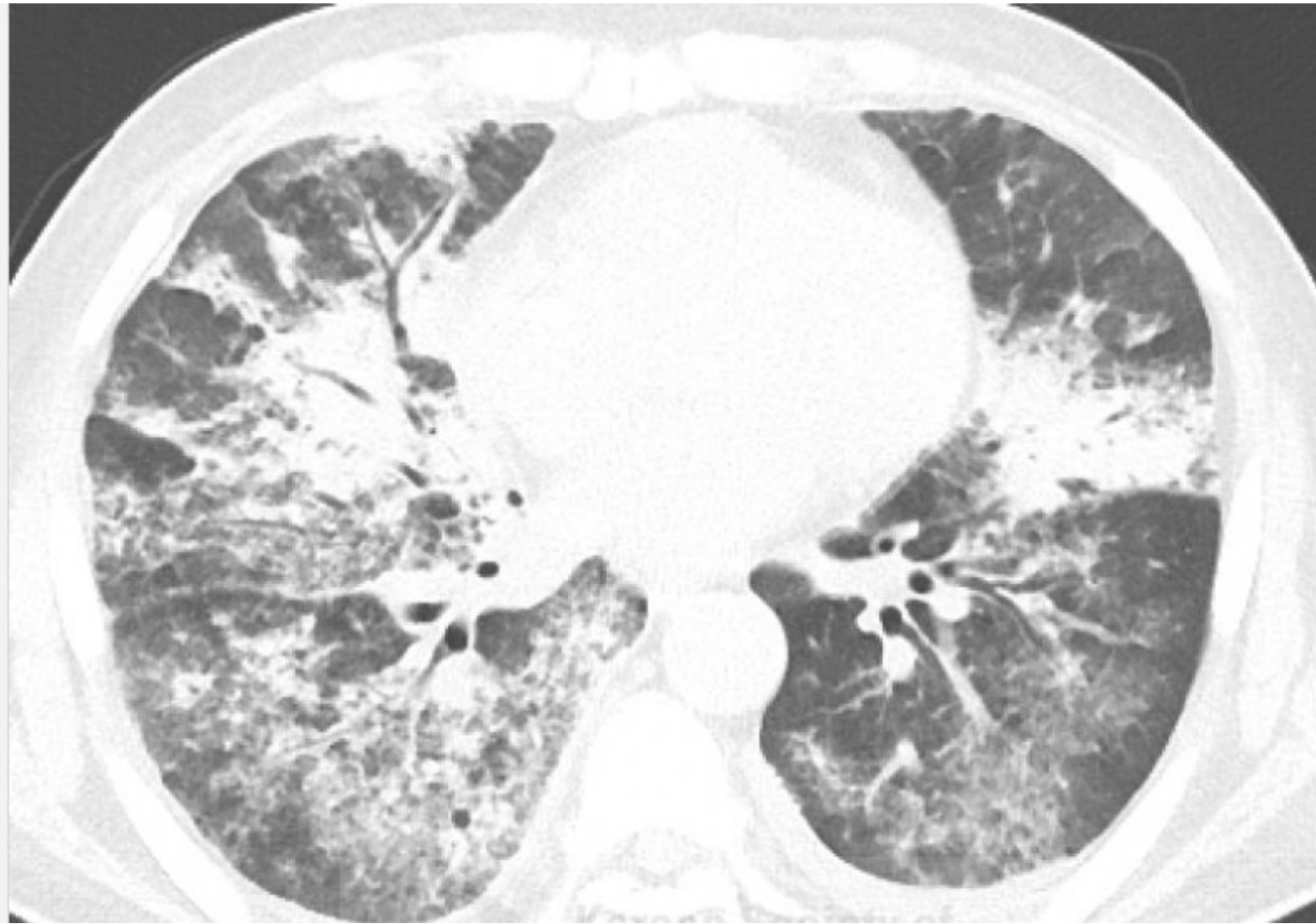



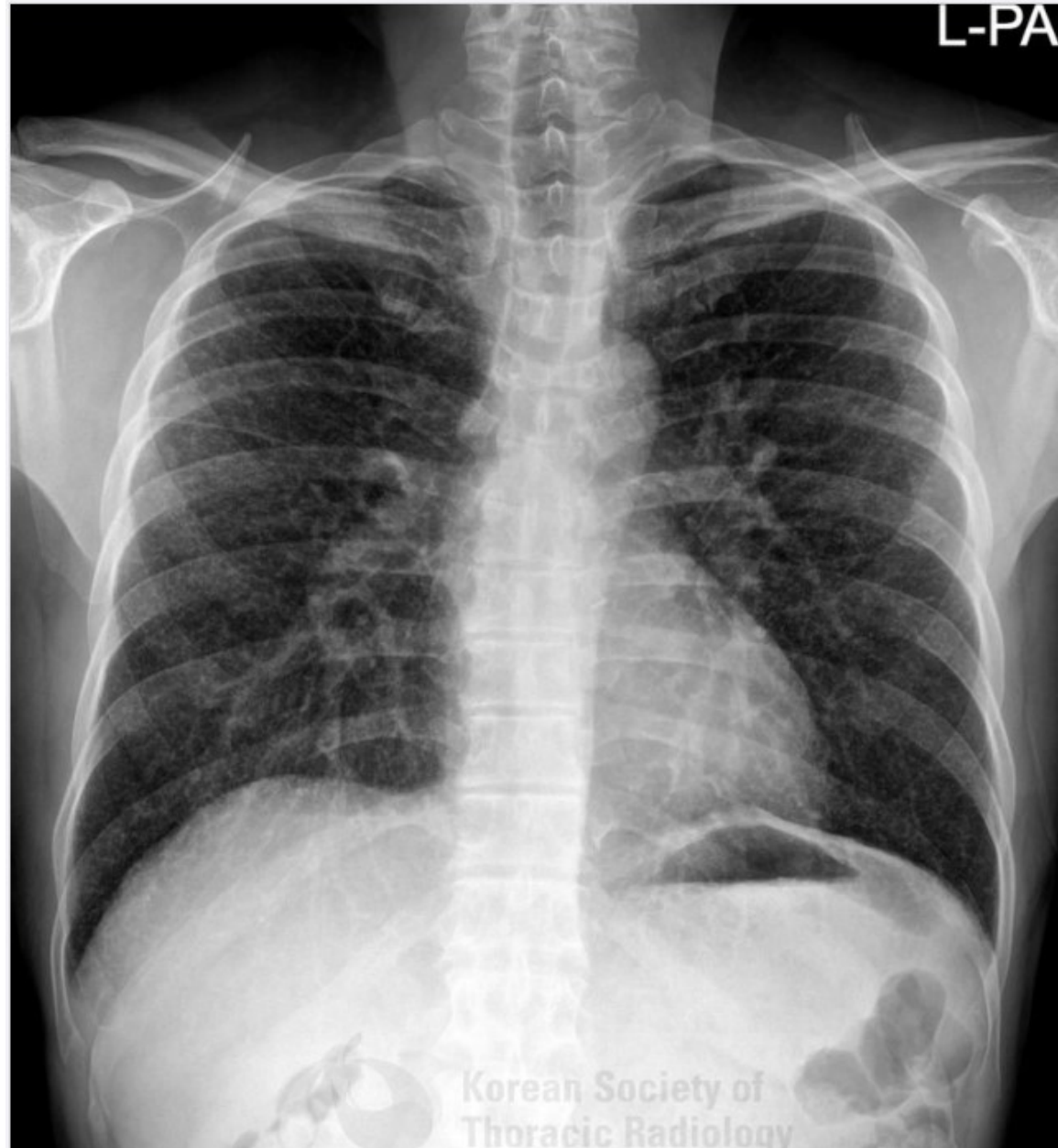


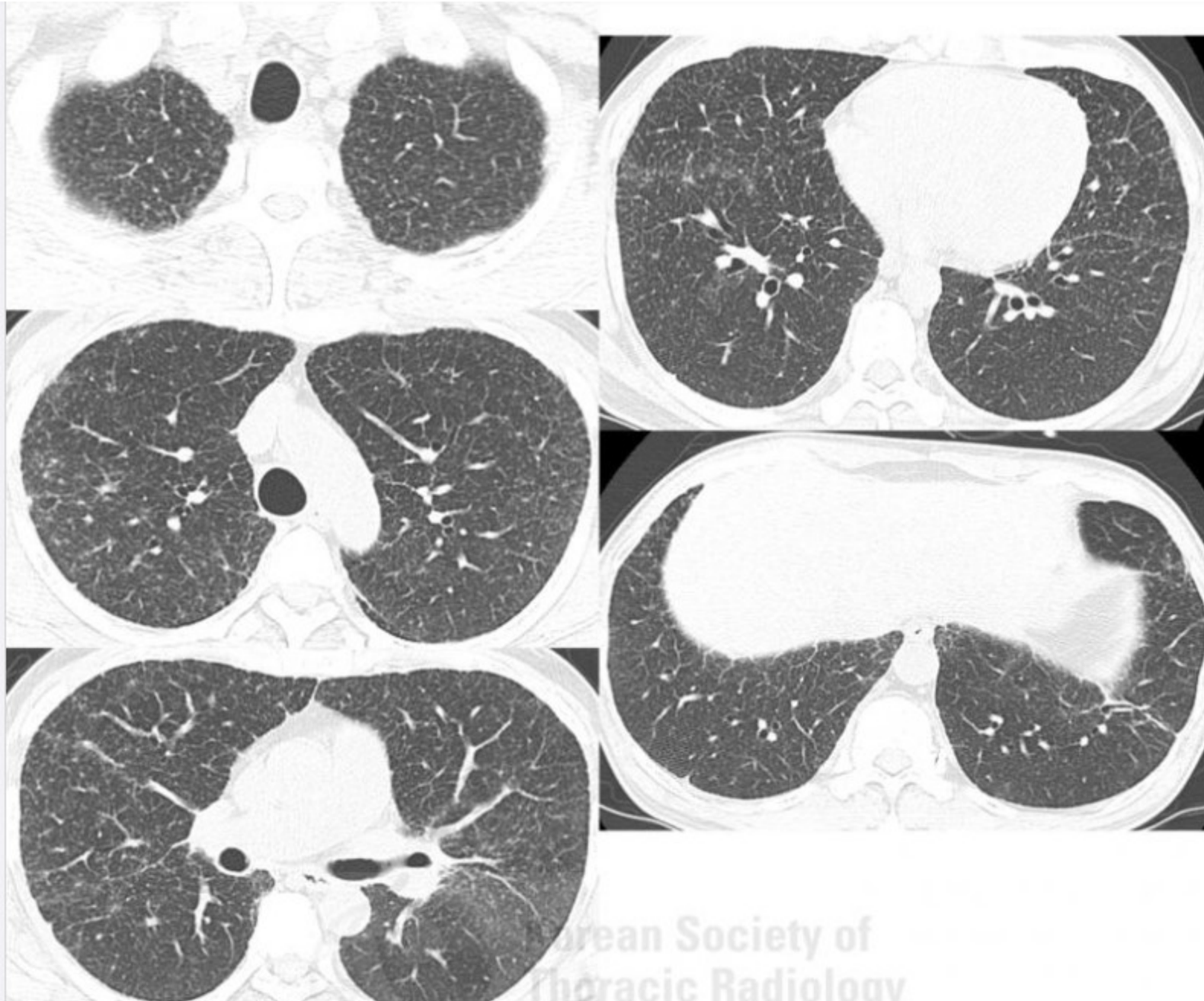
# Hemoptizi











Iranian Society of  
Thoracic Radiology